CABANG
BANTEN

INDONESIAN HEAD & NECK TEAM

BENJOLAN LEHER/KGB/ LYMPHADENOPATI

dr. Ibnu Harris Fadillah, Sp.THTBKL,Subsp.Onk (K)

Departemen THT - BKL
Fakultas Kedokteran Universitas Trisakti

DIAGNOSIS BENJOLAN LEHER???

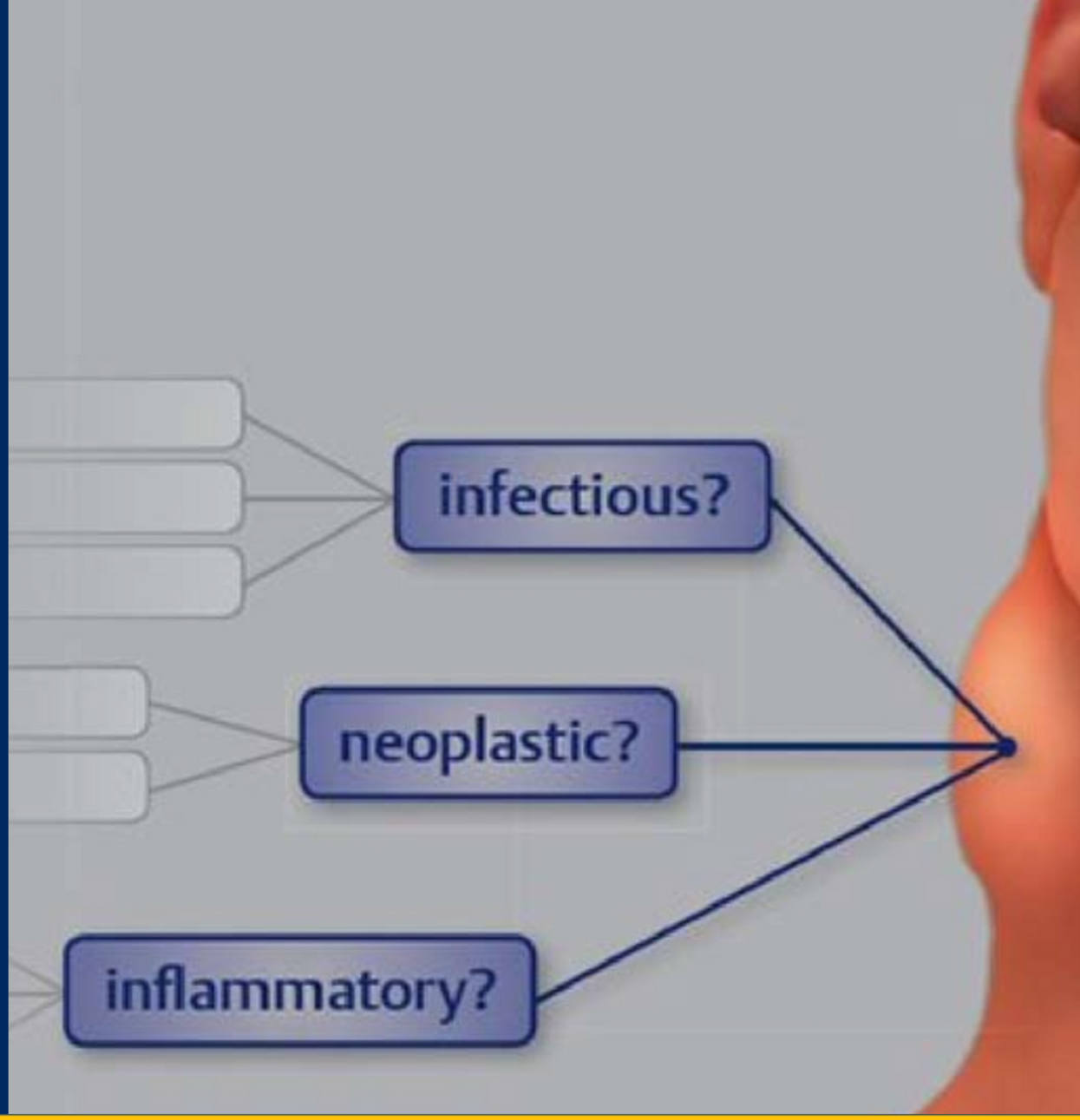

READ MORE

Departemen THT - BKL
Fakultas Kedokteran Universitas Trisakti

dr. Ibnu Harris Fadillah, Sp.THTBKL,Subsp.Onk (K)

Organ yang mungkin berkaitan dengan benjolan kepala leher

- **Parotis**
- **Submandibula gland**
- **Sublingual gland**
- **Thyroid**
- **Duktus Thyroglosus**
- **Kelenjar Limfe/KGB**



Anatomi penting yang berkaitan

- **Parotis, Submandibula gland, Sublingual gland**
- Merupakan Major salivary gland
- Sekresi saliva merupakan reflex parasimpatik yang dimediasi oleh N.Fasialis & N.Glosofaringeus
- Stimulasi simpatik pada saat stress menyebabkan mulut kering

READ MORE

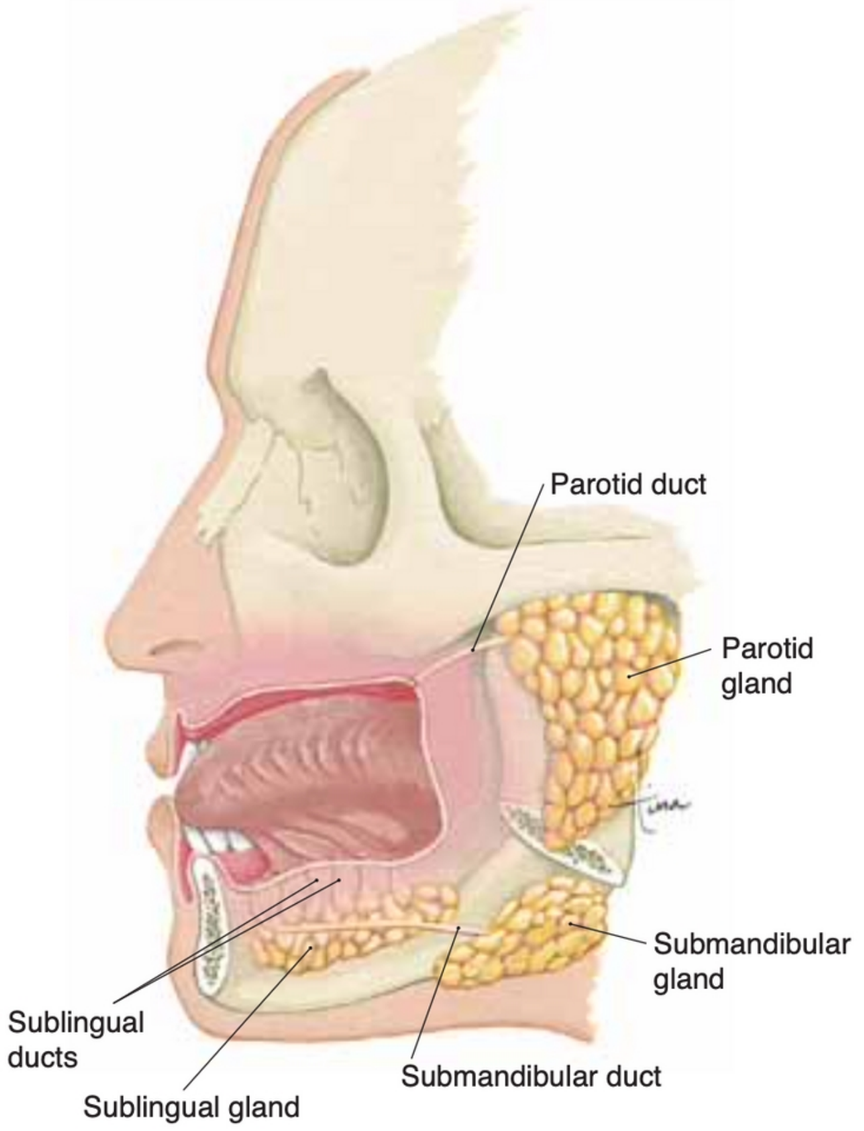

Figure 16–3. The salivary glands shown in left lateral view.

Massa parotis

- **Adenoma pleomorfik merupakan neoplasma jinak yang paling pada parotis**
- **Adanya massa parotis yang disertai paresis N7 merupakan tanda kemungkinan suatu keganasan**
- **Ektirpasi massa hanya di perbolehkan pada massa neoplasma jinak/ganas dan bukan suatu infeksi KGB**

The Thyroid Gland

READ MORE

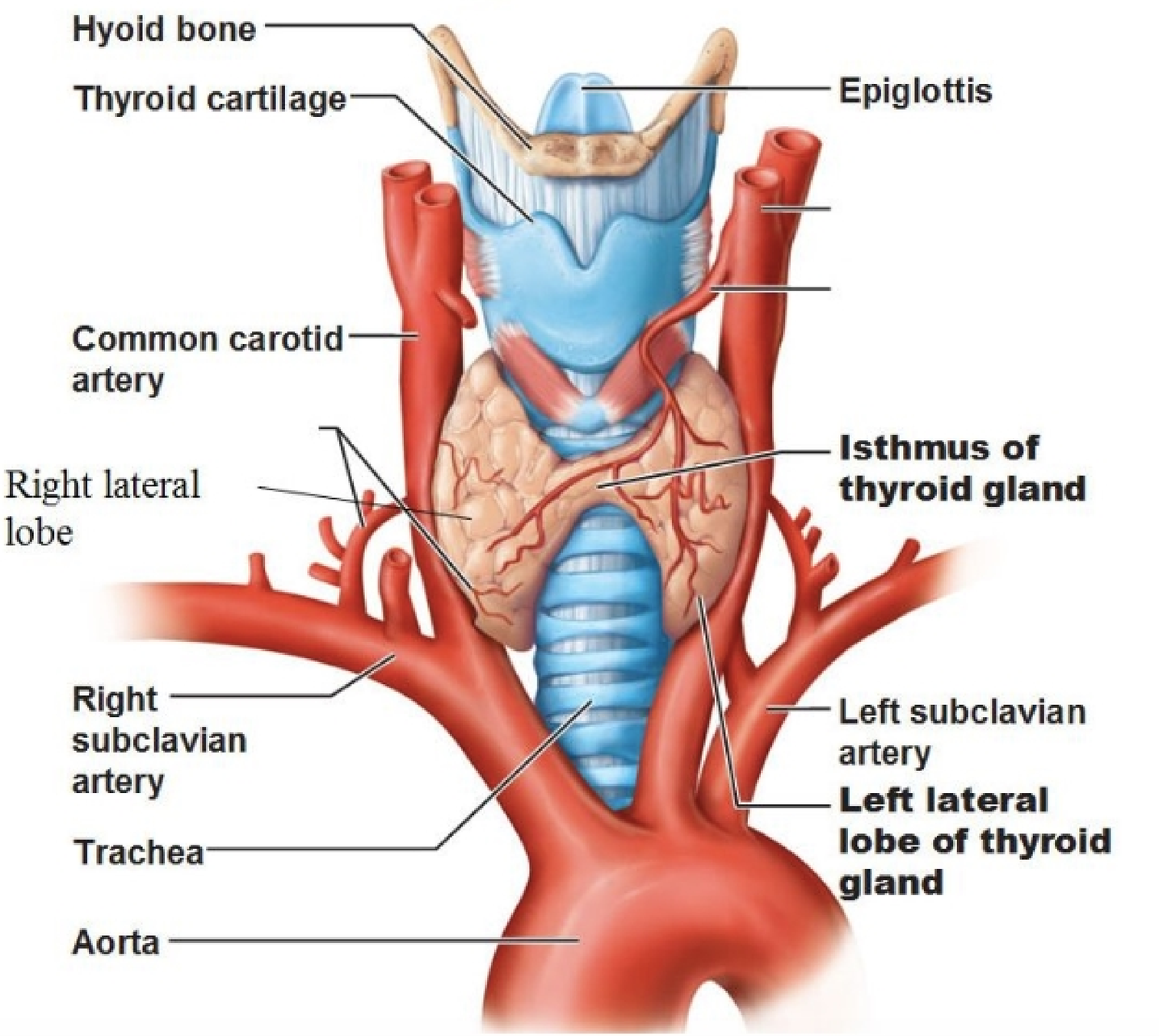

PARATHYROID

- Posterior to the Thyroid capsul, superior and inferior
- The feeding artery is mostly coming from Inferior Thyroid Artery

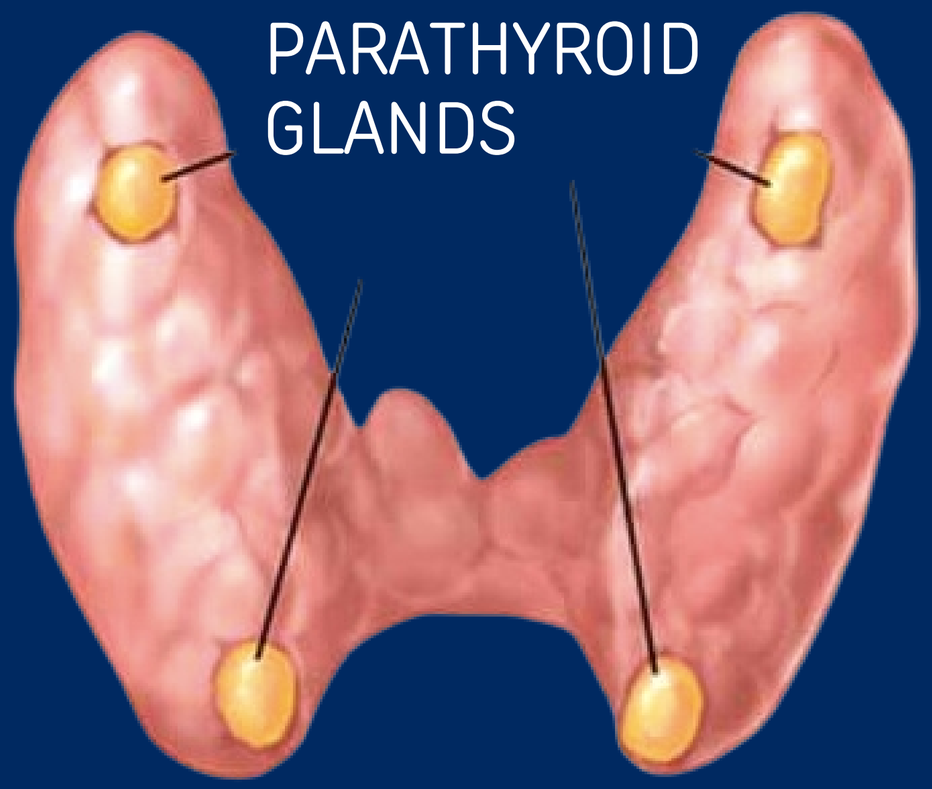

Tyroglosal duct cyst

- Benjolan pada midline
- Berkaitan dengan os Hyoid
- Tidak nyeri, bila terinfeksi nyeri
- Keluhan sulit atau gangguan menelan

Thyroglossal cyst

Tyroglosal duct cyst

Embryonal berasal dari foramen caecum
Dapat tumbuh sepanjang tyroglosal track
Paling sering pada os Hyoid

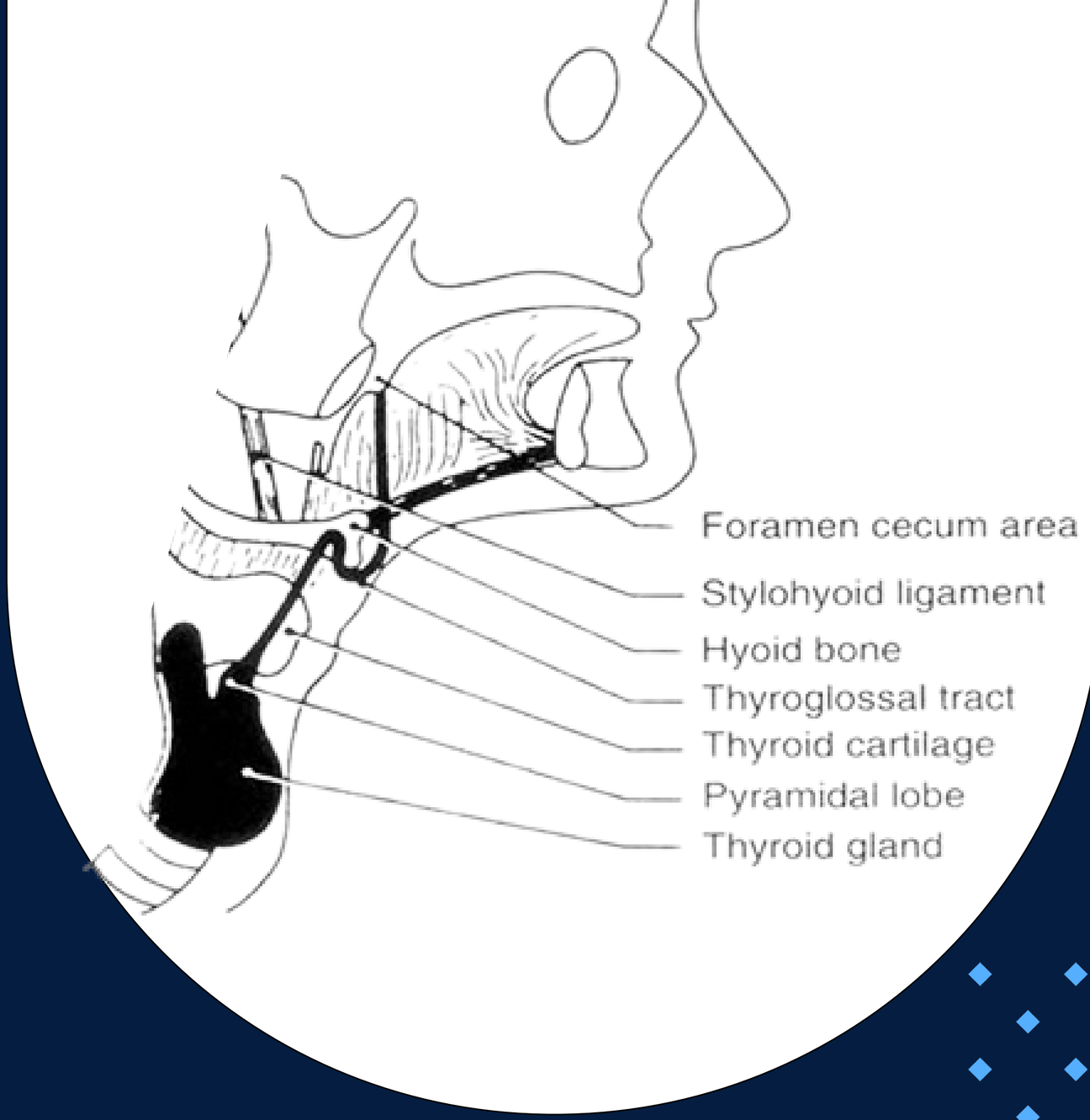

Departemen THT - BKL
Fakultas Kedokteran Universitas Trisakti

dr. Ibnu Harris Fadillah, Sp.THTBKL,Subsp.Onk (K)

Klinis
Tyroglosal duct cyst

- **Benjolan pada midline**
- **Ikut terangkat saat menjulurkan lidah (os Hyoid)**
- **Berkaitan dengan insidensi ectopic thyroid atau Lingual thyroid**

Learn More

Lymphatic System

Sistem limfatik bertanggungjawab mengembalikan cairan dari jaringan menuju darah dan melindungi tubuh dari material asing

Read More . . .

- Yang termasuk dalam Lymphatic system adalah : **cairan limf**, **pembuluh limfatik** (lymphatic vessel), dan **jaringan limfatik** (node/kgb, spleen/limpa, kelenjar thymus)

Learn More

Pembuluh Limfatik

- Dimulai dari ujung kapiler limfatik yang sangat permeable dalam mengumpulkan cairan dan protein, menuju pembuluh limfatik yang lebih besar yang memiliki katup seperti vena menuju satu arah.
- ***Skeletal pump***, mencegah aliran balik pada pembuluh limfatik tungkai. ***Respiratory pump***, pada rongga thorax memungkinkan cairan limf tetap bersirkulasi.
- Cairan limf kembali ke darah sebagai plasma.

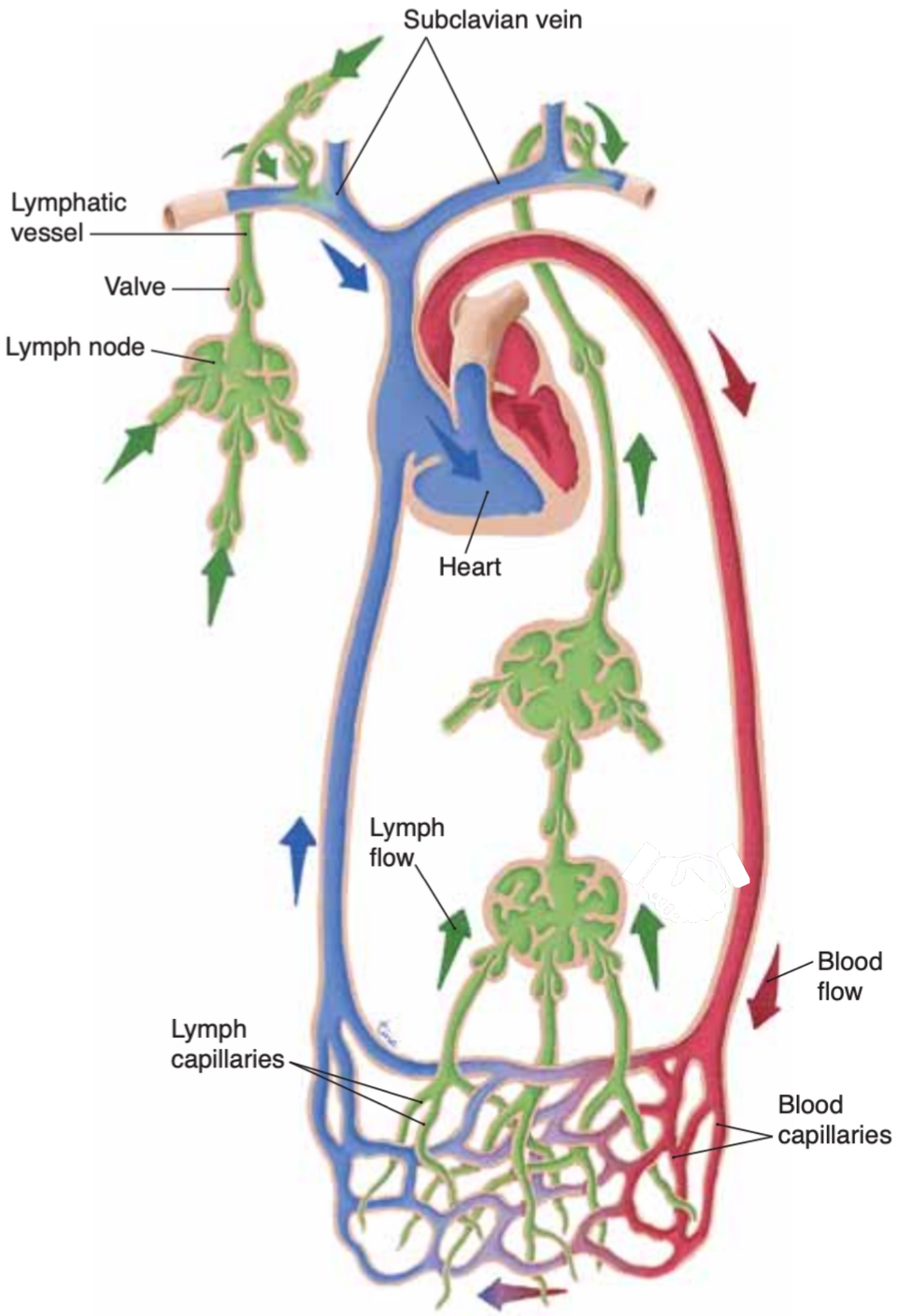

PEMBULUH LIMFATIK

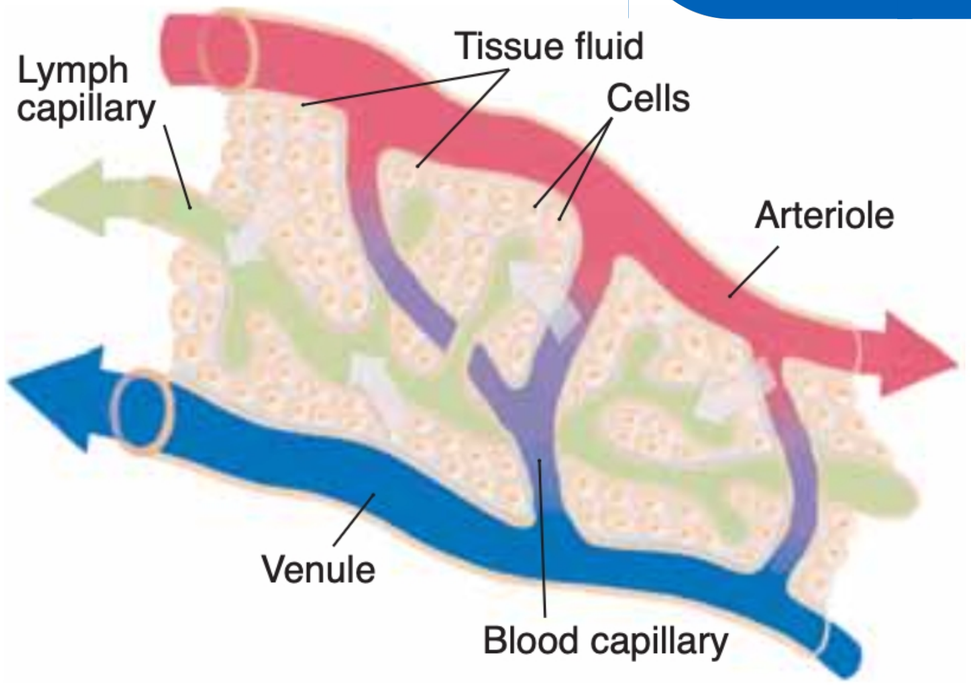

Figure 14–2. Dead-end lymph capillaries found in tissue spaces. Arrows indicate the movement of plasma, lymph, and tissue fluid.
QUESTION: Just before water enters lymph capillaries, what name does it have?

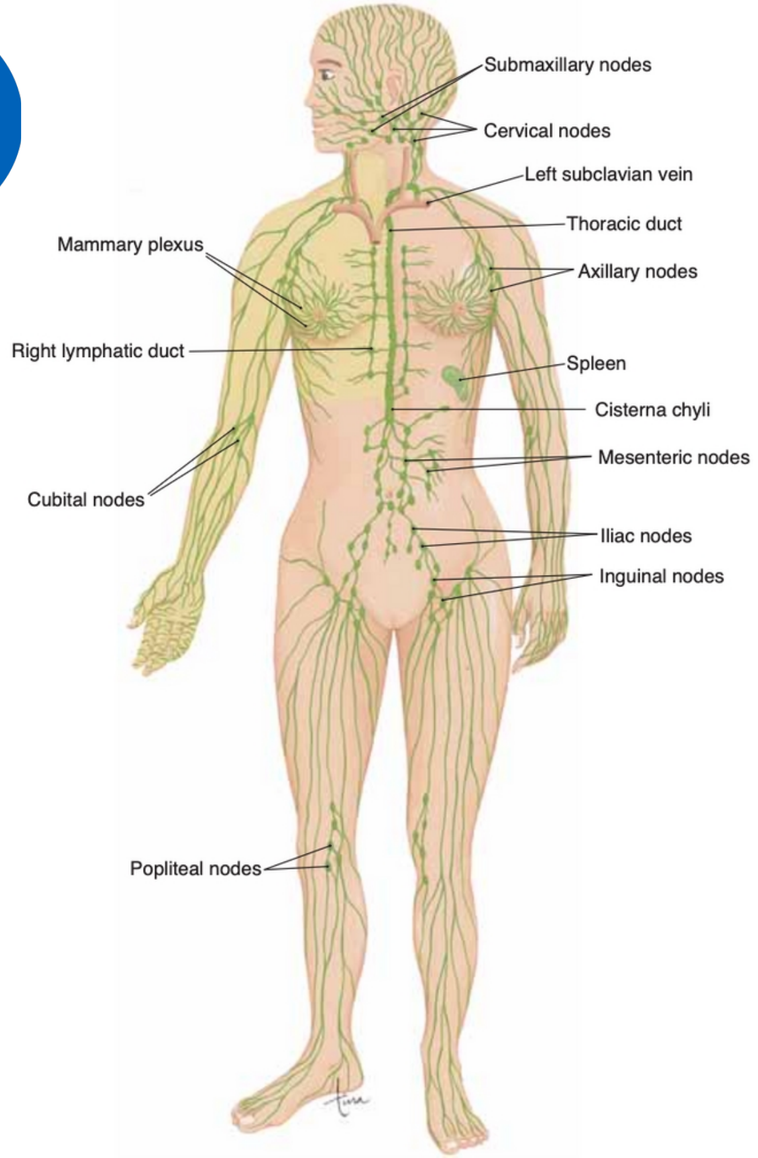

Figure 14–3. System of lymph vessels and the major groups of lymph nodes. Lymph is returned to the blood in the right and left subclavian veins.
QUESTION: Where are the major paired groups of lymph nodes located?

Jaringan limfatik (Tonsil dan adenoid)

- **Merupakan jaringan penghubung seperti kawat (mesh-like connective tissue) yang kaya akan limfosit yang dihasilkan dari stem sel bone marrow yang bermigrasi menuju limfanode, spleen dan thymus)**

- **Limfosit menjadi aktif dan berproliferasi sebagai respon terhadap infeksi**

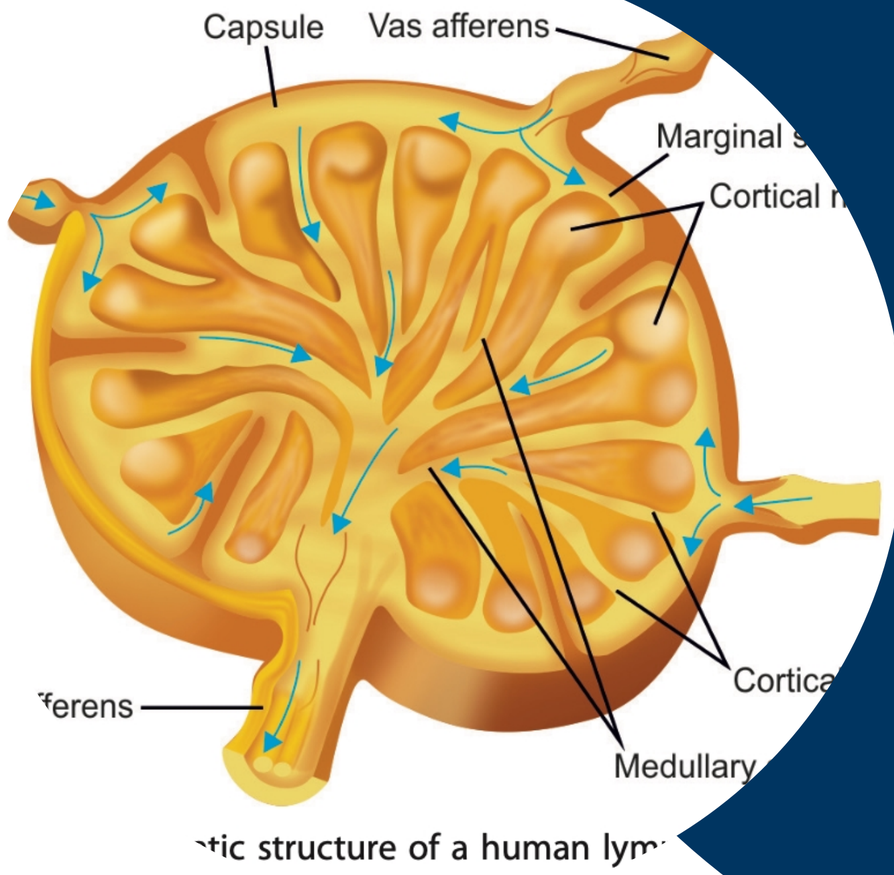

Learn More

Proses Metastasis KGB

a. Tumor menginduksi Limfangiogenesis intra-perintumoral dan invasi sel tumor pada sistem limfatik.
b. Pertumbuhan mikrometastasis pada sinus area.
c. Pembengkakan limfnode metastasis dan perubahan struktur pembuluh darah di dalamnya.
d. Penyebaran ektrakapsular dan pembentukan nekrotik area.

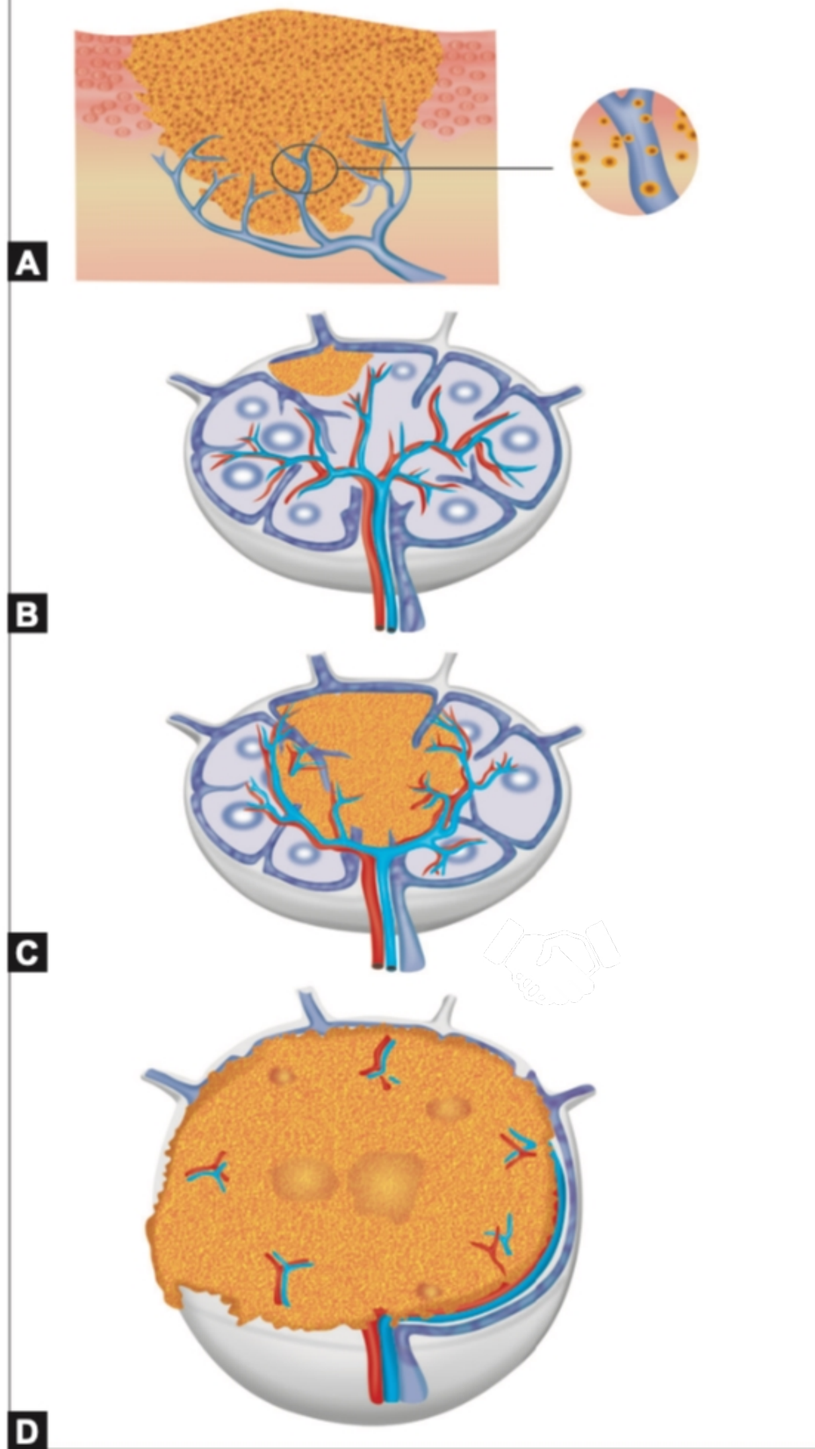

KEGANASAN KEPALA DAN LEHER

- Managemen benjolan leher sebagai bagian dari keganasan kepala dan leher sangat penting.
- Keterlibatan KGB leher pada keganasan ***upper aerodigestive tract*** dapat menurunkan angka harapan hidup 5 tahun dingga 50 %. (Shah.J)

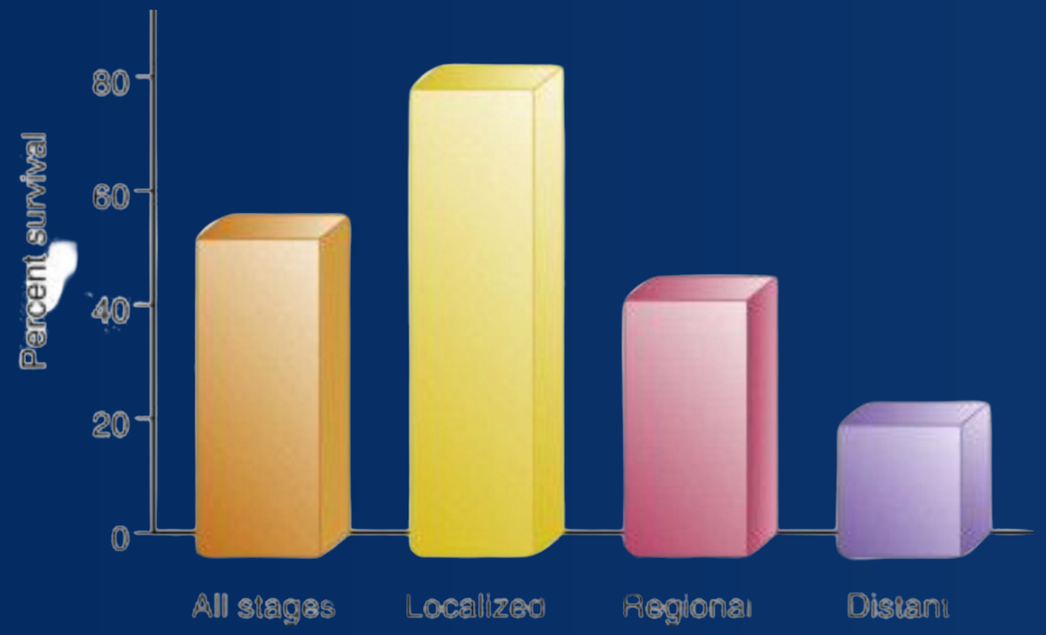

Figure 11-1 Five-year survival rates in patients with squamous cell carcinoma of the upper aerodigestive tract in relation to

PEMERIKSAAN KGB LEHER BAGIAN DARI PEMERIKSAAN THT

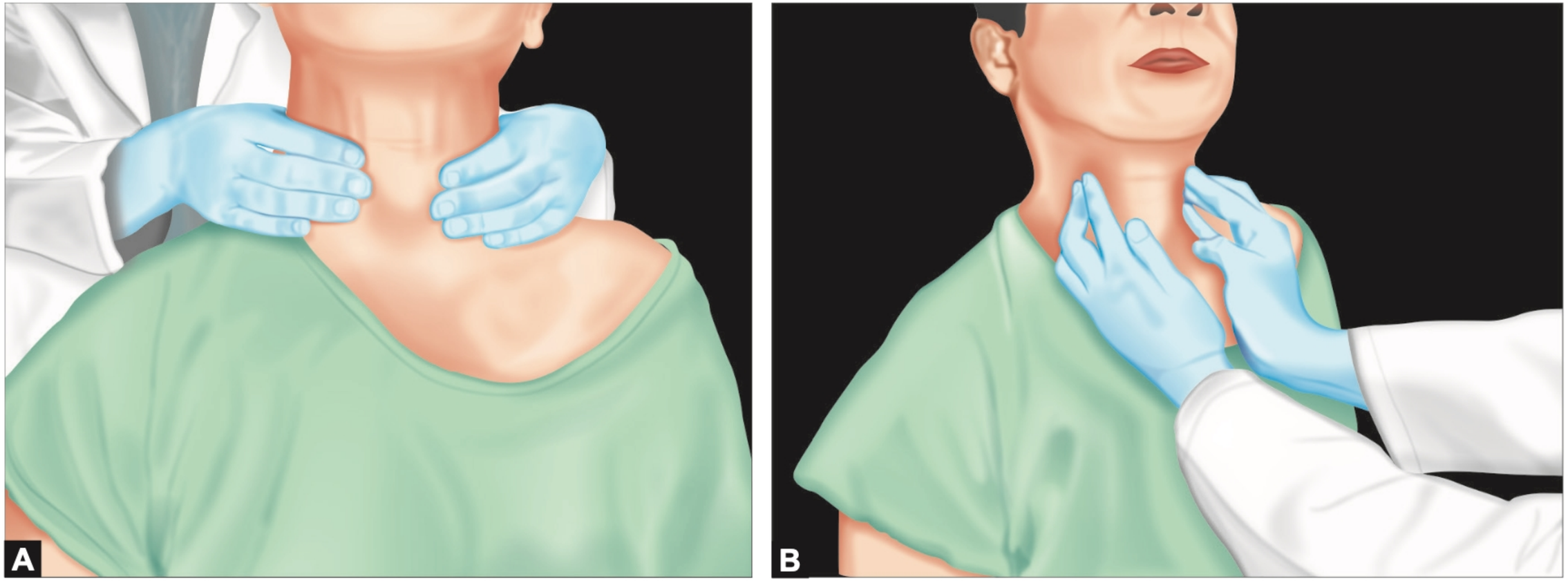

Figs. 3.4A and B: Palpation of the neck (A) from behind (correct) and (B) from in front (incorrect).

A & B gambaran metastasis leher Memorial Sloan-Katering Cancer Center

C, Modifikasi pembagian limfnode oleh AAOHNS

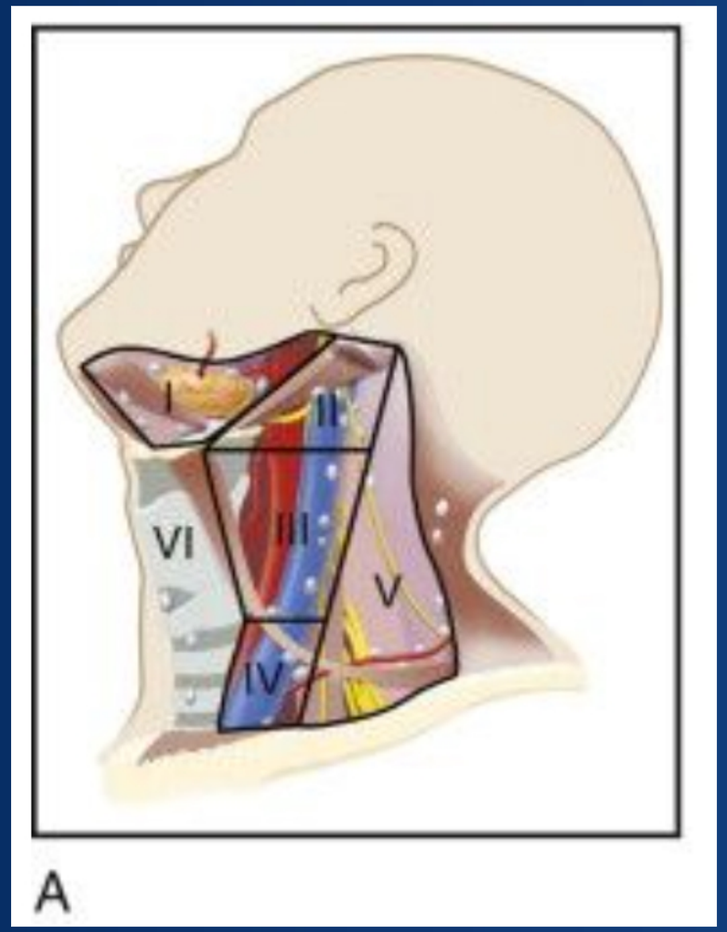

A

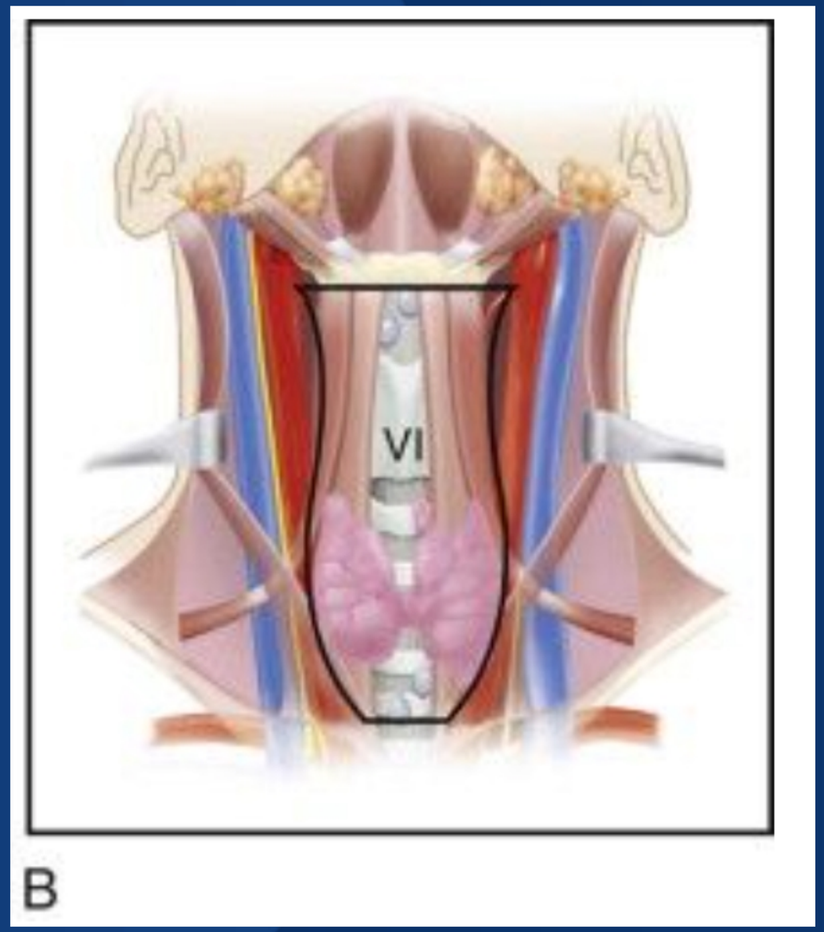

B

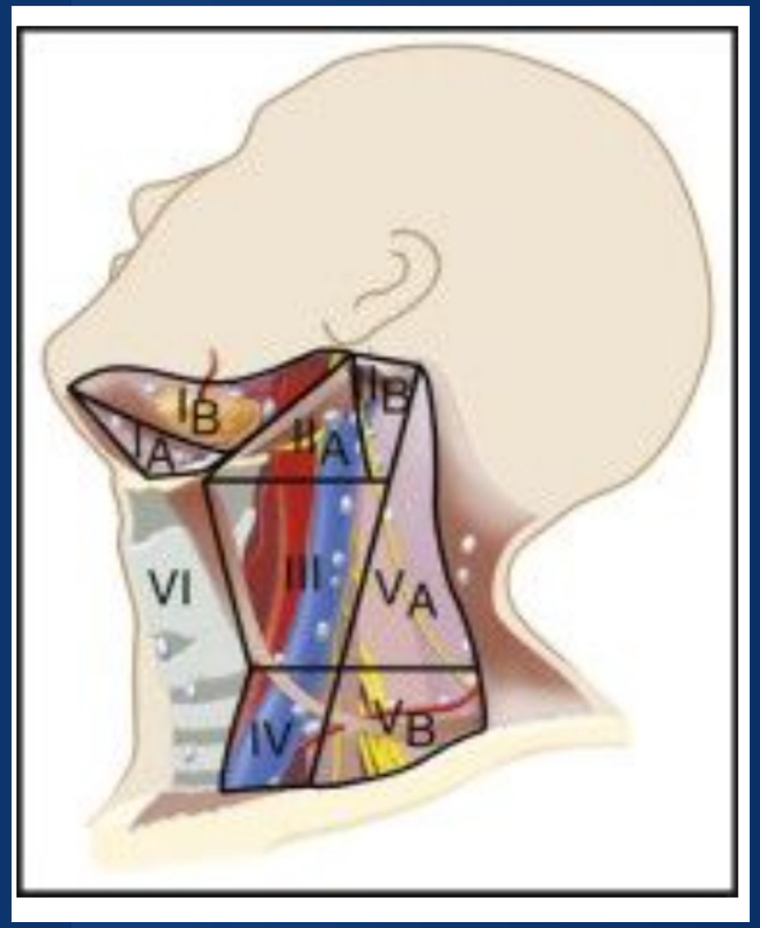

C

SISTEM LIMFATIK KEPALA DAN LEHER

- Drainase limfatik dari scalp dan skin kepala leher, mukosa aerodigestive, sinus paranasal, kelenjar saliva, kelenjar thyroid dapat diketahui dan dipetakan dengan baik.

- Jaringan Limfatik kepala dan leher berada pada 2 lapisan yang dipisahkan oleh ***deep servical fascia,*** superfisial limfatik dan deep jugular limfnode.

Learn More

Drainase limfatik kepala dan leher

- KGB periauricular, peri-intra parotis bertanggung jawab untuk daerah kulit wajah, fore-head dan bagian atas wajah.

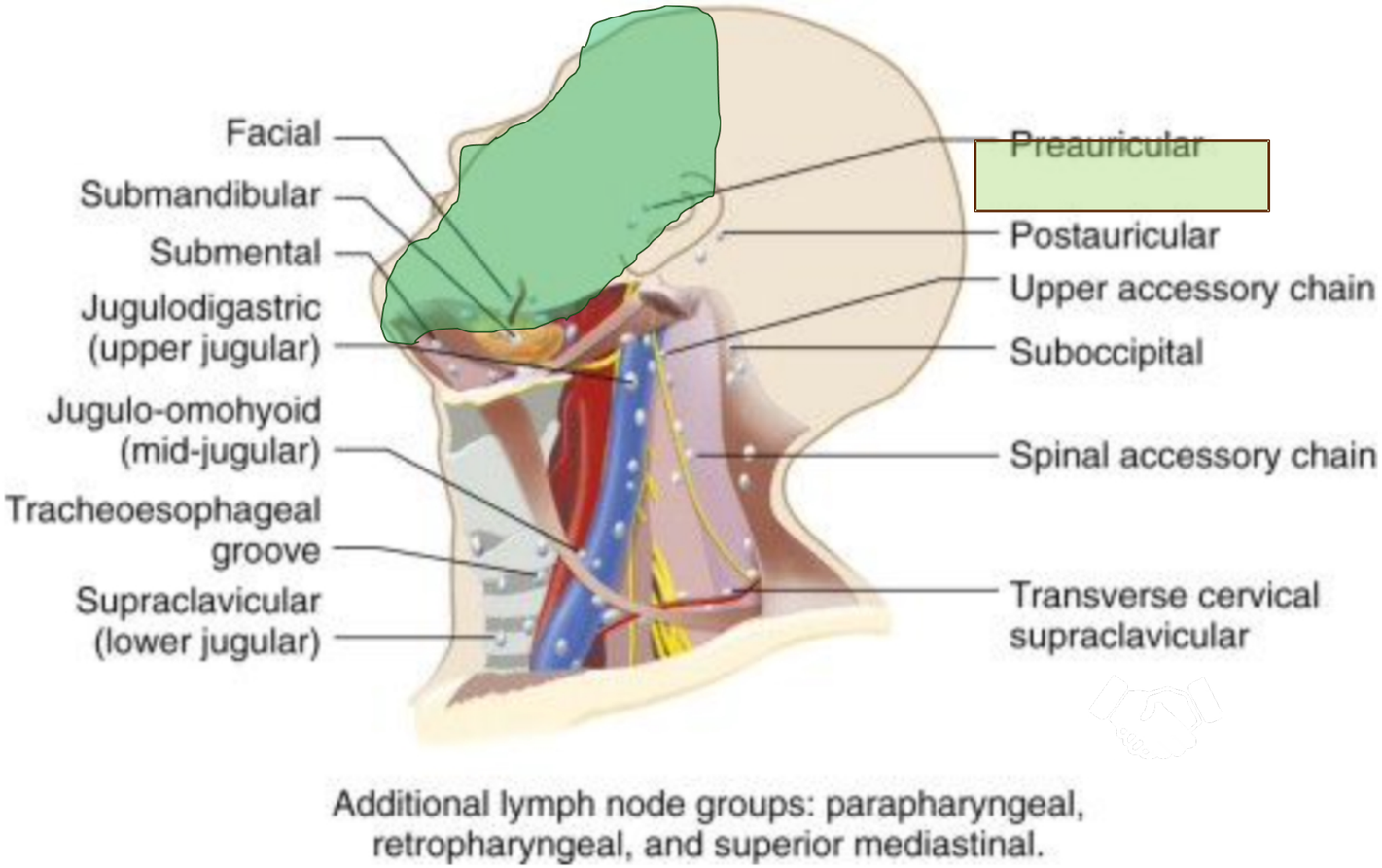

Figure 11-3 The regional lymph nodes of the head and neck region.
(Courtesy Memorial Sloan-Kettering Cancer Center.)

KGB PERI-INTRA

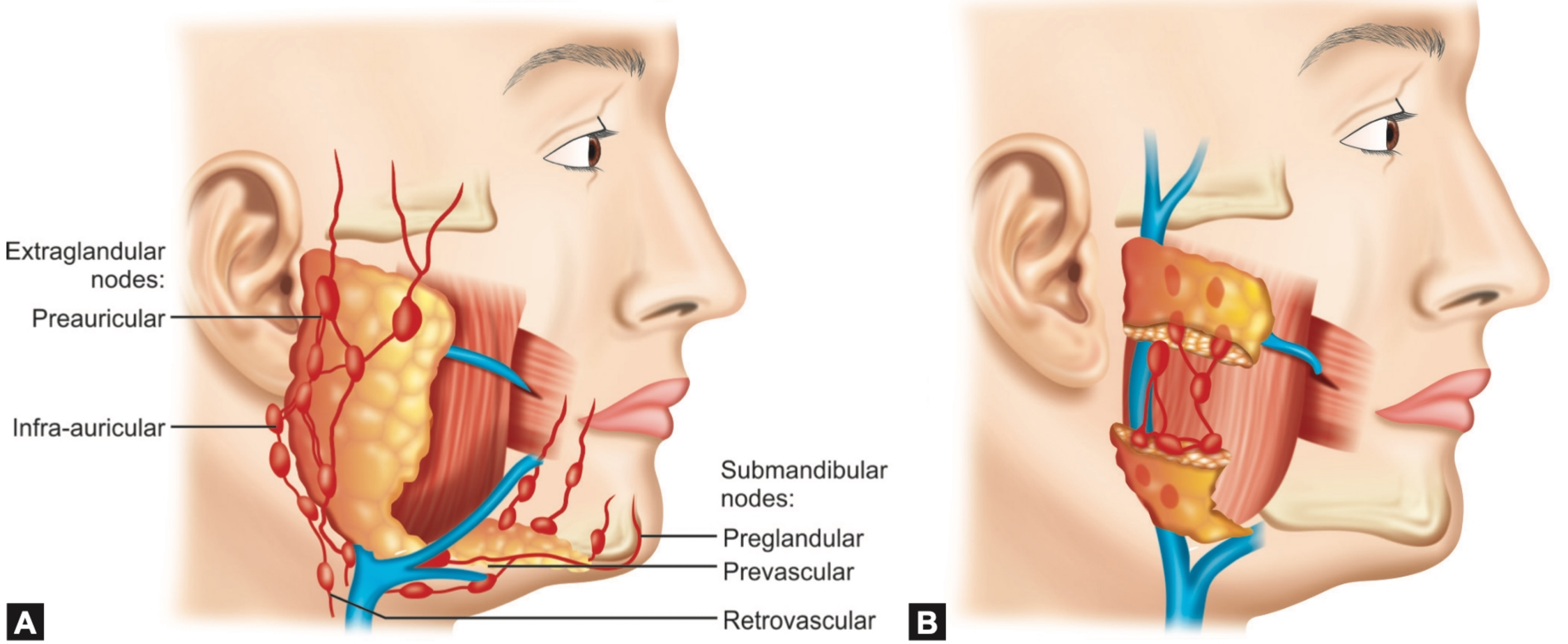

Figs. 4.6A and B: (A) Lymphatic distributions around the parotid and submandibular glands. (B) lymphatic distributions intra-parotid gland.

Learn More

Drainase limfatik kepala dan leher

- Limfnode submental dan submandibular bertanggung jawab untuk mukosa upper aerodigestive tract.

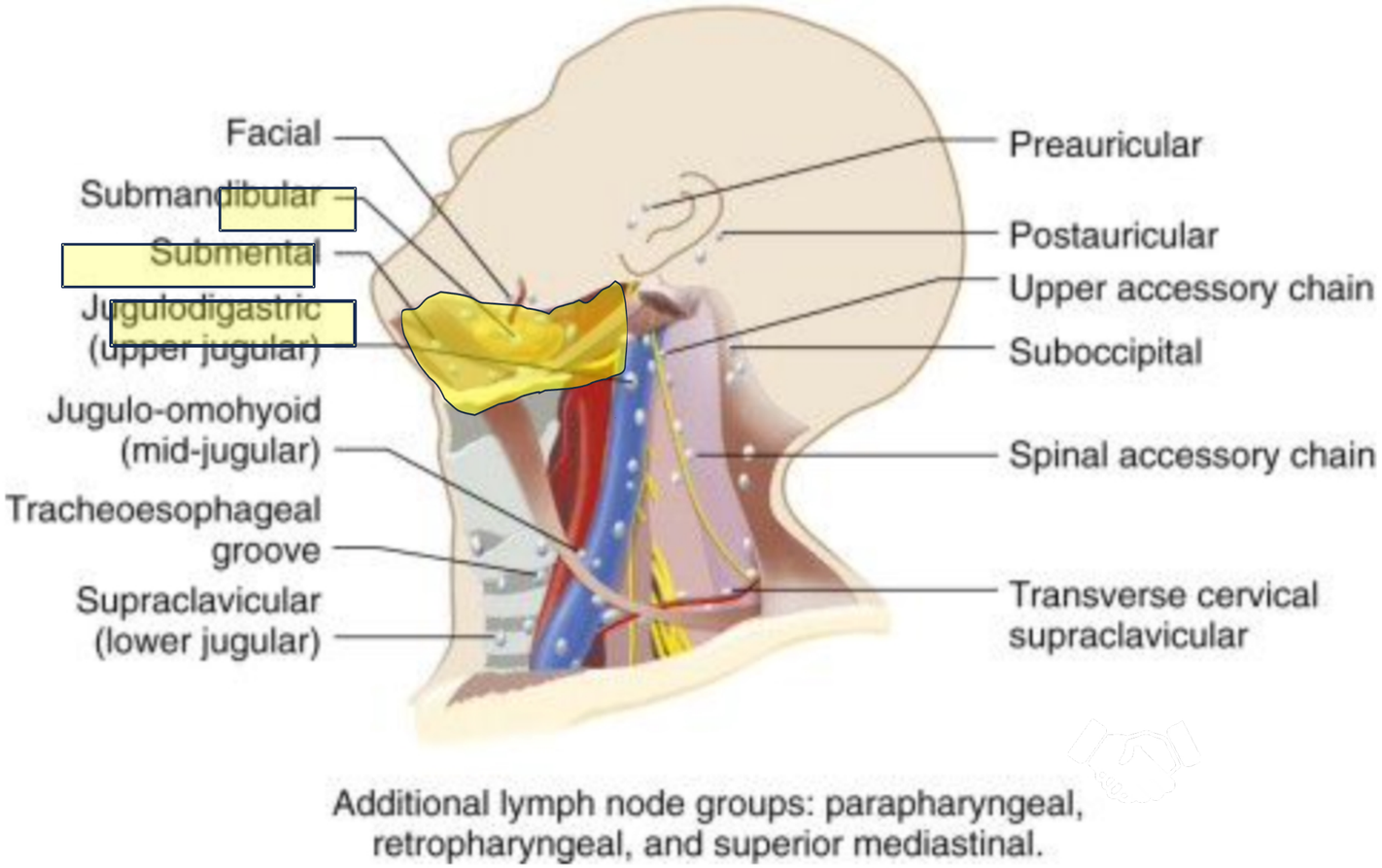

Figure 11-3 The regional lymph nodes of the head and neck region.
(Courtesy Memorial Sloan-Kettering Cancer Center.)

Learn More

Drainase limfatik kepala dan leher

- KGB post auricular dan suboccipital bertanggung jawab terhadap scalp posterior dan bagian belakang dari aurikula.
- Deep jugular limfnode jugulodigastric, jugulo-omohyoid, supra klavikular ,melekat pada IJV.

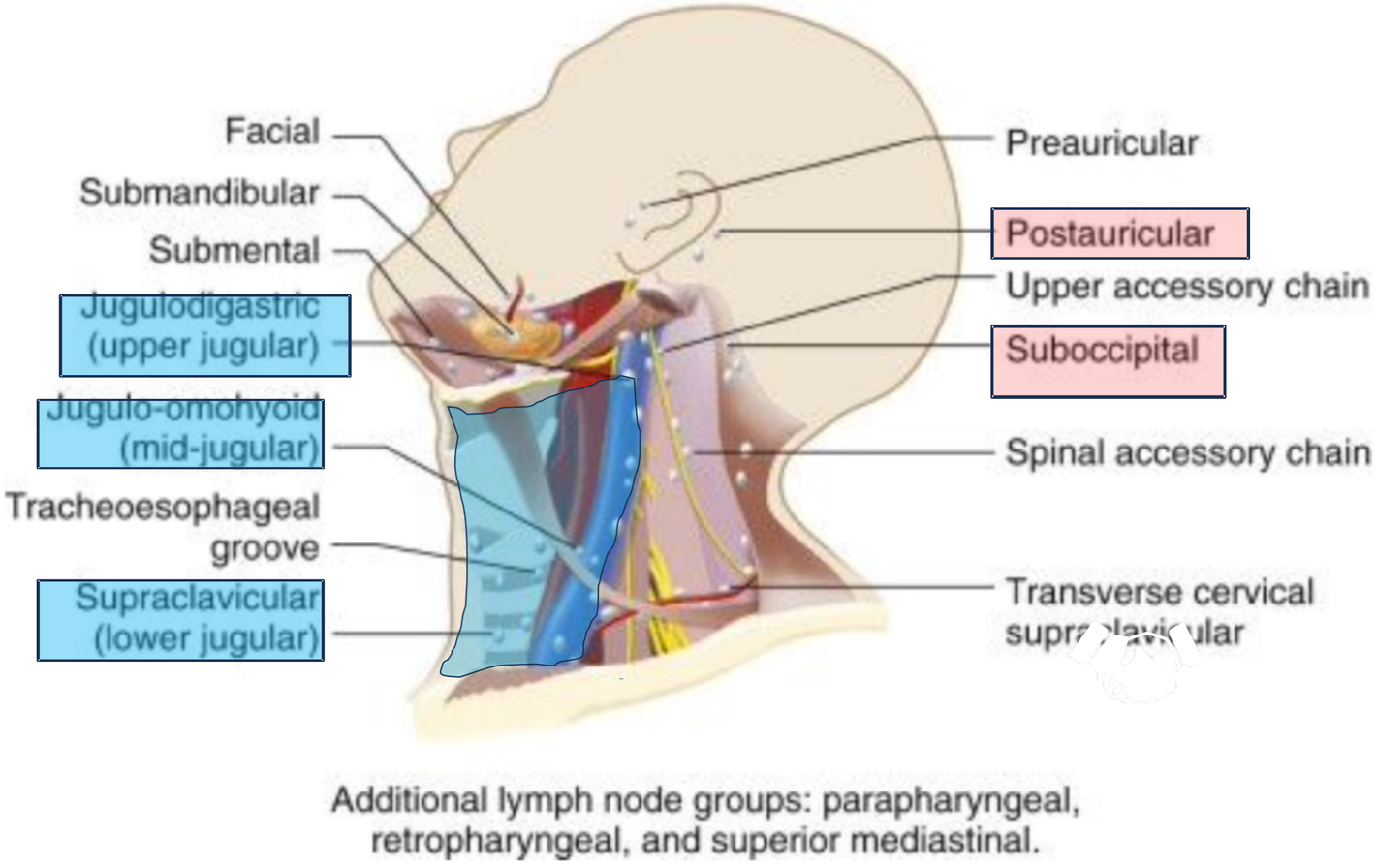

Figure 11-3 The regional lymph nodes of the head and neck region. *(Courtesy Memorial Sloan-Kettering Cancer Center.)*

Learn More

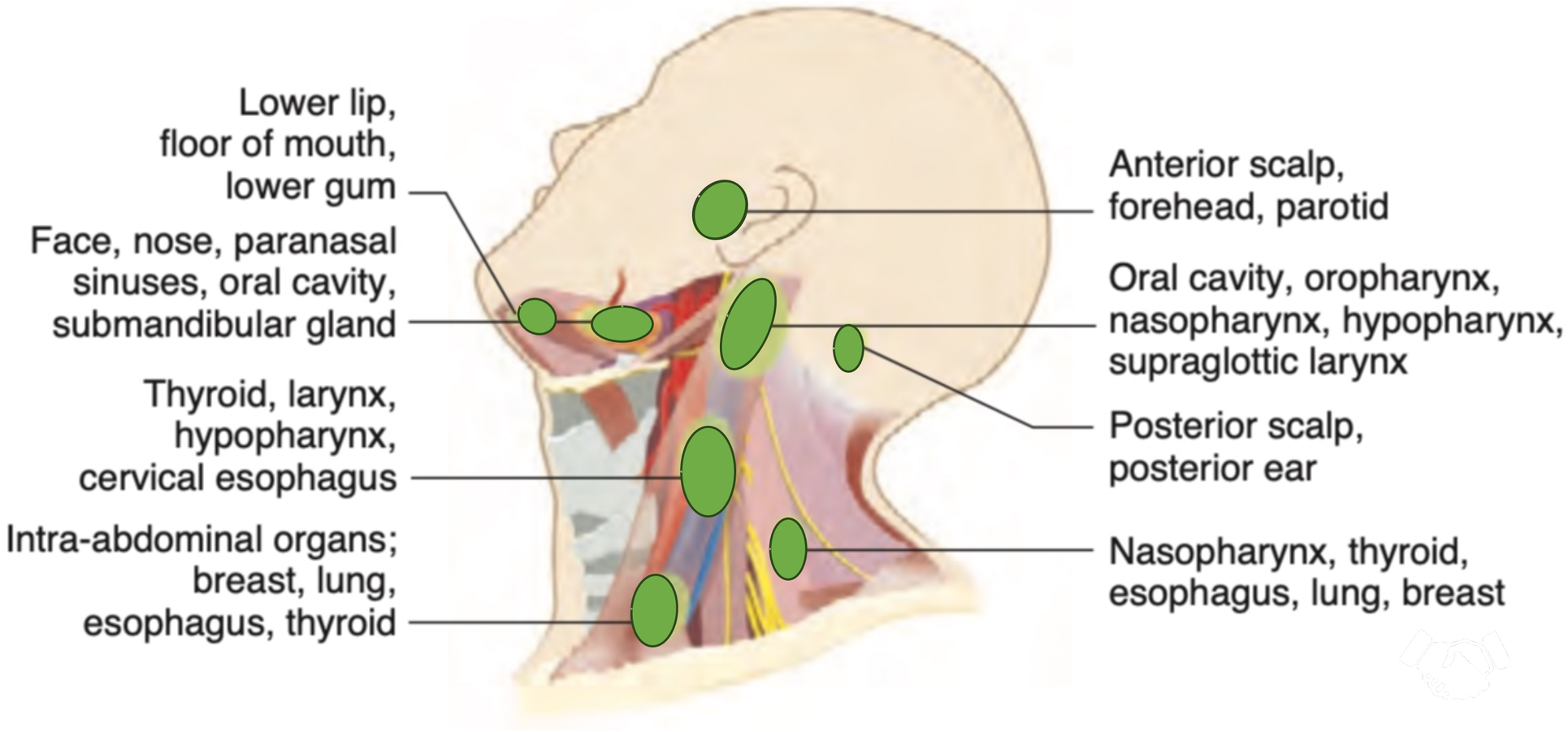

Figure 11.4 The regional lymph node groups draining a specific primary site as first-echelon lymph nodes. *(Courtesy Memorial Sloan Kettering Cancer Center.)*

Learn More

Diagnosis Benjolan Leher

- Kategori diagnosis banding benjolan leher :
  1. Inflamasi
  2. Neoplasma
  3. Kongenital

- Terdapat 2 hal penting :
  Usia pasien
  lokasi benjolan leher

USIA PASIEN

Tiga Kelompok Utama

- **Pediatric dibawah 15 th**
- **Dewasa Muda 16-40 th**
- **Dewasa akhir diatas 40 th**

anak dibawah usia 15 th

Inflamasi merupakan kasus palling sering diikuti dengan kelainan kongenital dan neoplasma

Diatas Usia 40 th

kemungkinan neoplasma menjadi lebih tinggi seiring dengan bertambahnya usia, diikuti dengan kasus inflamasi dan semakin kecil kemungkinan kelainan kongenital.

LOKASI BENJOLAN LEHER

- Secara umum diagnosis benjolan leher yang berkaitan dengan keganasan adalah 10% dari kasus.
- Sebagian besar pembesaran kgb yang berkaitan dengan metastasis dari keganasan kepala leher ada pada regio 2 dan 3.
- Limfoma sering melibatkan kgb regio 2 dan 5.
- Sedangkan metastasis yang bukan limfoma dan bukan berasal dari keganasan kepala dan leher, biasanya melibatkan KGB pada regio 4 dan 5.

LOKASI BENJOLAN

Table 60.1 Inflammatory, Neoplastic, and Congenital Neck Masses Based on Location

	Congenital	Inflammatory	Neoplastic	Other
Midline	Thyroglossal duct cyst Dermoid Laryngocele Plunging ranula Ectopic thyroid tissue	Adenitis	Thyroid	Prominent thyroid or cricoid cartilage
Anterior triangle	Branchial cleft cyst Thymic cyst	Thorotrast granuloma Sialadenitis (submandibular, parotid)	Metastatic disease • Face • Oral cavity • Oropharynx • Hypopharynx • Larynx • Thyroid • Nasosinal primary tumors • Carotid body • Glomus • Paraganglioma • Parotid tumors • Submandibular gland tumors	Atherosclerotic carotid artery Prominent hyoid
Posterior triangle	Lymphangioma	Adenitis	Metastatic disease • Thyroid • Nasopharynx • Scalp	
Any	Lymphangioma	Adenitis (viral, bacterial, or granulomatous)	Lymphoma Metastatic thyroid Lipoma	

1. Stewart MG, Selesnick SH. Differential diagnosis in Otolaryngology Head and Neck Surgery. Thieme medical publisher, Inc. New York, 2011.

KARAKTERISTIK BENJOLAN

- **Ukuran (Size)**
  Ukuran <1 cm umumnya jinak atau proses inflamasi
  Ukuran >1,5 cm memerlukan evaluasi lanjutan, resiko keganasan

- **Mobilitas (Mobility)**
  Lesi jinak umumnya dapat digerakan/mobile dan tidak terfixir
  Lesi yang terfixasi umumnya ganas atau tahapan lesi jinak yang lebih lanjut seperti pada Ductus thyroglosus cyst dan Carotid vagal paraganglioma yang tidak dapat digerakan cranio-caudal

KARAKTERISTIK BENJOLAN

- **Lunak (Soft)**

  Lesi jinak umumnya lunak pada perabaan
  Limfoma biasanya terpisah, rubbery, lembut (nontender), evaluasi sistemik diperlukan pada kecurigaan limfoma.
  Lymphangioma (Cyst Higroma) lunak, soft, kebiruan
  Hemangioma, lunak, dapat ditekan, kemerahan
  Ductus thyroglosus, midline, terikat pada os Hyoid

KARAKTERISTIK BENJOLAN

- **Batas tegas (Firm)**

  Kelanjar getah bening yang berbatas tegas dan terfiksasi mengarah pada keganasan Teratoma, hemangioma dan tortikolis dapat menunjukan batas yang tegas dan dapat dibedakan

  Neuroma, paraganglioma biasanya memiliki batas yang tegas dengan manifestasi neurologi.

KARAKTERISTIK BENJOLAN

- **Kekerasan (Hard)**
  Kartilago thyroid yang prominen sering dianggap sebagai massa

- **Pulsasi (Pulsatile)**
  Semua massa yang menempel pada karotis dapat menimbulkan pulsasi dan harus dapat dibedakan apakah pulsasi berasal dari karotis atau pulsasi massa itu sendiri.

  Paraganglioma, melekat pada karotis
  Hemangioma, pseudoaneurysme, congenital artery venous malformation origin dari pembuluh darah.

KARAKTERISTIK BENJOLAN

- **Durasi waktu**
  Massa tumor yang tumbuh melambat (slow growing) umumnya jinak sedangkan yang membesar dengan cepat (rapidly enlarging) harus dicurigai suatu keganasan sampai dibuktikan sebaliknya.

PEMERIKSAAN PENUNJANG

1. Endoskopi UADT
2. USG
3. CT scan kontras/MRI
4. FNAB

GAMBARAN KLINIS

- Abses parafaring

GAMBARAN KLINIS

Angina Ludovici

GAMBARAN KLINIS

Bezold abses

GAMBARAN KLINIS

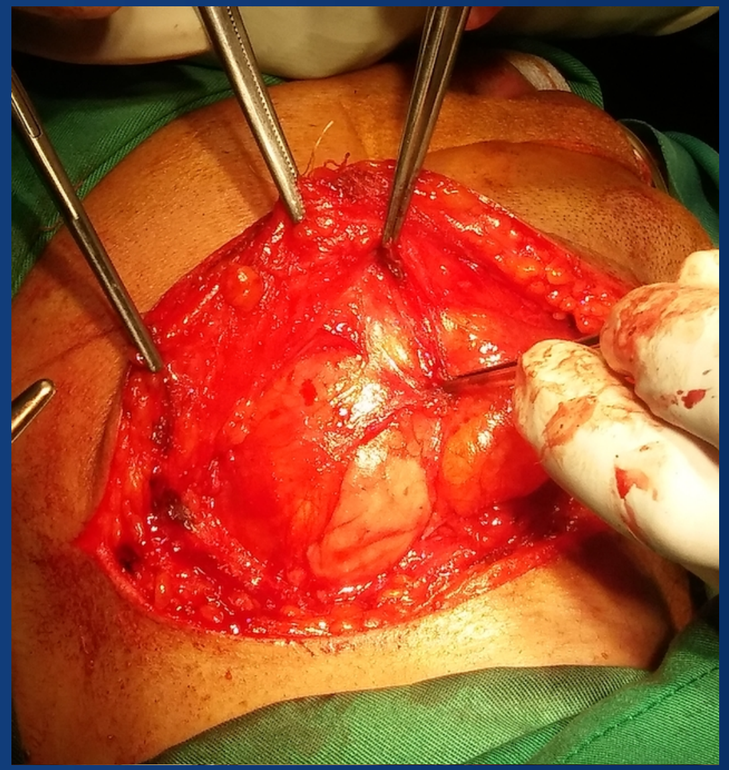

Kista submandibula

GAMBARAN KLINIS

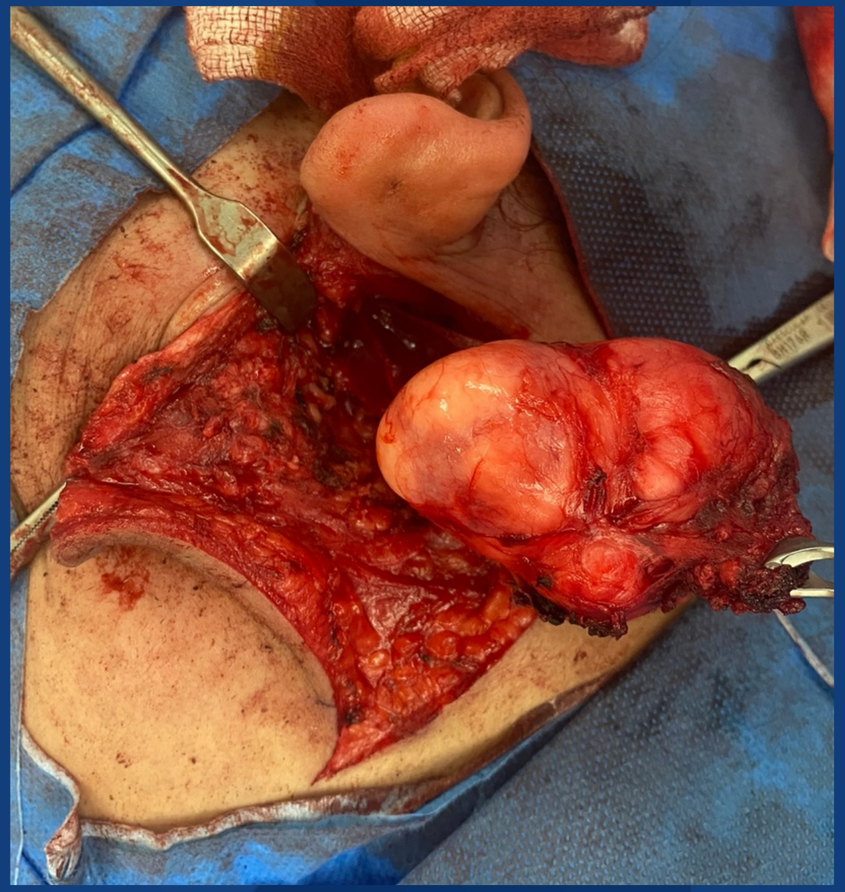

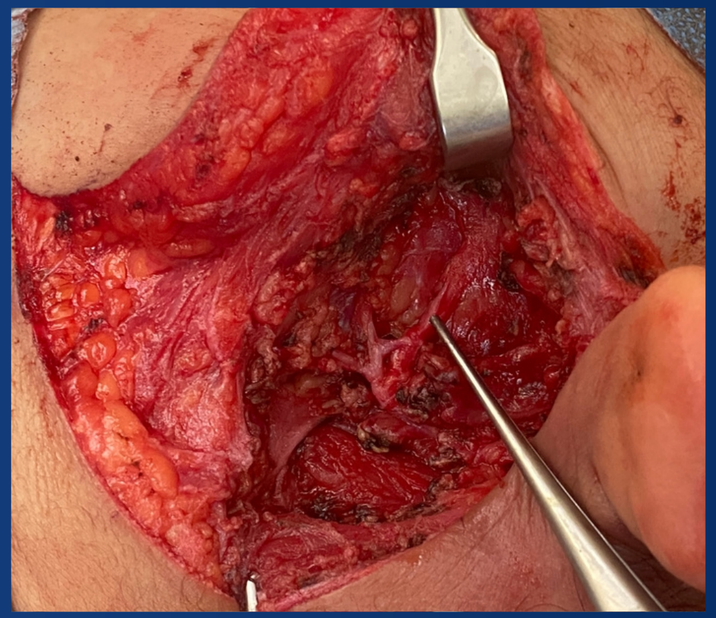

Adenoma pleiomorfik parotis

GAMBARAN KLINIS

Ca Mukoepidermoid Parotis

GAMBARAN KLINIS

Kanker Nasofaring

GAMBARAN KLINIS

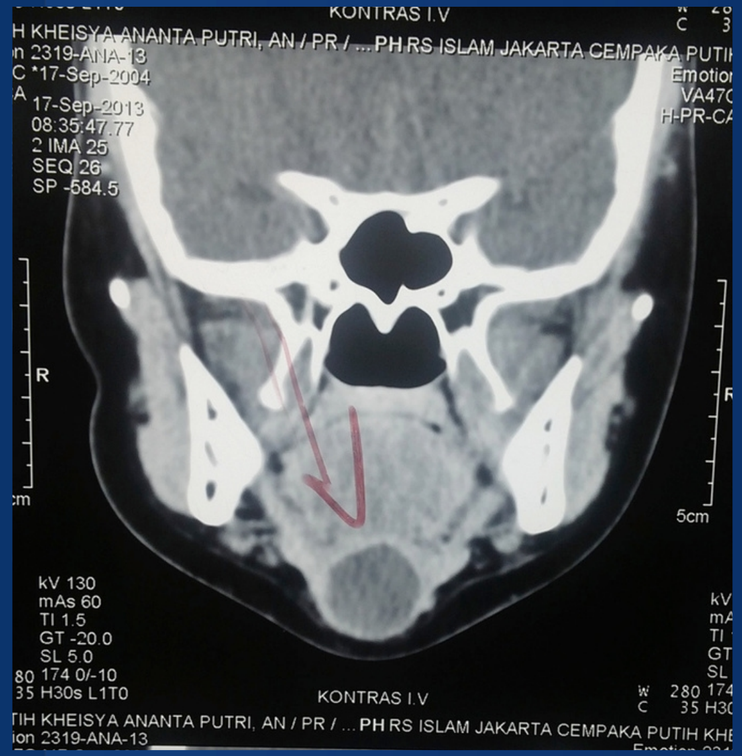

Kista ductus thyroglosus

SISTRUNK PROCEDURE



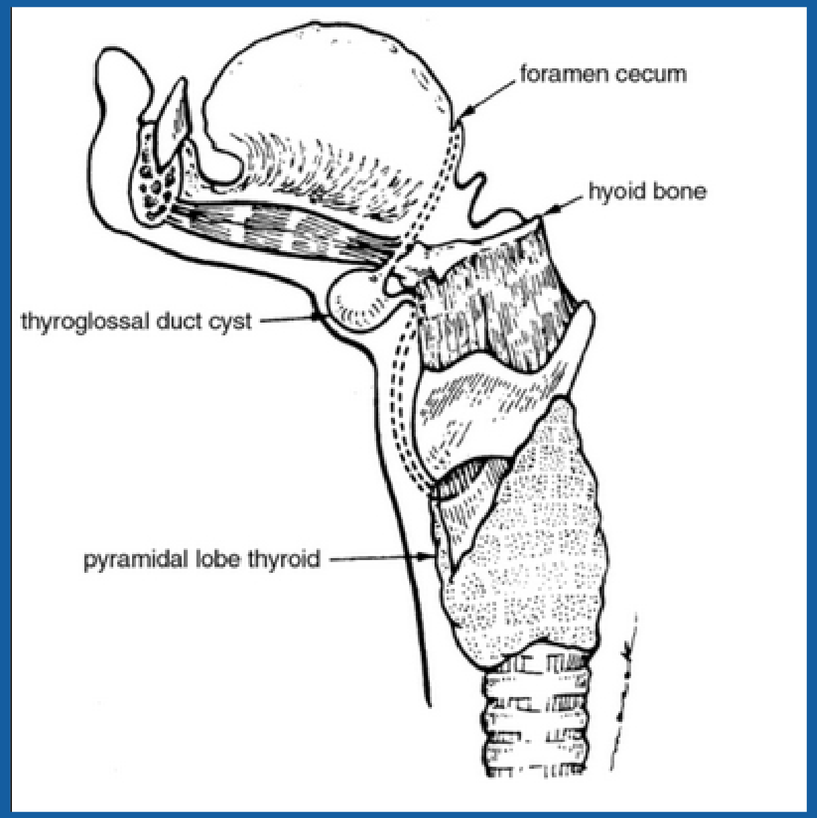

GAMBARAN KLINIS

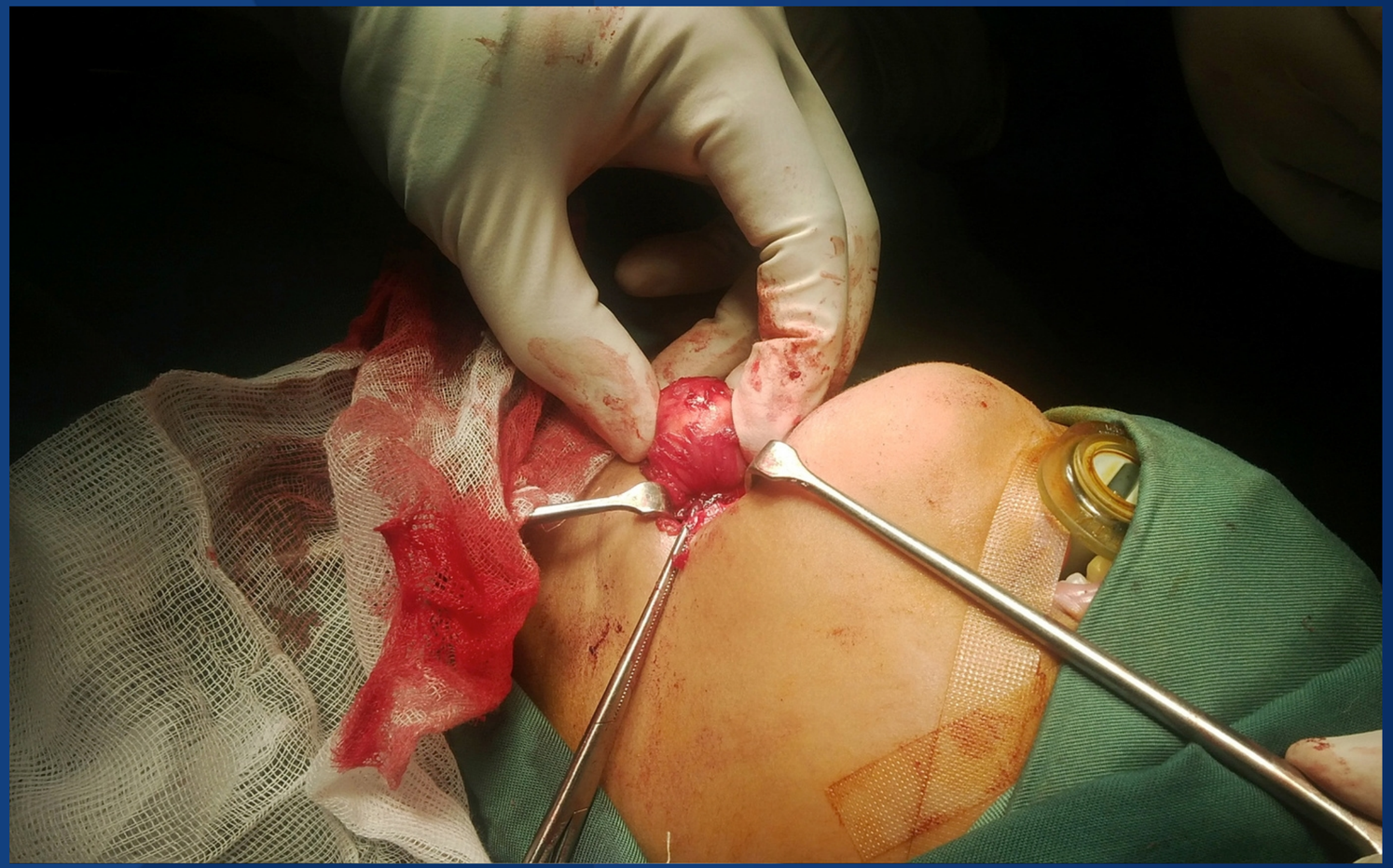

Kista ductus thyroglosus

GAMBARAN KLINIS

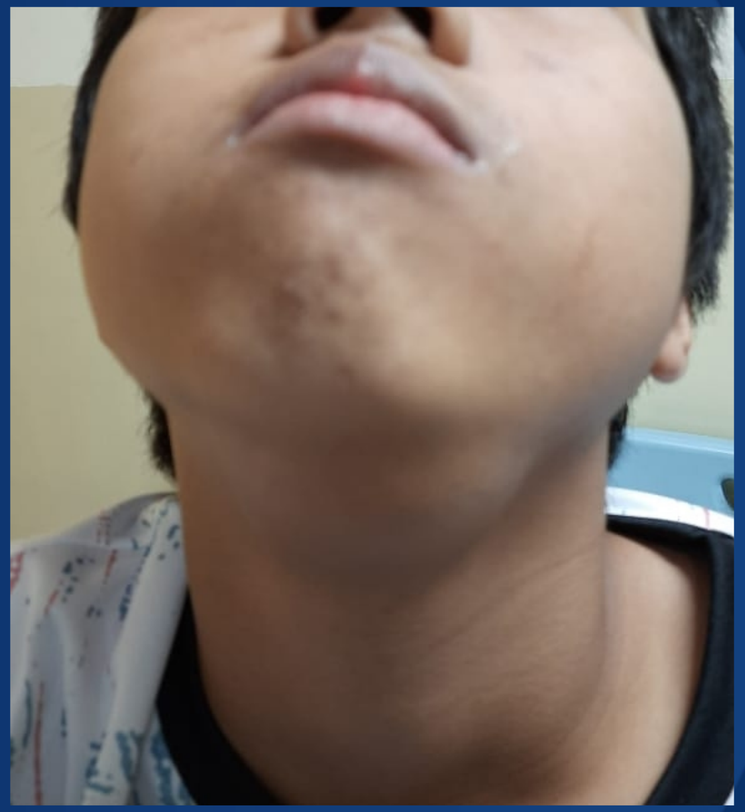

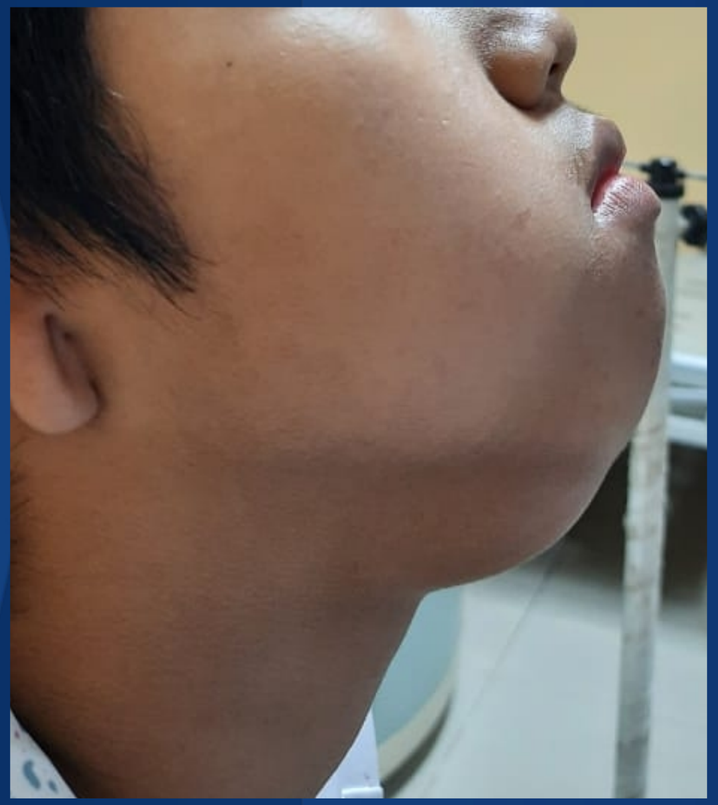

Giant Ranula

GAMBARAN KLINIS

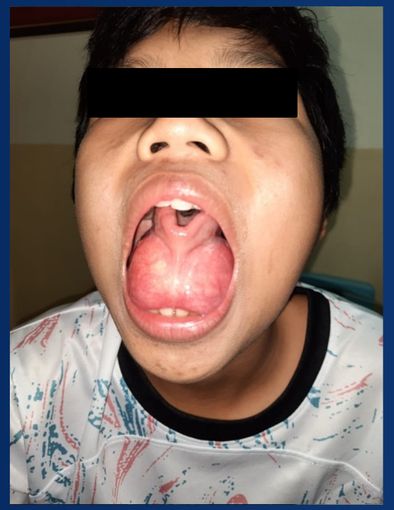

Giant Ranula/ plunging ranula

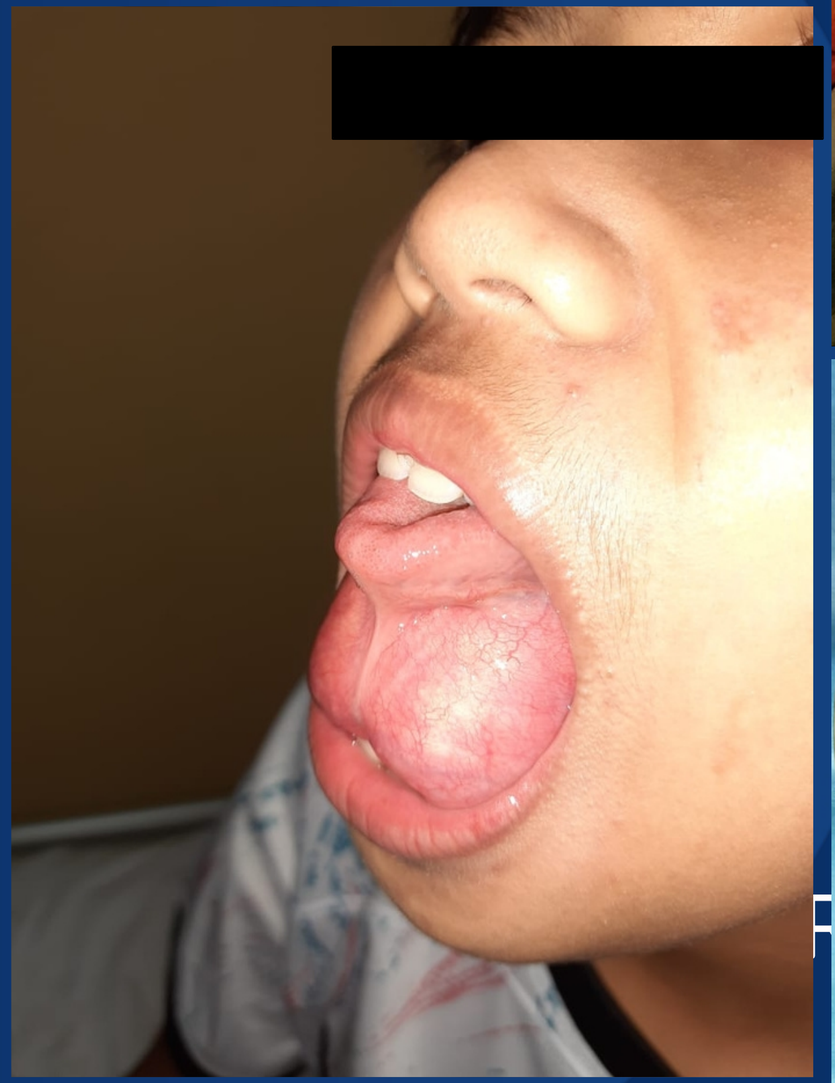

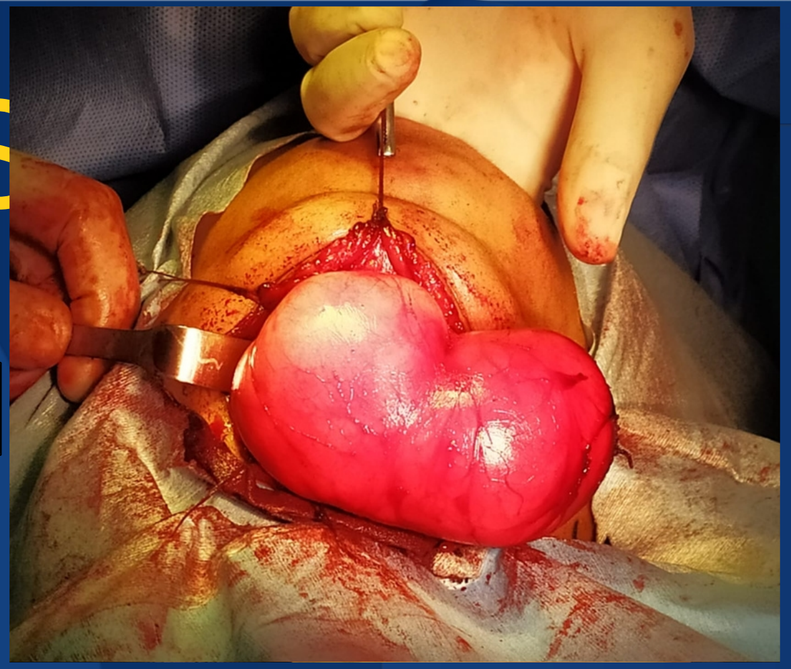

GAMBARAN KLINIS

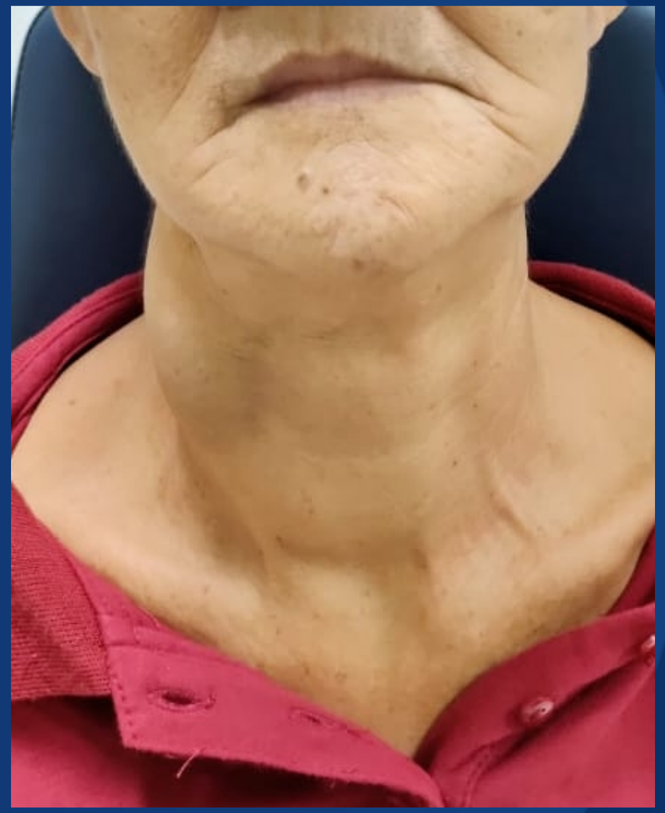

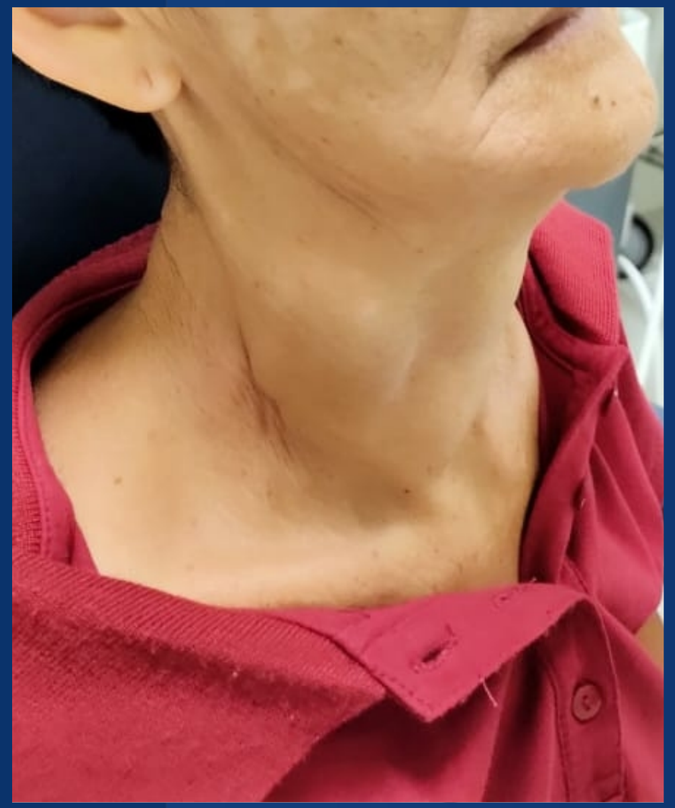

Ca Thyroid

Presentation to tertiary care

	Child <15 years	Young adult 16–40 years		Late adult >40 years	
First visit	History Fluctuation is size Symptoms and size–weight loss, night sweats, fever, supraclavicular area, mass >3 cms Examination of lump–position, number, size, shape, skin Examination of child–ENT, chest, other nodes, liver and spleen Blood tests, CXR, ultrasound Trial of antibiotics	History–social habits, addictions, family, hospitalization, medications, HIV, travel, employment Symptoms–local and systemic Examination of lump–position, size, number, shape, mobility, overlying skin Examine ENT–nasendoscopy, UgFNAC Offer free-hand FNAC–fluid/solid Blood tests, CXR, CT scan		History–social habits–smoking, drinking alcohol, medications, addiction, HIV, hospitalizations, travel, employment Symptoms–local and systemic Examination of lump–position, size, number, shape, mobility, overlying skin Examination ENT–nasendoscopy, UgFNAC Offer free-hand FNAC–fluid/solid Blood tests, CXR, CT scan	
Second visit	Blood tests and CXR normal and size the same or increased	Blood tests and CXR abnormal	Blood tests and CXR normal Lump reducing is size	Lump–reducing in size CXR–normal FNAC–negative CT–small solid lesion (<2 cm)	Lump–cystic/solid CXR–normal FNAC–negative CT–cyst/solid	Lump–solid CXR–normal FNAC–malignant CT–solid	Lump–solid CXR–abnormal FNAC–malignant CT–solid/metastases
Action	Excisional biopsy	Treat	Discharge	Review 4 weeks Repeat FNAC	Excise	Panendoscopy ± Biopsy	Refer to oncologists

Learn More

Take Home Messages

- Melakukan pemeriksaan KGB leher dengan seksama sebagai bagian dari pemeriksaan THTKL.
- Memahami struktur anatomi dan pembagian regio KGB leher yang bertanggung jawab terhadap area kepala leher.
- Memahami karakteristik dari benjolan leher untuk dapat membedakan masing masing kelainan.
- Hindari insisional biopsy terutama untuk KGB yang dicurigai sebagai metastasis KNF.

KELOMPOK STUDI ONKOLOGI BEDAH KEPALA LEHER, PERHATI-KL

Website : https://www.kankertht-kepalaleher.info/

YouTube https://www.youtube.com/channel/UCgueWzXz4jynm8mC8tUw.

https://instagram.com/oncology_ent?igshid=6cu31h7teqqf

https://www.facebook.com/oncology.headneck

CABANG
BANTEN

INDONESIAN HEAD & NECK TEAM

TERIMA KASIH

dr. Ibnu Harris Fadillah, Sp.THTBKL,Subsp.Onk (K)

Departemen THT - BKL
Fakultas Kedokteran Universitas Trisakti

Referensi

CABANG BANTEN

1. Stewart MG, Selesnick SH. Differential diagnosis in Otolaryngology Head and Neck Surgery. Thieme medical publisher, Inc. New York, 2011.
2. Shah J. Head and Neck surgery and oncology, 4th ed. Elsevier, Philadelphia, 2012.
3. Scanlon VC, Sanders T. Essential of anatomi and physiology, 5th ed. FA Davis Company, Philadelphia, 2007.
4. Morton RP, Ahmad Z, Giles M. Symptom oriented otolaryngology head and neck surgery. Jaypee Brothers Medical Publisher P Ltd, Vol 1, 1 st ed, 2017.