

Surgical Outcomes of Lateral Ulnar Collateral Ligament Reconstruction Versus Repair for Posterolateral Rotatory Instability of the Elbow: A Systematic Review and Meta-analysis

by Erica Kholinne

Submission date: 07-Feb-2025 08:56PM (UTC+0700)

Submission ID: 2582059779

File name: 10.1177_23259671241299831.pdf (1.19M)

Word count: 7380

Character count: 38724

Surgical Outcomes of Lateral Ulnar Collateral Ligament Reconstruction Versus Repair for Posterolateral Rotatory Instability of the Elbow

A Systematic Review and Meta-analysis

Erica Kholinne,^{*†‡} MD, PhD, Zhan Herr Ng,[§] MBChB, MRCS, Maria Anastasia,^{†||} MD, Leonard Christianto Singjie,^{†¶} MD, Jae-Man Kwak,[#] MD, PhD, and In-Ho Jeon,^{**} MD, PhD
Investigation performed at the Faculty of Medicine, Universitas Trisakti, Jakarta, Indonesia

Background: The aim of surgical treatment for posterolateral rotatory instability (PLRI) of the elbow is to restore the integrity of the lateral ulnar collateral ligament (LUCL), with ligamentous reconstruction being the preferred option for recurrent symptomatic PLRI. However, there is no clinical evidence demonstrating the superiority of reconstruction versus repair. Treatment options currently depend on the cause of the LUCL injury and surgeon preference.

Purpose: To review studies comparing surgical outcomes of LUCL reconstruction versus repair in treating PLRI of the elbow.

Study Design: Systematic review; Level of evidence, 4.

Methods: This review was conducted according to PRISMA (Preferred Reporting Items for Systematic Reviews and Meta-Analyses) guidelines. A literature search was conducted on PubMed, Medline (via EBSCO), ProQuest, and ScienceDirect databases using the following keywords: “(lateral ulnar collateral ligament reconstruction)” OR “(lateral ulnar collateral ligament repair)” AND “(outcome).” Excluded were studies in languages other than English, those that included terrible triad injury, transolecranon fracture, radial head arthroplasty involvement, associated procedures, animal studies, and biomechanical studies. A total of 193 studies were identified after the initial search. The primary outcome measure was the Mayo Elbow Performance Score, which was compared between studies using a random-effects model.

Results: Overall, 20 studies (N = 646 patients) were included, with 445 of 646 patients (68.8%) in the LUCL reconstruction group and 201 of 646 patients (31.1%) in the LUCL repair group. All injuries in the included studies were traumatic. The LUCL reconstruction group had a longer follow-up period compared with the LUCL repair group (72.05 ± 43.51 vs 36.86 ± 21.19 months, respectively). The postoperative range of motion arc was similar in both the repair and reconstruction groups (135.02° ± 15.33° vs 133.60° ± 8.84°, respectively). Both LUCL repair and LUCL reconstruction resulted in good to excellent outcomes on patient-reported outcome measures; however, a superior rate of return to activity and a lower complication rate were found after LUCL reconstruction versus LUCL repair (8.3% vs 14.9%). Ulnar nerve event (2.3%) was the most common complication in both groups.

Conclusion: Findings indicated that LUCL reconstruction had a superior rate of return to activity and a lower complication rate compared with LUCL repair.

Keywords: elbow instability; lateral ulnar collateral ligament; reconstruction; repair

The Orthopaedic Journal of Sports Medicine, 13(1), 23259671241299831
DOI: 10.1177/23259671241299831
© The Author(s) 2025

Posterolateral rotatory instability (PLRI) is a common form of recurrent elbow instability that was described by O'Driscoll²⁵ in 1994, implicating the lateral ulnar collateral ligament (LUCL) as a primary restraint for PLRI.

This open-access article is published and distributed under the Creative Commons Attribution - NonCommercial - No Derivatives License (<https://creativecommons.org/licenses/by-nc-nd/4.0/>), which permits the noncommercial use, distribution, and reproduction of the article in any medium, provided the original author and source are credited. You may not alter, transform, or build upon this article without the permission of the Author(s). For article reuse guidelines, please visit SAGE's website at <http://www.sagepub.com/journals-permissions>.

The condition occurs as a result of axial loading, valgus force, and forearm supination.³ This is relatively due to the internal rotation of the humerus on a fixed forearm. However, the functional anatomy of the remaining lateral elbow stabilizing structures indicates that PLRI constitutes a more complex problem. A more recent biomechanical cadaveric study suggested that damage to the lateral collateral ligamentous complex as a whole may be responsible for PLRI.²⁷

Although PLRI generally occurs after elbow trauma, other causes include tardy PLRI secondary to cubitus varus deformity, severe lateral epicondylitis—especially after repeated corticosteroid injections, or iatrogenic injury after lateral elbow surgery. In most cases, the mechanism involves a combination of axial load, valgus force, and supination on the forearm, resulting in the disruption of the LUCL from its humeral origin. PLRI itself gives a spectrum of mechanical symptoms, such as pain, clicking, recurrent subluxations, and dislocations. If PLRI is left untreated, posttraumatic arthritis may develop as a result of joint incongruity and cartilage damage. Establishing the diagnosis of PLRI may be difficult and is often delayed because of its variable presentation.^{7,30}

The restoration of LUCL integrity is the main purpose of the surgical treatment of PLRI. Treatment options depend on the cause of the LUCL injury and the surgeon's preference. The choice to perform repair versus reconstruction typically depends on the chronicity of the injury and the quality of tissue available at the time of surgery. Surgical repair is more favorable for acute traumatic cases or in occasions where the tissue is still viable and has good healing potential.²⁴ Jones et al^{15,16} showed that UCL repair with internal bracing was more resistant under fatigue loading compared with UCL reconstruction. Meanwhile, the main approach for addressing recurring PLRI involves the restoration of the LUCL. Reconstruction is the recommended surgical treatment when there is long-term weakening or a notable insufficiency in the ligament tissue, particularly among athletes performing overhead activities and persons who are engaged in strenuous manual labor.²³ There is no clinical evidence demonstrating the superiority of either LUCL repair or reconstruction.

In the present review, we aimed to compare studies on the surgical outcome of LUCL reconstruction versus repair in treating PLRI of the elbow. Based on the existing literature, we hypothesized that the results of LUCL reconstruction and LUCL repair would be comparable and that outcomes would depend on the patients'

circumstances—such as injury severity and time from injury to treatment.

METHODS

Search Strategy and Study Selection

This study was conducted in accordance with the guidelines of the Preferred Reporting Items for Systematic Reviews and Meta-Analyses (PRISMA),²⁸ and the study protocol was registered in the PROSPERO International Prospective Register of Systematic Reviews (CRD42023418856). We searched 4 databases—including PubMed, Medline via EBSCO, ProQuest, and ScienceDirect—from inception until September 2022 for relevant studies using the following keywords, which conformed to MeSH (Medical Subject Headings) and Emtree: “(Lateral ulnar collateral ligament reconstruction) OR (Lateral ulnar collateral ligament repair) AND (outcome).” As the number of studies investigating LUCL injury and treatment was limited, we made no restrictions with respect to specific surgical techniques, publication status, or study period. After eliminating duplicate studies, 2 independent reviewers (M.A. and L.C.S.) screened the titles and abstracts for relevant studies according to the inclusion and exclusion criteria.

Inclusion and Exclusion Criteria

All included studies were original research publications in the English language. Studies that included diagnosis, imaging, or treatment with open or arthroscopic LUCL repair or reconstruction for PLRI were included. The exclusion criteria included studies that included terrible triad injury, transolecranon fracture, radial head arthroplasty involvement, associated procedures at the time of surgery, and animal and biomechanical studies. Conference abstracts were also excluded.

Quality Appraisal and Risk-of-Bias Assessment

Two authors (M.A. and L.C.S.) independently performed data extraction and quality assessment. Discrepancies between the authors were resolved by reassessment and discussion with a third author specializing in elbow surgery (E.K.). The level of evidence of each included study was assessed using the guidelines of the Oxford Centre for Evidence-Based Medicine.¹⁴ Quality appraisal and

*Address correspondence to Erica Kholinne, MD, PhD, Faculty of Medicine, Universitas Trisakti, Jl. Kyai Tapa No.1, RT. 5/RW. 9, Tomang, Kec. Grogol petamburan, Kota Jakarta Barat, Daerah Khusus Ibukota, Jakarta 11440, Indonesia (email: erica@trisakti.ac.id).

[†]St Carolus Hospital, Jakarta, Indonesia.

[‡]Faculty of Medicine, Universitas Trisakti, Jakarta, Indonesia.

[§]Department of Trauma and Orthopaedic Surgery, Queen Alexandra Hospital, Portsmouth, UK.

^{||}Department of Orthopedic and Traumatology, Udayana University, Bali, Indonesia.

[¶]Department of Orthopedic and Traumatology, Hasanuddin University, Makassar, Indonesia.

^{**}Department of Orthopedic Surgery, Uijeongbu Eulji Medical Center, Eulji University School of Medicine, Uijeongbu, Republic of Korea.

^{***}Department of Orthopaedic Surgery, Asan Medical Center, University of Ulsan College of Medicine, Seoul, Republic of Korea.

Final revision submitted March 30, 2024; accepted April 12, 2024.

The authors declared that there are no conflicts of interest in the authorship and publication of this contribution. AOSSM checks author disclosures against the Open Payments Database (OPD). AOSSM has not conducted an independent investigation on the OPD and disclaims any liability or responsibility relating thereto.

risk of bias were assessed using the Methodologic Index for Non-randomized Studies¹ (MINORS). The MINORS consists of a 12-item checklist comprising 8 items for noncomparative studies, with 4 additional items for comparative studies. Each item is scored from 0 to 2, with a maximum of 16 points for noncomparative studies and 24 points for comparative studies. Since the scoring system has no predefined cutoff, we considered the studies as high quality if the MINORS score was >60% (9/16 for noncomparative studies).

Data Extraction and Analysis

Data were extracted from the texts, figures, tables, and associated supplementary files and comprised (1) patient characteristics; (2) preoperative characteristics (eg, radiological findings); (3) intraoperative characteristics; and (4) postoperative outcomes (eg, functional outcomes, rate of return to work or sport, patient satisfaction, and complications). Collated data were summarized in tables using Excel (2013; Microsoft Corp). A qualitative assessment was performed to produce a narrative report. Treatment modalities were compared using subgroup analysis. Statistical analysis was conducted using OpenMeta-Analyst software (Brown University CEBM). The I^2 value was used to identify the heterogeneity between studies.

The primary outcome measure was the functional outcome of the patients as measured using the Mayo Elbow Performance Score (MEPS). MEPS values were provided as scores from 0 to 100 or as categories: poor (<60), fair (60-74), good (75-89), or excellent (90-100). The secondary outcomes were the visual analog scale (VAS; 0-10) for pain, as well as postoperative complications. The MEPS values across relevant studies were assessed using a random-effects model, with forest plots used to identify outcomes. Statistical significance was set at $P < .05$.

RESULTS

Included Studies

Overall, 20 studies met the inclusion criteria; 18 were level 4 case series, and the remaining 2 were level 3 retrospective cohort studies.^{††} Figure 1 shows the PRISMA²⁷ flow diagram of the study inclusion process.

Quality Assessment

The mean MINORS score for all 20 studies was 10.1 (Figure 2). Overall, all but 1 study³⁴ were considered high-quality studies with a low risk of bias.

Included Patients

A total of 646 patients ($n = 646$ elbows) with PLRI were included in 20 studies (Table 1). There were 367 elbows in men (56.8%) and 279 elbows in women (43.2%). The

^{††}References: 4, 6, 8, 9, 11, 12, 16-21, 23, 26, 29-34.

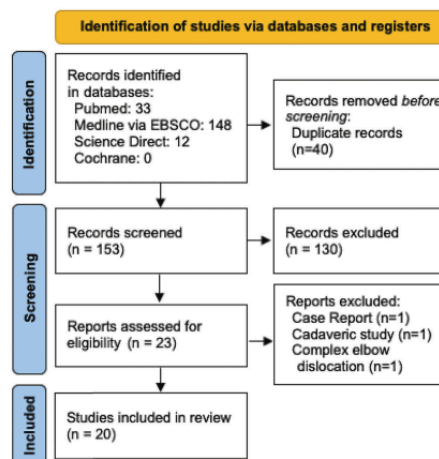


Figure 1. PRISMA flow diagram of the study inclusion process. PRISMA, Preferred Reporting Items for Systematic Reviews and Meta-Analyses.

dominant extremity was affected in 27.8% of patients (180/646). The mean waiting time was 18.1 months (range, 3 weeks-51.3 months); the mean follow-up was 4.5 years (range, 1-19 years).

Preoperative Characteristics

The preoperative characteristics are shown in Table 2. Most patients experienced pain at rest (475; 73.5%) and instability symptoms (532; 82.3%). The most common instability test performed was the pivot-shift test, which was found positive in 40.2% (260/646) of patients, followed by the varus stress test (104/646; 16%) and posterolateral drawer test (56/646; 8.6%). Other instability tests performed include the chair push-up test (29/646; 4.4%) and the tabletop relocation test. The preoperative range of motion (ROM) was only available in 338 patients (52.3%), with limited ROM found in 24 patients (3.7%). All patients underwent standard elbow radiographs; other imaging modalities such as magnetic resonance imaging and computed tomography were performed on 455 (70.4%) and 31 (4.7%) patients, respectively.

Intraoperative Characteristics

The intraoperative characteristics of the studies are summarized in Appendix Table A1. Overall, 68.8% (445/646) of patients underwent LUCL reconstruction and 31.1% (201/646) of patients underwent LUCL repair. For the reconstruction procedure, the most common graft used was the triceps tendon autograft (342/445; 76.8%) followed by palmaris

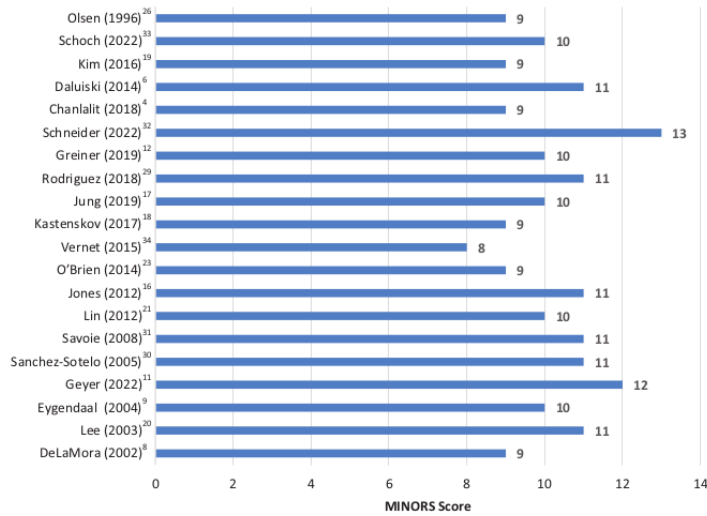


Figure 2. Distribution of MINORS Score in the included studies. MINORS, Methodologic Index for Non-randomized Studies.

TABLE 1
Characteristics of the Included Studies (N = 20)^a

Lead Author (Year)	Country	Study Type (LOE)	Elbows, n	Dominant Side Affected	Mean Age (Range), Years	Sex (M/F), n	Mean Waiting Time, Month ^b	Mean Follow-up, Month
Chanlalit (2018) ⁴	Thailand	Case series (4)	6	NR	46 (39-58)	1/5	32	24.2
Daluiski (2014) ⁶	US	Retrospective cohort (3)	34	NR	43.3 (NR)	21/13	12.3	38.1
DeLaMora (2002) ⁸	US	Case series (4)	5	NR	NR (22-61)	NR	NR	NR
Eygendaal (2004) ⁹	Netherlands	Case series (4)	12	5/12	35 (19-65)	8/4	36	23
Geyer (2022) ¹¹	Germany	Retrospective cohort (3)	31	NR	42.4 (18-65)	13/18	51.3	57.7
Greiner (2019) ¹²	Germany	Case series (4)	17	NR	38.3 (17-69)	14/3	NR	11
Jones (2012) ¹⁶	US	Case series (4)	8	NR	39.8 (17-57)	4/4	0.3	85.2
Jung (2019) ¹⁷	Republic of Korea	Case series (4)	21	NR	43.3 (21-59)	16/5	NR	27.4
Kastenskov (2017) ¹⁸	Denmark	Case series (4)	15	NR	34 (13-48)	3/12	37	228
Kim (2016) ¹⁹	Republic of Korea	Case series (4)	13	NR	43.2 (18-72)	11/2	NA	22.1
Lee (2003) ²⁰	Singapore	Case series (4)	10	6/10	34 (20-50)	6/4	10.4	24.1
Lin (2012) ²¹	Taiwan	Case series (4)	14	NR	31.6 (18-60)	14/8	2.3	49
O'Brien (2014) ²³	US	Case series (4)	13	5/13	26.6 (16-49)	11/2	2.2	29.9
Olsen (1996) ²⁶	Denmark	Case series (4)	18	11/18	30 (16-50)	5/13	35	44
Rodriguez (2018) ²⁹	US	Case series (4)	23	9/23	31.6 (19-46)	20/3	19.5	55.2
Sanchez-Sotelo (2005) ³⁰	US	Case series (4)	44	NR	39.2 (18-80)	24/13	NR	72
Savoie (2008) ³¹	US	Case series (4)	60	53/60	17.2 (16-22)	47/13	45	59.2
Schneider (2022) ³²	Germany	Case series (4)	72	52/72	46.9 (21-74)	33/39	NR	33.6
Schoch (2022) ³³	Germany	Case series (4)	178	NR	31.2 (17-48)	105/73	13	91
Vernet (2015) ³⁴	France	Case series (4)	18	NR	37.8 (20-63)	10/8	17	61.1

^aLOE, level of evidence; NR, not reported; Retrospective, retrospective; US, United States.

^bTime from injury to surgery.

tendon autograft (72/445; 16.1%). The other grafts were gracilis tendon autograft (13/445; 2.9%), Achilles tendon allograft (6/445; 1.3%), hamstring tendon autograft (4/445; 0.89%),

and flexor carpi radialis autograft (1/443; 0.22%). The most frequently used fixation type was transosseous fixation (197/646; 30.4%), followed by tenodesis screw (178/646; 27.5%),

TABLE 2
Preoperative Characteristics of the Included Studies^a

Study	Pain at Rest, n/Total	Instability Symptoms, n/Total	Instability Testing (n/Total)	Preoperative ROM arc, Deg	Imaging Evaluation	Imaging Findings (n/Total)
Chanlalit and Dilokhuttakarn ⁴ (2018)	NR	6/6	Varus stress (3/6); pivot-shift (5/6); posterolateral rotatory drawer (1/6); chair push-up (3/6)	NR	Radiograph, MRI	MRI: LCL lesion and concomitant pathologies (pathological plica and lateral epicondylitis) (5/6)
Daluisi et al ⁶ (2014)	NR	34/34	Varus stress (34/34); pivot-shift (34/34); posterolateral rotatory drawer (34/34)	NR	Radiograph	NR
DeLaMora and Hausman ⁸ (2002)	5/5	5/5	NR	127.5	NR	NR
Eyendaal ⁹ (2004)	12/12	12/12	Pivot-shift (NA)	147.9	Radiograph, MRI	MRI: Normal (9/12); cartilage lesion (3/12)
Geyer et al ¹¹ (2022)	NR	NR	NR	134.2	MRI	Partial LUCL lesion (17/31)
Greiner et al ¹² (2019)	17/17	17/17	Pivot-shift (17/17)	NR	Radiograph, MRI	MRI: LUCL injury (17/17)
Jones et al ¹⁶ (2012)	8/8	8/8	Pivot-shift (8/8)	NR	MRI	LUCL injury (8/8)
Jung et al ¹⁷ (2019)	21/21	21/21	Varus stress (21/21); posterolateral rotatory drawer (21/21)	133	MRI	Apparent joint space widening (21/21)
Kastenskov et al ¹⁸ (2017)	18/18	18/18	Pivot-shift (18/18)	NR	Radiograph	Posterolateral subluxation of the radial head (2/18)
Kim et al ¹⁹ (2016)	NR	13/13	Pivot-shift (13/13)	NR	CT, MRI	MRI and CT: tear of the lateral ulnar collateral ligament
Lee et al ²⁰ (2003)	5/10	9/10	Pivot-shift (5/10)	117.5	Radiograph	Radiohumeral subluxation (8/10)
Lin et al ²¹ (2012)	12/14	3/14	Pivot-shift (10/14)	114.3	Radiograph (stress and plain)	<ul style="list-style-type: none"> • Stress film: varus instability (9/14) • Plain film: Lateral epicondyle and anterior capsule avulsion fracture (7/14); medial and lateral epicondyle and anterior capsule avulsion fracture (2/14); lateral epicondyle avulsion fracture (1/14); none (4/14)
O'Brien et al ²³ (2014)	None	None	Pivot-shift (NA)	NR	MRI	RCL and LCL complex tear proximally off of the lateral epicondyle of the humerus (14/14)
Olsen et al ²⁶ (1996)	18/18	4/18	Pivot-shift (18/18); varus stress (7/18)	NR	Radiograph	Posterolateral subluxation of the radial head (2/18)
Rodriguez et al ²⁹ (2018)	17/23	18/23	Pivot-shift (18/23)	131.4	Radiograph, MRI	MRI: LUCL injury (17/23)
Sanchez-Sotelo et al ³⁰ (2005)	33/44	44/44	Pivot-shift (19/44); varus stress (39/44); chair push-up (26/44)	123.3	NR	NR
Savoie et al ³¹ (2008)	41/60	60/60	Pivot-shift (60/60)	NA	MRI	MUCL damage (42/60)
Schneider et al ³² (2022)	72	72	NR	NR	Radiograph, MRI	NR

(continued)

TABLE 2
(continued)

Study	Pain at Rest, n/Total	Instability Symptoms, n/Total	Instability Testing (n/Total)	Preoperative ROM arc, Deg	Imaging Evaluation	Imaging Findings (n/Total)
Schoch et al ³³ (2022)	178/178	178/178	Pivot-shift (NA), table-top relocation (178/178); chair push-up (178/178)	135.4	Radiograph, MRI	<ul style="list-style-type: none"> • Radiograph: drop sign • MRI: ligamentous injuries, cartilage lesions
Vernet et al ³⁴ (2015)	18/18	10/18	Pivot-shift (18/18)	NR	CT	Posterior subluxation of elbow (5/18); coronoid process fracture non-union (3/18)

^aCT, computed tomography; LCL, lateral collateral ligament; LUCL, lateral ulnar collateral ligament; MRI, magnetic resonance imaging; MUCL, medial ulnar collateral ligament; NA, not applicable; NR, not reported; RCL, radial collateral ligament; ROM, range of motion.

TABLE 3
Subgroup Analysis of LUCL Repair Versus Reconstruction Patients^a

Variable	LUCL Repair (n = 201)	LUCL Reconstruction (n = 445)
Mean age, y	41.11 ± 13.59 (9-80)	36.33 ± 10.03 (10-68)
Mean follow-up, mo	36.86 ± 21.19 (6-174)	72.05 ± 43.51 (9-265)
Mean waiting time, mo	6.32 ± 7.98 (0.13-24)	30.83 ± 22.32 (0.4-108)
Postoperative ROM arc, deg	135.02 ± 15.33 (80-151)	133.60 ± 8.84 (90-170)
Postoperative MEPS	91.58 ± 8.83 (60-100)	89.8 ± 8.31(45-100)
Return to activities rate, %	93.65 ± 4.84 (90-100)	96.28 ± 1.87 (80-100)
Satisfaction rate, %	94.40 ± 6.98 (88.6-100)	93.69 ± 4.74 (86-100)
Complication rate, %	14.9	8.3

^aData are presented as mean ± SD (range). LUCL, lateral ulnar collateral ligament; MEPS, Mayo Elbow Performance Score; ROM, range of motion.

suture anchor (138/646; 21.2%), and suture tape (72/646; 11.1%). Examination under anesthesia (EUA) was performed in 33.7% of patients (218/646). The types of EUA performed were the pivot-shift test (168/218; 77%), posterior drawer test (56/218; 25.6%), and varus stress test (21/218; 9.6%). Arthroscopic examination for instability was performed in 75 patients (11.6%), with a positive result in 45.3% (34/75) of patients.

Postoperative Characteristics

The postoperative outcomes according to the study are detailed in Appendix Table A2, and the results of the subgroup analysis of LUCL repair (n = 201 patients) versus reconstruction (n = 445 patients) are shown in Table 3. The most common functional outcome tool used was the MEPS, with 15 studies including postoperative MEPS values.^{††} A total of 44 patients (21.8%) in the repair group and 254 patients (57%) in the reconstruction group reported excellent MEPS outcomes, and 32 patients (15.9%) in the repair group and 124 patients (27.8%) in the

reconstruction group reported good outcomes. The remaining 5 patients reported fair outcomes, and 1 patient reported poor outcomes; all of these patients belonged to the reconstruction group. The mean MEPS was 91.58 ± 8.83 in the repair group and 89.8 ± 8.31 in the reconstruction group (Table 3). The VAS pain score was reported in 269 patients (41.6%), none of whom had a VAS score >3. The instability symptoms resolved in 592 patients (89.1%). Residual symptoms were observed in 28 patients (4.3%). The most common residual symptom exhibited was instability (18/28; 64.2%), followed by pain (11/28; 39.2%) and stiffness (5/28; 17.8%). Return to work or sport was reported in 8 studies,^{12,18,23,26,29,31,32,34} with times ranging from 7.7 to 52 weeks. Patient satisfaction was reported in 12 studies,⁸⁸ with 75 patients in the repair group and 212 patients in the reconstruction group satisfied with outcomes. The mean satisfaction rate was 94.40% ± 6.98% in the repair group and 93.69% ± 4.74% in the reconstruction group (Table 3).

Complications were observed in 54 patients (8.3%), with ulnar nerve event being the most common complication

^{††}References: 4, 6, 11, 12, 16-19, 21, 23, 26, 29, 32-34.

⁸⁸References: 11, 16, 18, 20, 21, 23, 26, 29, 30-32, 34.

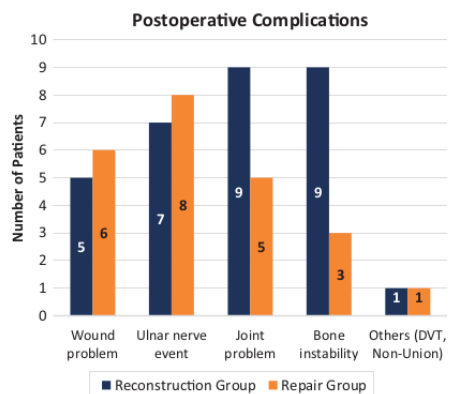


Figure 3. Postoperative complications after LUCL reconstruction versus LUCL repair. LUCL, lateral ulnar collateral ligament.

(2.3%). Postoperative complications were grouped into wound problems (1.8%)—including hematoma, wound infection, stitch abscess, pin-site irritation, and suture granuloma; ulnar nerve event (2.3%)—including persistent ulnar nerve symptoms, postoperative ulnar nerve injury, cubital tunnel syndrome, and ulnar nerve neuritis; joint problems (2.1%)—including contracture, heterotopic ossification, posttraumatic osteoarthritis, and arthrofibrosis; instability (1.8%)—including medial collateral ligament and flexor pronator tear, graft insufficiency, mild radiocapitellar opening, and reruptured ligament; and other (0.3%)—including deep vein thrombosis and nonunion. A comparison of complications between the reconstruction and repair groups is shown in Figure 3.

Functional Outcomes

Results of the meta-analysis of MEPS scores among 4 studies^{9,19,23,30} of LUCL repair and 11 studies¹¹ of LUCL reconstruction indicated that the mean postoperative MEPS was significantly higher in the repair group (91.5 [95% CI, 86.8-96.2]; $P = .016$; $I^2 = 99.3\%$) (Figure 4A) compared with the reconstruction group (89.8 [95% CI, 82.8-96.7]; $P < .001$; $I^2 = 100\%$) (Figure 4B).

DISCUSSION

This review and meta-analysis indicated that both LUCL repair and reconstruction surgery led to good to excellent patient-reported outcome scores. With regard to other outcome measures, LUCL reconstruction was shown to have

¹¹References: 4, 11, 16, 18, 21, 26, 29, 30, 32-34.

a superior rate of return to activity and a lower complication rate compared with LUCL repair, while LUCL repair had higher postoperative functional outcomes and ROM arc.

In the acute traumatic setting, LUCL repair is an option if the soft tissues are amenable; however, given the frequent difficulty in diagnosis of PLRI, repair is often not feasible as the soft tissues are irreparable. Therefore, reconstruction of the lateral collateral ligament complex is the recommended choice to restore elbow stability in patients, especially in those with subacute to chronic PLRI. As reported by Sanchez-Sotelo et al,³¹ reconstructions using a tendon graft provided better results than ligament repair, and the results did not appear to deteriorate with time, as satisfactory results were seen in 84% of patients after reconstruction.^{3,6,31}

With regard to functional outcomes, the postoperative ROM arc and MEPS values were slightly higher in patients who underwent LUCL repair versus reconstruction (ROM: 135.02° vs 133.60°; MEPS: 90.14 vs 89.04). These results may be due to the longer waiting times in the reconstruction group (30.82 months vs 6.30 months in the repair group), since a longer time from diagnosis of PLRI to surgery will result in significant pain, dysfunction, and degenerative changes to the elbow. Concrete diagnosis of PLRI is often delayed since it requires a careful history of elbow trauma in combination with a focused physical examination as well as associated imaging.³³ Among the included studies, Lin et al²² reported a mean time between injury and index surgery of 45 months, and Chanlalit and Dilokhuttakarn⁴ reported that patients with atraumatic PLRI showed inferior results compared with patients with traumatic PLRI due to their longer waiting time.

Our findings are similar to a study by Fares et al,¹⁰ which showed that despite the delayed diagnosis, surgical outcomes after LUCL reconstruction are generally excellent, with 90% of patients reporting a mean MEPS of 89.7 at a long-term follow-up. The rate of return to activities was marginally higher in the LUCL reconstruction group compared with the repair group. Vitale et al³⁵ showed that LUCL reconstruction was effective in returning athletes to sports, with a rate of return of approximately 80%. This finding was also supported by Hechtman et al,¹³ who reported that out of 34 athletes, 29 athletes (85%) had an excellent result, defined as the ability to return to play at or above the preinjury level. Conway et al⁵ also reported that only 50% of patients undergoing a direct repair returned to their previous level of sport compared with 68% of those undergoing a reconstruction. Even worse outcomes were seen in Major League Baseball players in the United States who underwent primary repair, with only 2 of 7 players being able to return to sports.¹³

We cannot conclude from the available studies whether one procedure is superior to another because of the limited number of patients and the heterogeneity of the patient characteristics and mechanisms of injury. LUCL repair may be a viable surgical option in young athletes with acute injuries, as it has excellent outcomes and allows an earlier return to play compared to LUCL reconstruction.²⁹

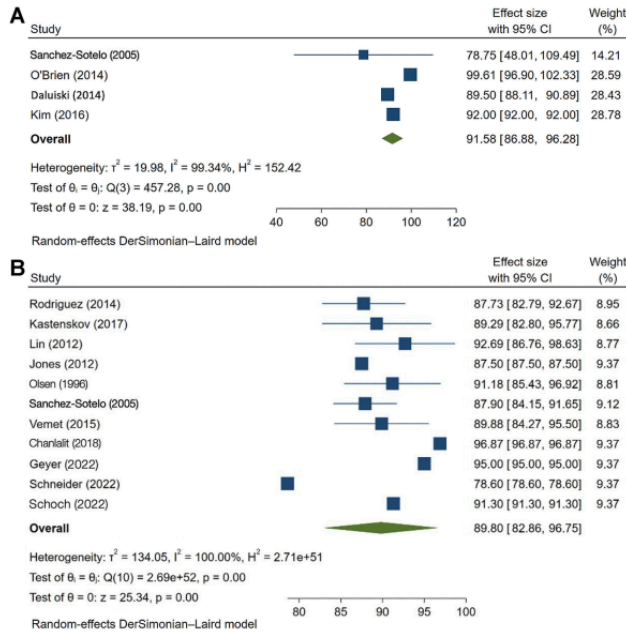


Figure 4. The MEPS of the (A) LUCL repair group and (B) LUCL reconstruction group. LUCL, lateral ulnar collateral ligament; MEMPS, Mayo Elbow Performance Score.

Savoie et al.³¹ included in this review, showed that the results of primary LUCL repair in patients with acute injury were excellent, with 93% (56/60) of patients returning to sporting activities within 6 months. However, LUCL reconstruction may be more beneficial in patients with subacute, chronic PLRI or in older patients who may have degenerative tissue.^{2,17}

Limitations

The main strength of this study is that our meta-analysis compares the surgical outcome of LUCL reconstruction versus repair for PLRI, comprising 20 included studies from 4 major databases after a comprehensive literature search. However, this study does have limitations. The analysis demonstrated a lower quality of evidence. However, the heterogeneity of patient characteristics and various mechanisms of injury limited the comparison of the superiority of each technique. Also, many studies did not discuss postoperative rehabilitation, and they had incomplete data as it related to return to preoperative levels of activity. Future studies into the surgical treatment of PLRI with a higher level of evidence, similar patient characteristics, and chronicity of the condition are needed.

CONCLUSION

This study demonstrated that LUCL reconstruction showed a superior rate of return to activity and a lower complication rate compared with LUCL repair. The patient population and the time from injury to the procedure also contributed to the outcome among the patients. LUCL reconstruction also had a lower complication rate but the ROM among these groups was similar.

REFERENCES

1. Arem Lim KS, Mile Ini EN, Amien Orestier DF, et al. Methodological Index for Non-randomized Studies (MINORS): development and validation of a new instrument. *ANZ J Surg.* 2003;73:712-716.
2. Badhrinarayanan S, Desai A, Watson JJ, White CHR, Phadnis J. Indications, outcomes, and complications of lateral ulnar collateral ligament reconstruction of the elbow for chronic posterolateral rotatory instability: a systematic review. *Am J Sports Med.* 2021;49(3):830-837.
3. Camp CL, Smith J, O'Driscoll SW. Posterolateral rotatory instability of the elbow: part I. Mechanism of injury and the posterolateral rotatory drawer test. *Arthrosc Tech.* 2017;6(2):e401-e405.
4. Charlilil C, Dilokhuttakam T. Lateral collateral ligament reconstruction in atraumatic posterolateral rotatory instability. *JSES Open Access.* 2018;2(2):121-125.

5. Conway JE, Jobe FW, Glousman RE, Pink M. Medial instability of the elbow in throwing athletes. Treatment by repair or reconstruction of the ulnar collateral ligament. *J Bone Joint Surg Am.* 1992;74(1):67-83.
6. Daluiski A, Schrupf MA, Schreiber JJ, Nguyen JT, Hotchkiss RN. Direct repair for managing acute and chronic lateral ulnar collateral ligament disruptions. *J Hand Surg Am.* 2014;39(6):1125-1129.
7. Dargel J, Küpper F, Wegmann K, Oppermann J, Eysel P, Müller LP. Graft diameter does not influence primary stability of ulnar collateral ligament reconstruction of the elbow. *J Orthop Sci.* 2015;20(2):307-313.
8. DeLaMora SN, Hausman M. Lateral ulnar collateral ligament reconstruction using the lateral triceps fascia. *Orthopedics.* 2002;25(9):909-912.
9. Eygendaal D. Ligamentous reconstruction around the elbow using triceps tendon. *Acta Orthop Scand.* 2004;75(5):370-373.
10. Fares A, Kusnezov N, Dunn JC. Lateral ulnar collateral ligament reconstruction for posterolateral rotatory instability of the elbow: a systematic review. *HAND.* 2022;17(2):373-379.
11. Geyer S, Heine C, Winkler PW, et al. LUCL reconstruction of the elbow: clinical midterm results based on the underlying pathogenesis. *Arch Orthop Trauma Surg.* 2022;142(8):1809-1816.
12. Greiner S, Koch M, Kerschbaum M, Bhide PP. Repair and augmentation of the lateral collateral ligament complex using internal bracing in dislocations and fracture dislocations of the elbow restores stability and allows early rehabilitation. *Knee Surg Sports Traumatol Arthrosc.* 2019;27(10):3269-3275.
13. Hechtman KS, Zvijac JE, Wells ME, Botto-van Bemden A. Long-term results of ulnar collateral ligament reconstruction in throwing athletes based on a hybrid technique. *Am J Sports Med.* 2011;39(2):342-347.
14. Howick J, Chalmers I, Lind J, et al. Oxford Centre for Evidence-Based Medicine 2011 Levels of Evidence.
15. Jones CM, Beason DP, Dugas JR. Ulnar collateral ligament reconstruction versus repair with internal bracing: comparison of cyclic fatigue mechanics. *Orthop J Sports Med.* 2018;6(2):232596711875599.
16. Jones KJ, Dodson CC, Osbahr DC, et al. The docking technique for lateral ulnar collateral ligament reconstruction: surgical technique and clinical outcomes. *J Shoulder Elbow Surg.* 2012;21(3):389-395.
17. Jung HS, Lee JS, Rhyou IH, Lee HW, Park MJ. Dual reconstruction of lateral collateral ligament is safe and effective in treating posterolateral rotatory instability of the elbow. *Knee Surg Sports Traumatol Arthrosc.* 2019;27(10):3284-3290.
18. Kastenskov C, Rasmussen JV, Ovesen J, Olsen BS. Long-term clinical results in patients treated for recurrent posterolateral elbow joint instability using an ipsilateral triceps tendon graft. *J Shoulder Elbow Surg.* 2017;26(6):1052-1057.
19. Kim JW, Yi Y, Kim TK, et al. Arthroscopic lateral collateral ligament repair. *J Bone Joint Surg Am.* 2016;98(15):1268-1276.
20. Lee BPH, Teo LHY. Surgical reconstruction for posterolateral rotatory instability of the elbow. *J Shoulder Elbow Surg.* 2003;12(5):476-479.
21. Lin KY, Shen PH, Lee CH, Pan RY, Lin LC, Shen HC. Functional outcomes of surgical reconstruction for posterolateral rotatory instability of the elbow. *Injury.* 2012;43(10):1657-1661.
22. Marinelli A, Graves BR, Bain GI, Pederzini L. Treatment of elbow instability: state of the art. *J ISAKOS.* 2021;6(2):102-115.
23. O'Brien MJ, Lee Murphy R, Savoie FH. A preliminary report of acute and subacute arthroscopic repair of the radial ulnohumeral ligament after elbow dislocation in the high-demand patient. *Arthroscopy.* 2014;30(6):679-687.
24. O'Brien MJ, Savoie FH III. Arthroscopic and open management of posterolateral rotatory instability of the elbow. *Sports Med Arthrosc Rev.* 2014;22(3):194-200.
25. O'Driscoll SW. Elbow instability. *Hand Clin.* 1994;10(3):405-415.
26. Olsen BS, Vaesel MT, Søjbjerg JO, Helmgig P, Sneppen O. Lateral collateral ligament of the elbow joint: anatomy and kinematics. *J Shoulder Elbow Surg.* 1996;5(2 Pt 1):103-112.
27. Page MJ, McKenzie JE, Bossuyt PM, et al. The PRISMA 2020 statement: an updated guideline for reporting systematic reviews. *Syst Rev.* 2021;10(1):1-11.
28. Redler LH, Degen RM, McDonald LS, Altchek DW, Dines JS. Elbow ulnar collateral ligament injuries in athletes: can we improve our outcomes? *World J Orthop.* 2016;7(4):229.
29. Rodriguez MJ, Kusnezov NA, Dunn JC, Waterman BR, Kilcoyne KG. Functional outcomes following lateral ulnar collateral ligament reconstruction for symptomatic posterolateral rotatory instability of the elbow in an athletic population. *J Shoulder Elbow Surg.* 2018;27(1):112-117.
30. Sanchez-Sotelo J, Morrey BF, O'Driscoll SW. Ligamentous repair and reconstruction for posterolateral rotatory instability of the elbow. *J Bone Joint Surg Br.* 2005;87(1):54-61.
31. Savoie FH III, Trenhaile SW, Roberts J, Field LD, Ramsey JR. Primary repair of ulnar collateral ligament injuries of the elbow in young athletes. *Am J Sports Med.* 2008;36(6):1066-1072.
32. Schneider MM, Müller K, Hollinger B, et al. Lateral ulnar collateral ligament reconstruction for posterolateral rotatory instability after failed common extensor origin release: outcomes at minimum 2-year follow-up. *Orthop J Sports Med.* 2022;10(2):23259671211069340.
33. Schoch C, Dittnich M, Seilern und Aspang J, Geyer M, Geyer S. Autologous triceps tendon graft for LUCL reconstruction of the elbow: clinical outcome after 7.5 years. *Eur J Orthop Surg Traumatol.* 2022;32(6):1111-1118.
34. Vemet E, Bacle G, Marteau E, Favard L, Laulan J. Lateral elbow ligamentoplasty by autologous tendon graft in posterolateral rotatory instability: results in 18 cases at a mean 5 years' follow-up. *Orthop Traumatol Surg Res.* 2015;101(4).
35. Vitale MA, Ahmad CS. The outcome of elbow ulnar collateral ligament reconstruction in overhead athletes. *Am J Sports Med.* 2008;36(6):1193-1205.

APPENDIX

TABLE A1
Intraoperative Characteristics of the Included Studies^a

Study	Procedure	Intraoperative Findings	Graft Type	Fixation Type	Additional Procedures
Chanlalit and Dilokhuttakarn ⁴ (2018)	LUCL repair	Lateral epicondylitis (4/6); pathological plica (2/6)	—	Suture Anchor	NR
Daluiski et al ⁶ (2014)	Arthroscopic LUCL repair (32); LUCL recon (2)	Humeral detachment of the lateral collateral ligaments (34/34)	Palmaris tendon autograft (2/34)	Suture anchor	—
DeLaMora and Hausman ⁸ (2002)	LUCL recon	NR	Triceps tendon autograft (5/5)	Transosseous	—
Eyegendaal ⁹ (2004)	LUCL recon	NR	Triceps tendon autograft	Bioabsorbable 5.5-mm interference screws	—
Geyer et al ¹¹ (2022)	LUCL recon	Arthroscopic instability testing: PLRI finding (31/31)	Triceps tendon autograft	Transosseous	—
Greiner et al ¹² (2019)	LUCL repair with internal bracing augmentation	<ul style="list-style-type: none"> • EUA: posterior drawer test (17/17) • Drive-through sign (17/17) 	—	Suture anchor	MCL reattachment (2/17); radial head resection (3/17); coronoid process reconstruction (1/17); radial head arthroplasty (1/17)
Jones et al ¹⁶ (2012) ¹⁶	LUCL recon (docking)	<ul style="list-style-type: none"> • EUA: pivot-shift test (8/8) • Drive-through sign (8/8) 	Palmaris tendon autograft (8/8)	Transosseous	—
Jung et al ¹⁷ (2019)	Dual RCL and LUCL recon	EUA: Varus stress test, posterolateral drawer test	Triceps tendon autograft	Transosseous	ECRB tendon debridement
Kastenskov et al ¹⁸ (2017)	LUCL recon	Posterior displacement of radial head (18/18)	Triceps tendon autograft	Suture anchor	—
Kim et al ¹⁹ (2016)	Arthroscopic LUCL repair	NR	—	Suture anchor (13/13)	Coronoid fracture fixation (8/13); radial head excision (5/13)
Lee et al ²⁰ (2003)	LUCL recon (4/10); LUCL repair (6/10)	EUA: pivot-shift test (10/10)	Palmaris tendon autograft (5/10); split semitendinosus graft (1/10)	Transosseous	—
Lin et al ²¹ (2012)	LUCL recon	<ul style="list-style-type: none"> • EUA: pivot-shift test (14/14) • Fluoroscopic stress view (14/14) 	Palmaris tendon autograft (8/14); gracilis autograft (6/14)	Transosseous	—
O'Brien and Savoie ²³ (2014)	Arthroscopic LUCL repair	<ul style="list-style-type: none"> • EUA: pivot-shift test • Drive-through sign • Incompetence annular ligament 	—	Suture anchor	—
Olsen et al ²⁶ (1996)	LUCL recon	EUA: posterolateral drawer test (18/18)	Triceps tendon autograft (18/18)	Suture anchor	—
Rodriguez et al ²⁹ (2018)	LUCL recon (docking)	NA	Palmaris tendon autograft (12/23); hamstring tendon autograft (1/23); gracilis autograft (4/23); flexor carpi radialis autograft (1/23); NR (5/23)	NR	—

(continued)

TABLE A1
(continued)

Study	Procedure	Intraoperative Findings	Graft Type	Fixation Type	Additional Procedures
Sanchez-Sotelo et al ³⁰ (2005)	Open LUCL repair (12/44); LUCL recon (yoke) (32/44)	<ul style="list-style-type: none"> EUA: pivot-shift test (41/44) Arthroscopic evaluation: lateral joint opening (3/44) Ligamentous lesion: avulsion (8/44), laxity (28/44) 	Repair with ligament imbrication (7/12); reconstruction with palmaris tendon autograft (20/32); triceps tendon autograft (4/32); semitendinosus autograft (2/32); Achilles tendon autograft (6/32)	Transosseous	Loose body removal (5/9); capsulectomy (2/9); radial head replacement (1/9); coronoid process reconstruction (1/9)
Savoie et al ³¹ (2008)	Arthroscopic LUCL repair (24/60); open LUCL repair (27/60); LUCL recon (3/60)	EUA: pivot-shift test (54/60)	Arthroscopic repair with suture anchor (24/60); open repair with interference screw (27/60); reconstruction with gracilis allograft (3/60)	Transosseous	Lateral epicondylitis release (16/60); open extensor mass avulsion repair (6/60); open posterior interosseous nerve release (4/60); suture repair of the lateral collateral ligamentous complex (34/60)
Schneider et al ³² (2022)	LUCL recon	NR	Triceps tendon autograft	Suture tape	NR
Schoch et al ³³ (2022)	LUCL recon	NR	Ipsilateral triceps tendon autograft	Tenodesis screw	—
Vernet et al ³⁴ (2015)	LUCL recon	<ul style="list-style-type: none"> EUA: pivot-shift test (18/18) Irreparable LUCL and ulnar bundle (18/18) 	Palmaris tendon autograft (17/18); triceps tendon autograft (1/18)	Suture anchor	—

^aECRB, extensor carpi radialis brevis; EUA, examination under anesthesia; LUCL, lateral ulnar collateral ligament; MCL, medial collateral ligament; NR, not reported; PLRI, posterolateral rotatory instability of the elbow; RCL; radial collateral ligament; recon, reconstruction.

TABLE A2
Postoperative outcomes of the Included Studies^a

Study	Quantitative Assessment		Quantitative Assessment				
	Outcome Measures	Postop ROM arc, Deg	Resolution of Instability Symptom, n/Total	Recurrence/Residual Symptoms (n/Total)	Return to Work/Sport (Time)	Patient Satisfaction, n/Total (%)	Complications (n)
Chanlalit Chanlalit and Dilokhuttakarn ⁴ (2018)	<ul style="list-style-type: none"> MEPS: 97.5 DASH: 7.6 	136.8	8/8	—	NR	NR	None
Daluisi et al ⁶ (2014)	MEPS: 89.5	135	34/34	—	NR	NR	Postoperative stiffness (1); wound breakdown (1); postoperative arthritis (1); ulnar nerve neuritis (1)
DeLaMora and Hausman ⁸ (2002)	NR	125	5/5	—	NR	NR	None
Eyegendaal ⁹ (2004)	Broberg and Morrey score: excellent (6/12), good-excellent (5/12), good (1/12)	150.4	11/12	Persistent instability (1/12)	NR	NR	None
Geyer et al ¹¹ (2022)	<ul style="list-style-type: none"> MEPS: 95 PREE: 15.8 VAS pain: 1.4 DASH: 11.8 	137.9	29/31	—	NR	28/31 (90.4)	Wound infection (1); persistent ulnar nerve symptoms (2); elbow stiffness (1)
Greiner et al ¹² (2019)	<ul style="list-style-type: none"> MEPS: 92.4 DASH: 27.5 OES: 39.1 	130	17/17	—	17/17 (52 wk)	NR	Heterotopic ossification (1)

(continued)

TABLE A2
(continued)

Study	Quantitative Assessment		Quantitative Assessment				
	Outcome Measures	Postop ROM arc, Deg	Resolution of Instability Symptom, n/Total	Recurrence/Residual Symptoms (n/Total)	Return to Work/Sport (Time)	Patient Satisfaction, n/Total (%)	Complications (n)
Jones et al ¹⁶ (2012)	<ul style="list-style-type: none"> • MEPS: 87.5 • Nestor grading system: excellent (4/8), good (4/8) 	Full ROM	6/8	Occasional instability (2/8)	NR	8/8	None
Jung et al ¹⁷ (2019)	<ul style="list-style-type: none"> • MEPS: 85 • QuickDASH: 11.4 • NRS: 2 	130	19/21	Mild instability (2/21)	NR	NR	Stitch abscess (1)
Kastenskov et al ¹⁸ (2017)	<ul style="list-style-type: none"> • MEPS: 89 • VAS pain: 0 during rest, 3 during activity • OES: 45 • MEPS: 92 • Nestor grading system: excellent (11), good (2) 	136.4	18/18	Mild pain during activity (6/18)	18/18	16/18	Posttraumatic osteoarthritis (5)
Kim et al ¹⁹ (2016)	<ul style="list-style-type: none"> • MEPS: 89 • VAS pain: 0 during rest, 3 during activity • OES: 45 • MEPS: 92 • Nestor grading system: excellent (11), good (2) 	141	13/13	—	NR	NR	Pin site irritation (1); delayed union (1); mild widening of the radiocapitellar joint space (1)
Lee et al ²⁰ (2003)	Nestor grading system: excellent 3/10, good 5/10, fair 2/10	128.5	10/10	Stiffness (2/10)	NR	10/10 (100)	Postoperative hematoma (1)
Lin et al ²¹ (2012)	<ul style="list-style-type: none"> • MEPS: 93.2 • Nestor grading system: excellent (10/14), good (3/14), fair (1/14) 	122.1	13/14	Persistent instability (1/14)	NR	13/14 (93)	MCL tear (1)
O'Brien and Savoie ²³ (2014)	MEPS: 100	128.1	13/13	—	13/13 (7.7 wk)	13/13	Heterotopic ossification (1)
Olsen et al ²⁶ (1996)	<ul style="list-style-type: none"> • MEPS: 92 • Modified Constant score: 89 	136	18/18	Moderate pain (5); loss of extension (2); loss of flexion (1)	15/18	15/18	Ulnar nerve paralysis (1); deficient triceps tendon graft (1)
Rodriguez et al ²⁹ (2018)	<ul style="list-style-type: none"> • MEPS: excellent (9/23), good (10/23), fair (3/23), poor (1/23)^a • VAS pain: 1.34 	121	23/23	—	19/23 (19.5 wk)	19/23	Wound infection (1); cubital tunnel syndrome (3); contracture (1)
Sanchez-Sotelo et al ³⁰ (2005)	Nestor grading system: excellent (18/37), good (10/37), fair (9/37)	134.8	31/37	Pain and recurrence of instability (6/37)	NR	38/44 (86)	Wound infection (2); heterotopic ossification (1); ulnar nerve compression (2); deep vein thrombosis (1)
Savoie et al ³¹ (2008)	Andrews-Carson score: excellent (53/60), good (3/60), fair (3/60), poor (1/60)	NR	NR	NR	58/60 (24 wk)	51/60 (85)	Arthrofibrosis (1); ulnar nerve injury (6); wound infection (2); flexor pronator tear (2)
Schneider et al ³² (2022)	<ul style="list-style-type: none"> • MEPS: 78.6 • SEV: 78.9 • PRTEE: 21.5 • DASH: 20.4 	NA	72/72	—	72/72 (18.9 wk)	67/72	Heterotopic ossification (1); insufficient triceps tendon graft (5); suture granuloma (1)
Schoch et al ³³ (2022)	<ul style="list-style-type: none"> • MEPS: 91.3 • VAS pain: 1.8 • OES: 46.5 	131.3	178/178	—	NR	NR	Ligament rerupture (2)
Vernet et al ³⁴ (2015)	<ul style="list-style-type: none"> • VAS pain: 2.6 • MEPS: excellent (11/18), good (6/18), fair (1/19)^b 	126.7	18/18	—	18/18 (14 wk)	18/18	None

^aDASH, Disabilities of the Arm, Shoulder and Hand; MEPS, Mayo Elbow Performance Index; NR, not reported; NRS, Numeric Rating Scale; OES, Oxford Elbow Score; PREE, Patient-Rated Elbow Evaluation; preop, preoperative; ROM, range of motion; SEV, Subjective Elbow Value; VAS, visual analog scale.

^bMEPS scores were categorized as poor (<60), fair (60-74), good (75-89), or excellent (90-100).

Surgical Outcomes of Lateral Ulnar Collateral Ligament Reconstruction Versus Repair for Posterolateral Rotatory Instability of the Elbow: A Systematic Review and Meta-analysis

ORIGINALITY REPORT

18%

SIMILARITY INDEX

14%

INTERNET SOURCES

16%

PUBLICATIONS

7%

STUDENT PAPERS

MATCH ALL SOURCES (ONLY SELECTED SOURCE PRINTED)

1%

★ "ESSKA Instructional Course Lecture Book",
Springer Nature, 2016

Publication

Exclude quotes On

Exclude matches Off

Exclude bibliography On

Surgical Outcomes of Lateral Ulnar Collateral Ligament Reconstruction Versus Repair for Posterolateral Rotatory Instability of the Elbow: A Systematic Review and Meta-analysis

GRADEMARK REPORT

FINAL GRADE

GENERAL COMMENTS

/100

PAGE 1

PAGE 2

PAGE 3

PAGE 4

PAGE 5

PAGE 6

PAGE 7

PAGE 8

PAGE 9

PAGE 10

PAGE 11

PAGE 12