

Search... « 1 2 »

Page 1 of 2 | Total Records : 17

Publications	Citation
Strawberry Extract's Effects on Enterococcus faecalis and Porphyromonas gingivalis Biofilms in vitro El Armelia Sari Widyarman, Stephanie Brigitta Widjaja SCIENTIFIC DENTAL JOURNAL 1 (1), 1-5	15

Penerbit:
 Faculty of Dentistry, Trisakti University
[Website](#) | [Editor URL](#)

Address:
 Jl. Kyai Tapa No.260, Grogol, Jakarta Barat 11440, Indonesia
 Jakarta

Email:
 armeliasari@trisakti.ac.id

Phone:
 0811929379

Last Updated :
 2020-12-01

Consumption of Yogurt Containing Probiotic Bifidobacterium Lactis Reduces Streptococcus mutans in Orthodontic Patients TP Armelia Sari Widyarman, Shirley Trisna Yunita SCIENTIFIC DENTAL JOURNAL 2 (1), 19-25	10
Comparing the Effectivities of Chitosan Citrate and Chitosan Acetate in Eradicating Enterococcus faecalis Biofilm ASW Uppalavanna Witedja, Tien Suwartini, Anastasia E Prahasti SCIENTIFIC DENTAL JOURNAL 2 (1), 1-7	4
Optimization of Emergence Profile of Implant Prosthesis: A Literature Review KB Minoru Sanda, Daisuke Sato SCIENTIFIC DENTAL JOURNAL 2 (1), 31-37	2
Level of Salivary Uric Acid in Gingivitis and Periodontitis Patients SV Muhammad Ihsan Rizal SCIENTIFIC DENTAL JOURNAL 1 (1), 7-10	2
Microbiomics of Oral Biofilms: Driving The Future of Dental Research TS Chaminda Jayampath Seneviratne SCIENTIFIC DENTAL JOURNAL 1 (1), 25-30	1
The Addition of Pharmacological Treatment to Physiotherapy in Pain Reduction of TMD-myalgia Patients HP Carolina Marpaung SCIENTIFIC DENTAL JOURNAL 2 (1), 25-30	0
The Efficacy of Fish Scales as Bone Graft Alternative Materials IN Abdul Gani Soulissa SCIENTIFIC DENTAL JOURNAL 2 (1), 9-17	0
The Efficacy of Fish Scales as Bone Graft Alternative Materials IN Abdul Gani Soulissa SCIENTIFIC DENTAL JOURNAL 2 (1), 9-17	0
The Importance of The Dentist – Patient Relationship in Oral Cancer Treatment RA Indrayadi Gunardi SCIENTIFIC DENTAL JOURNAL 1 (1), 17-23	0
Pigmented Oral Lichen Planus: A Case Report TGK Firstine Kelsi Hartanto SCIENTIFIC DENTAL JOURNAL 1 (1), 11-16	0

Level of Salivary Uric Acid in Gingivitis and Periodontitis Patients SV Muhammad Ihsan Rizal SCIENTIFIC DENTAL JOURNAL 1 (1), 7-10	0
Knowledge and attitude differences among students at dental-education institutions as a result of interprofessional education AB Marta Juslily, Tri Erri Astoeti SCIENTIFIC DENTAL JOURNAL 4 (2), 64-71	0
Correlation between body mass index with anterior crowding and enamel hypoplasia of sundanese children in Bandung YY Linda Sari Sembiring, Loes D Sjahruddin SCIENTIFIC DENTAL JOURNAL 4 (2), 59-63	0
The effect of 10% forest honey rinsing on dental plaque score for children aged 9-12 years FM Ulfia Yasmin, Sulistiawati, Hema Awalia, Budi Asri SCIENTIFIC DENTAL JOURNAL 4 (2), 54-58	0
The effectiveness of mixtures of tetracycline, acid and detergent, and mixtures of chlorhexidine and ethylenediaminetetraacetic acid in preventing the growth of Enterococcus ... BOR Tien Suwartini, Eljira Anggraini, Meiny Faudah Amin SCIENTIFIC DENTAL JOURNAL 4 (2), 49-53	0
The effect of repeated preheating on diametral tensile strength of composite resin with different fillers RT Ellen Winarta, Tien Suwartini, Anastasia Elsa Prahasti SCIENTIFIC DENTAL JOURNAL 4 (2), 44-48	0
Dental negligence: It is time to overcome it RC Shail Kumari, Sunil Kumar Mishra SCIENTIFIC DENTAL JOURNAL 4 (2), 39-43	0



ISSN : 2580 - 6504 (print)
ISSN : 2541 - 321X (online)



SDJ

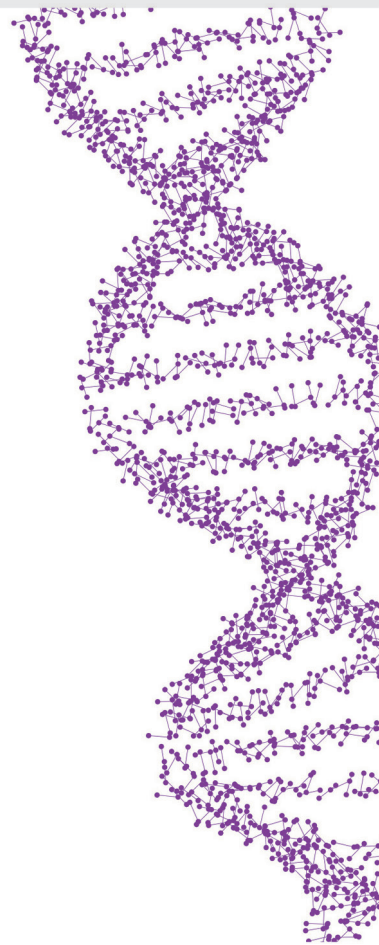SCIENTIFIC
DENTAL JOURNAL

Volume 2

Mei 2018

Number 2

DOI: <http://dx.doi.org/10.26912/sdj.v2i1>





About ▾

Articles ▾

Authors ▾

Search ▾

Subscribe

Contact Us

Reader Login ▾

Editorial Board

About the journal

Editor-in-Chief:

Dr. Armelia Sari Widyarman

Department of Microbiology, Faculty of Dentistry, Trisakti University, Jakarta, Indonesia
armeliasari@trisakti.ac.id
sdj@trisakti.ac.id

Executive Editor:

Dr. Rosalina Tjandrawinata,

Department of Dental Material, Faculty of Dentistry, Trisakti University, Jakarta, Indonesia
rosatjandrawinata@gmail.com

Editorial Board:

Dr. Carolina Marpaung

Department of Prosthodontics, Faculty of Dentistry, Trisakti University, Jakarta, Indonesia
carolina@trisakti.ac.id

POPULAR ARTICLES

JOIN AS REVIEWER

GET EMAIL ALERTS

RECOMMEND

Dr. Chaminda Jayampath Seneviratne,
Faculty of Dentistry, National University of Singapore, Singapore
jaya@nus.edu.sg

Prof. SG Damlee
Pediatric and Preventive Dentistry, Maharishi Markandeshwar University, India
sgdamlee@gmail.com

Dr. Risa Chaisuparat
Associate Professor, Department of Oral Pathology,
Faculty of Dentistry, Chulalongkorn University, Thailand
mink_risa@yahoo.com

Prof. Sittichai Koontongkaew
Department of Oral Biology, Faculty of Dentistry, Thammasat University, Thailand
koontongkaew@gmail.com

Prof. Rahmi Amtha
Department of Oral Medicine, Faculty of Dentistry, Trisakti University, Indonesia
rahmi.amtha@gmail.com

Dr. M. Orliando Roeslan
Department of Histology, Faculty of Dentistry, Trisakti University, Indonesia
orliandoichol@gmail.com

Dr. Muhammad Ihsan Rizal
Department of Biochemistry and Molecular Biology, Division of Oral Biology, Faculty of Dentistry, Trisakti University, Indonesia
ihsan.rizal@gmail.com

Administration:

Dr. Enrita Dian Rahmadini
Department of Pedodontics, Faculty of Dentistry, Trisakti University, Indonesia
enritadian@gmail.com

Mega Cahyati
Faculty of Dentistry, Trisakti University, Indonesia
mega.cahyati@gmail.com

Mario Richi
MiCORE Laboratory, Faculty of Dentistry, Trisakti University, Indonesia
mario.richi1995@gmail.com

Moh Shidqon
Faculty of Economics and Business, Trisakti University, Indonesia
ajidshidqon@gmail.com

ISSN : 2580 - 6504 (print)
ISSN : 2541 - 321X (online)

DOAJ DIRECTORY OF
OPEN ACCESS
JOURNALS

SCIENTIFIC DENTAL JOURNAL

CONTENT

Enzymatic Activity of Bromelain Isolated Pineapple (<i>Ananas comosus</i>) Hump and Its Antibacterial Effect on <i>Enterococcus faecalis</i>	<i>Dewi Liliany, Armelia Sari Widyarman, Erni Erfan, Janti Sudiono, Melanie S. Djamil</i>	/ 39 - 50
Chewing Gum, Acetaminophen, and Green Tea Effect in Reducing Pain After Orthodontic Appliance Placement	<i>Elvina, Joko Kusnoto, Himawan Halim, Boedi Oetomo Roeslan</i>	/ 51 - 57
Analyzing the Width of the Maxillary Sinus from Private Practice in Bogor, Indonesia	<i>Steven A. Tjang, Rosalina Tjandrawinata, Muhammad Novo Perwira Lubis</i>	/ 59 - 66
Isolation and Identification of Indonesian <i>Lactobacillus reuteri</i> Strain from the Saliva of Young Adults	<i>Armelia Sari Widyarman, Stella Pranoto, Citra Fragrantia Theodorea, Endang Winiati Bachtiar, Boy Muchlis Bachtiar</i>	/ 67 - 75
A Case Report of Angiosarcoma of Maxillary Gingiva: Histopathology Aspects	<i>Firstine Kelsi Hartanto, Shin Hin Lau</i>	/ 77 - 83



Analyzing the Width of the Maxillary Sinus from Private Practice in Bogor, Indonesia

Steven A. Tjang¹, Rosalina Tjandrawinata², Muhammad Novo Perwira Lubis³

¹ Private Practice, Siliwangi 146, Bogor, West Java – Indonesia

² Department of Dental Material, Faculty of Dentistry, Trisakti University – Indonesia

³ Department of Radiology, Faculty of Dentistry, Trisakti University – Indonesia

Corresponding Author: Rosalina Tjandrawinata, Faculty of Dentistry, Trisakti University – Indonesia.

Email: rosalinatjandrawinata@gmail.com

Received date: January 30, 2018. **Accepted date:** April 21, 2018. **Published date:** May 29, 2018.

Copyright: ©2018 Tjang SA, Tjandrawinata R, Lubis MNP. This is an open access article distributed under the terms of the Creative Commons Attribution License, which permits unrestricted use, distribution, and reproduction in any medium provided the original author and sources are credited.

DOI: <http://dx.doi.org/10.26912/sdj.v2i2.2504>

ABSTRACT

Background: X-ray examinations are still a frequent diagnostic tool used by doctors in Indonesia. However, there is an apparent lack of descriptive data regarding the size and location of the maxillary sinus in Indonesian people. **Objective:** The aim of this study is to provide descriptive data on the size and location of the maxillary sinus among patients in the city of Bogor, West Java, Indonesia. **Methods:** Sixty eligible subjects aged 17 to 70 years old were randomized into six groups: male and female patients between 17 and 25 years old; male and female patients between 26 and 45 years old; and male and female patients aged 46 or older. Radiographic pictures were taken using the *X-mind Novus Digital Panoramic X-ray unit* and data were measured using the software *Digora for Windows*. **Results:** Using an analysis of variance, we found that men have significantly larger maxillary sinus dimensions than women (79.05 mm compared to 66.33 mm). It also reveals that there are significant differences ($p < 0.05$) between male and female groups; whereas 2 groups aged less than 46 years old are significantly different with group aged 46 years or older in both gender. **Conclusion:** The study demonstrates that the size and location of maxillary sinus differ significantly between men and women in Bogor and that they follow a specific trend.

Keywords : dental implant, digital radiography, maxillary sinus, panoramic radiography

Background

The maxillary sinus, the largest sinus in the cranium, is an important structure to consider when carrying out treatments on the maxillary region, especially when placing dental implants.¹⁻⁴ Failing to allow adequate bone width surrounding the structure may cause a dental implant to be placed incorrectly, causing oro-antral communication involving the maxillary, ethmoid, frontal and/or sphenoid sinuses.^{1,4-7} If left untreated, oro-antral

communication can further cause undesirable conditions such as pansinusitis, panophthalmitis and orbital cellulitis.⁸⁻¹¹ Early detection of oro-antral communication may help dentists to determine a more beneficial treatment plan, which in turn may lead to greater success in restoring normal tooth function and mastication.^{6,7}

During a treatment plan, dentists must use non-invasive techniques such as radiography to diagnose

conditions that cannot easily be seen. Panoramic radiography¹²⁻¹⁵ is one of the most commonly used techniques due to its ability to reveal the overall condition of patients' teeth and supporting structures, including bone and sinus. Panoramic radiography has many limitations by comparison to newer techniques such as cone beam computed tomography (CBCT) and magnetic resonance imaging (MRI).¹⁶

The existence of new technologies such as digital X-rays has led to more frequent use of X-rays in dentists' daily repertoires.^{12,17} Digital technology allows dentists to perform radiographic examinations more easily, with less radiation and with greater accuracy.¹⁷⁻¹⁹ In panoramic radiography, images can become blurred due to the difference in the concentric and eccentric rotational axes of the radiation source and the object. Image distortion or inaccurate images can also occur due to the difference in distance factor and the alignment of the radiation source and object.^{14,15,17} These factors, combined with the fact that any two dimensional image inevitably causes the superimposition of three dimensional structures, can reduce dentists' diagnostic confidence.^{15,17} Despite the many limitations of panoramic radiography, it is still frequently used by dentists because it is relatively easy to use, generates a diagnostic image quickly and is available in most hospitals throughout Indonesia.²⁰

The ability to understand and interpret radiographic imaging is crucial in determining treatment plan.¹⁴⁻¹⁹ When considering dental implant placement, there are insufficient data on the dimensions of the maxillary sinus among the Indonesian population. Some studies have successfully determined the location of maxillary sinus structures using panoramic X-ray images,^{2,16} however, there have been few studies examining the variance of maxillary sinus width and position among different populations in Indonesia. An effort was made to gather panoramic radiography data in one private practice clinic in Bogor, West Java, Indonesia, in order to determine the maxillary sinus variance among the local residents. The purpose of this study is to make these data available to those who wish to study further the variance in the location and dimension of the maxillary sinus based on age and gender, with the goal of supporting diagnosis and treatment plans for their patients.

Materials and Methods

Study Design

This study was designed to describe the panoramic image from subjects. Three variable groups were applied to each gender. Federer formula showed that the minimum sample size per variable group needed to be at least 10 people. Therefore, the total sample size for each gender in the study is 30 people.

Subjects were classified according to gender and age. The three age groups were determined according to the criteria previously set by the Ministry of Health Republic of Indonesia, with the first variable group being adolescents aged 17 to 25 years old; the second variable group consisting of adults aged 26 to 45 years old; and the third variable group being adults aged 46 years and older.

The variable of interest was maxillary sinus width, which was defined as the radiolucent region demarcated by the radiopaque line located apical to the maxillary dentition. Measurements were determined using the software *Digora for Windows*, which is integrated into the *X-mind Novus Digital Panoramic X-ray unit*, the device that was used to produce the panoramic radiographic imaging.

Study Population

The study population consisted of 60 patients between the ages of 17 and 70 years old (30 males and 30 females) who received treatment in this particular private practice in the city of Bogor. All patients received panoramic radiographic examination using the *X-mind Novus Digital Panoramic X-ray unit*, the data from which were measured using the software *Digora for Windows*. The inclusion criteria for subjects were: 1) complete maxillary permanent dentition, up to 28 teeth; 2) an age range from 17 to 70 years old, further divided into three variables to be grouped according to Ministry of Health Republic of Indonesia; 3) non-smokers; 4) no pathological conditions within or around the maxillary sinus. Patients were excluded from the study if: 1) the panoramic image was distorted; or 2) their maxillary sinus could not be identified.

Sample Collection

Patients were instructed to place their chin on a chin rest and bite the bite block. The X-ray machine was adjusted according to the height of the patient and a lead apron was used. Patients were instructed to remove any metal jewelry. The angle of the patient's head was adjusted so that their mid-sagittal plane and Frankfort plane were aligned with the positioning light on the X-ray equipment. Patients were instructed to press their tongue against their palate and close their lips. They remained stationary for approximately 12 seconds while the X-ray image was taken. The resulting image was then downloaded onto *Digora for Windows* and processed for data collection. The software was calibrated to produce an image that replicated the exact dimension of the patient's anatomy. An example measurement is presented in Fig. 1. In this example, it can be determined that the

width of the left maxillary sinus is 70.97 mm and the width of the right maxillary sinus is 69.12 mm. The palatal apices of teeth 17, 27 and apices of teeth 13, 23 were used as reference points in determining the location of the maxillary sinus. Teeth 13 and 23 were used because their sizes, which do not change significantly, can be used to determine the vertical dimension.²⁰ Teeth 17 and 27 were used as reference points because their locations are the most distal of all the teeth in maxillary dentition. Using an imaginary line drawn between these reference points and the most mesial or most distal points, we can accurately determine the location of maxillary sinus. Two methods of statistical analysis were used: an analysis of variance (ANOVA)²¹ and a Bonferroni post hoc test completed with the help of the SPSS 15.0 computer software.

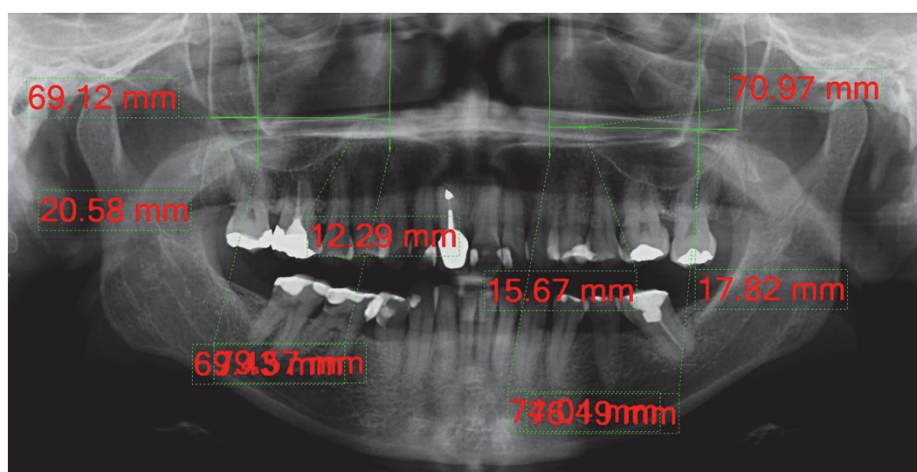


Figure 1. A sample measurement of the dimension and location of the maxillary sinus using the software *Digora for Windows*.

Result

Table 1 shows the data as observed. The data suggests that, on average, men had larger maxillary sinuses than women. The total mean value for men was 79.05 mm, whereas for women it is 66.33 mm. Overall, there was a reduction in the width of the maxillary sinus of older subjects. Subjects aged 17-25 years old, the

mean width was 78.78 mm; subjects aged 26-45 years old the mean width was 77.03 mm; and aged >46 years old the mean width was 67.27 mm.

The data from Table 1 were then analyzed using ANOVA. The results showed statistically significant

differences (ANOVA; $p < 0.05$) between gender categories (men and women), between all three age categories (17-25, 26-45, and ≥ 46) and when both gender and age were compared. The Bonferroni post hoc analysis showed no significant differences between the 17-25 and 26-45 groups and gender ($p > 0.05$). However, both groups showed significant differences by comparison to the ≥ 46 group category in relation to gender, the values were far below the other groups (Fig. 2). ANOVA also showed that gender and age were significantly ($p < 0.05$) affected the width of maxillary sinus.

Table 1. Maxillary sinus width

Gender	Age (years old)	Mean \pm SD (mm)	N
Male	17-25	82.02 \pm 11.42	10
	26-45	80.21 \pm 8.56	10
	≥ 46	74.94 \pm 14.74	10
Total mean		79.05 \pm 11.83	30
Female	17-25	75.54 \pm 9.20	10
	26-45	73.85 \pm 7.90	10
	≥ 46	49.61 \pm 22.21	10
Total mean		66.33 \pm 18.54	30

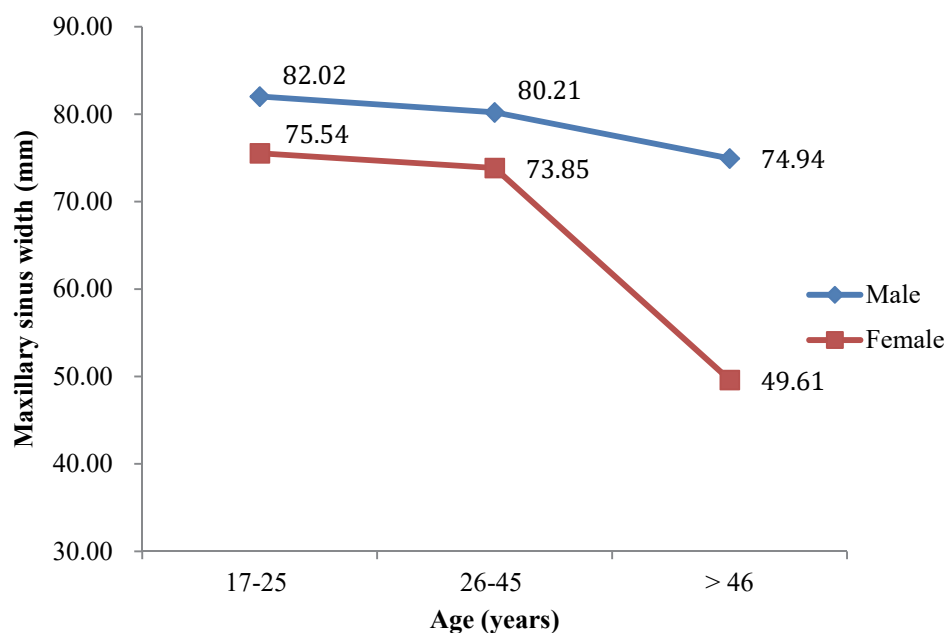


Figure 2. Mean index of maxillary sinus width (mm) for groups aged 17-25, 26-45 and ≥ 46

Discussion

The panoramic X-rays used in this study showed several unexpected anatomical features. As shown in Fig. 3, the mesial aspect of the maxillary sinus was adjacent to teeth numbers 12 and 22. This finding shows that the location of maxillary sinus varies from patient to patient.

Mesial reference points were chosen at the tips of teeth 13 and 23 because the root structure of these teeth is the longest and therefore the most stable. These teeth are important in determining vertical dimension. They are also rarely displaced in the event of extraction of the neighboring teeth.^{18,20,22-24} The reliability of the root structure makes these teeth a consistent reference point.^{19,22,23} In this study, we did not measure the distal aspect of the maxillary sinus toward the reference point of palatal root teeth number 17 and 27 because almost all patients have a distal maxillary sinus location both to the right and left beyond the distal of the reference point. We also did not take into account the maxillary sinus floor location toward the posterior maxillary roots because this was difficult to determine from a panoramic X-ray alone.

The mean value of the mesial side of the patients' maxillary sinus located mesially is about the same as the mesial side of the patients' maxillary sinus located distally from these reference points. This finding suggests that the maxillary sinus does not always begin at the premolar teeth.

In this study, the Ministry of Health Republic of Indonesia's age classifications were used because each age range has its own distinct characteristics. Between the ages of 17 to 25 years old, the growth of teeth numbers 18 and 28 shows a complete pneumatization process at the maxillary sinus. In patients aged 46 and older, hormonal changes for both males and females cause an alteration in bone quality, with the bones becoming more porous. A decrease in bone quality is caused by changes in the activity of osteoclast and osteoblast cells, differences in estrogen production and decreases in calcium absorption in the colon.^{1,24-26} Other factors that influence bone quality include lifestyle, exercise, genetics and nutrition. Bones becoming more porous is often caused by metabolic factors than functional factors.⁶ These factors are consistent with this study's findings that there was no statistically significant difference in maxillary sinus width between the 17 to 25 and 26 to 45 age groups, but there was a statistically significant difference between those groups and the 46 and older group.

The post-hoc analysis demonstrated that there was a reduction in maxillary sinus width among patients aged 46 and older. In other words, there was an increase in bone structure. This phenomenon is supported by Ahlborg *et al.* finding that the bone size increases in conjunction

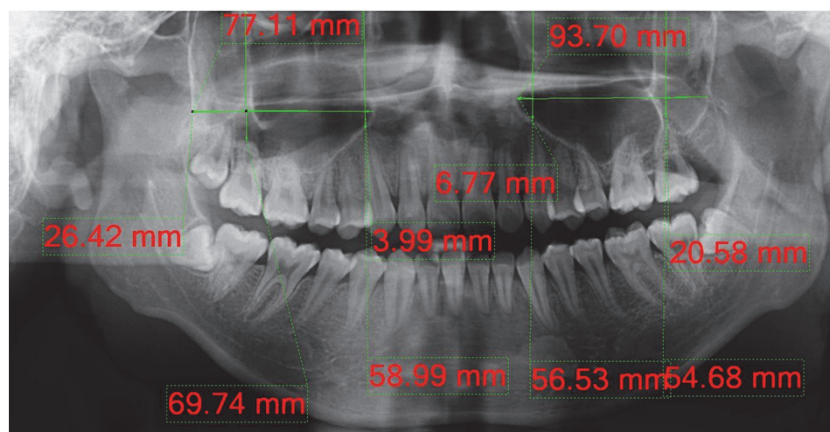


Figure 3. Measurement of the maxillary sinus using panoramic X-ray, mesial aspects of the maxillary sinus going toward the anterior region sextant. (Teeth number 12 and 22)

with increase in age. The data also showed that women aged 46 and older have smaller maxillary sinus width. Hormonal changes might be the main reason for this tendency.²⁶ In addition, as the force of the alveolar bone increases, other bone will increase its own width as a physiological counter-response.²⁴ This is also known as an ontological adaptation, whereby form follows function. Since alveolar bone is sensitive to mechanical stimuli, a process called mechanotransduction causes increased bone width to withstand an increase in force. This process is achieved by reducing sclerotin production in order to increase bone mass. The bone of the upper jaw has a thin cortical bone with equal spreading to the trabecular bone, with bone quality of D3 and D4. Preventing bone fractures is not possible by changing the quality of the bone; it must be done by changing the quantity of the bone.²⁷

A smaller maxillary sinus size, increased bone width, bone mass and bone quantity are some of the things that can lead to a greater chance of successfully restoring normal tooth function and mastication.^{6,7} This is because these factors reduce the difficulties of placing dental implants, especially in the posterior region, which has a risk of oro-antral communication.⁴ This topic will hopefully contribute to further discussion, with the aim of finding out whether there is any correlation between stress and increased thickness of the cortical bone among the Indonesian population.

Radiographic magnification which varies considerably is one of the disadvantages of panoramic radiography. A number of factors, including patient position, the type of equipment, the anatomic location on the maxillary and mandibular arch, gender and the patient's jaw size and shape, may affect the degree of both horizontal and vertical magnification in panoramic radiography.^{28,29} The magnification factor when measuring width was lowest in the maxillary molar region and greatest in the mandibular anterior region. While the lowest magnification value of length was observed in the mandibular molar region, the highest value appeared in the maxillary premolar area.²⁸ In this study, all radiographic records were taken with the same machine and by the same operator, and then analyzed using the same software. This can reduce the possibility

of radiographic magnification issues during measurement.

Knowledge of the anatomy of the maxillary sinus, as well as variations in the width and pneumatization of the sinus, are very important in determining treatment plans for the maxillary region, especially in relation to placing dental implants. Panoramic radiography can be used to determine the size of dental implants inserted and is considered the standard radiographic modality for dental implant planning because it provides an overview of the teeth and surrounding structure.¹²⁻¹⁵ However, the dentist must understand the limitations of this technique, especially its inability to measure buccolingual dimension.

To increase the rate of success and reduce the risk of complications in dental implant procedures, dentists should consider the degree of magnification when selecting the implant site and size, since there are some vital neighboring structures that may be in close proximity to the implant site. A few studies on dental implant procedures have investigated the issue of image magnification in panoramic radiography in relation to anatomical position and gender. Factors such as the difference in jaw size and shape due to variation in patient ethnicity, the type of dental implant used and the type of radiographic machine are important, which explains the disparity between these studies' differing results.²⁸

Conclusion

Our descriptive analysis showed that the size and location of the maxillary sinus among male and female patients at one private clinic in Bogor have a significant and meaningful impact on performing procedures on the maxillary region, especially in relation to the placement of dental implants. These findings showed that maxillary sinus location can be as close to incisor teeth and that younger patients have a larger maxillary sinus size than older patients. Men tend to have larger maxillary sinuses than women, however, both genders exhibit a similar pattern of reduction in size of the maxillary sinus according to their age. The reduction in the size of the maxillary sinus occurs at a faster rate among women than

men, which may be caused by hormonal changes.

Since using panoramic radiograph as a chief point of reference results in two-dimensional images only, this can make it more difficult to determine the width of the bone at the base of sinus. In addition, the magnification issues related to panoramic images should be taken into consideration, since it can be a factor in the success of implant and prosthetic treatments that involve the bone near the maxillary sinus. Further research may utilize more accurate data gathering equipment, such as cone beam computed tomography, to determine the extent of the bone mass surrounding the maxillary sinus and thus obtain more accurate results. This research may also be expanded by determining the variation in the location of the maxillary sinus septa among Indonesian individuals, because a lack of understanding the septa can increase the chances of perforation during sinus elevation surgery.

Acknowledgment

We want to thank you to Dr. Armelia Sari Widyanman for all important suggestion in this study.

Conflict of Interest

Researchers guarantee that there is no conflict of interest in collecting the data for this research. All patients' identities will be kept confidential and are only used for this study.

References

1. Kim YK, Park JY, Kim SG, Kim JS, Kim JD. Magnification rate of digital panoramic radiographs and its effectiveness for pre-operative assessment of dental implants. *Dentomaxillofac Radiol*. 2011;40(2):76-83.
2. Kim JH. A review of the Maxillary Sinus. Oklahoma: Perio-implant advisory; 2012 Sept 12 [cite 2081 Jan 11]. Available from: <http://www.surgicalrestorative.com/articles/2012/09/a-review-of-the-maxillary-sinus.html>
3. Gosau M, Rink D, Driemel O, Draenert FG. Maxillary Sinus Anatomy: A Cadaveric Study with Clinical Implication. *Anat Rec (Hoboken)*. 2009; 292 (3):352-4. DOI: 10.1002/ar.20859
4. Fusari P, Doto M, Chiapasco M. Removal of a dental implant displaced into the maxillary sinus by means of bone lid technique. *Case Rep Dent*.2013;2013:260707. DOI: 10.1155/2013/260707
5. Taschieri S, Fabbro MD, Tsesis I, Corbella S. Maxillary Sinus in Relation to Modern Oral and Maxillofacial Surgery. *Int J Dent*. 2012;391012. DOI: 10.1155/2012/391012
6. Borgonovo AE, Berardinelli FV, Favale M, Mariorana C. Surgical option in Oroantral Fistula treatment. *Open Dent J*. 2012;6:94-8. DOI: 10.2174/1874210601206010094
7. Batra H., Jindal G., & Kaur S. Evaluation of different treatment modalities for closure of oro antral communication and formulation of a rational approach. *J Maxillofac Oral Surg*. 2010;9(1) 13-8. DOI: 10.1007/s12663-010-0006-y
8. Pynn BR, Nish IA. Oral Surgery: Maxillary Sinusitis: A Review for the dental practitioner. [journal] 2001 [cited 2001 November 2013] Available: <http://www.oralhealthgroup.com/news/oral-surgery-maxillary-sinusitis-a-review-for-the-dental-practitioner/1000107403/?&er=NA>
9. Finegold SM, Flynn MJ, Rose FV, Jousimies-Somer H, Jakielaszek C, McTeague M, et al. Bacteriologic Findings Associated with Chronic Bacterial Maxillary Sinusitis in Adults. *Clin Infec Dis*. 2002;.35(4):.428-33. DOI: 10.1086/341899
10. Alkan A, Celebi N, Bas B. Acute Maxillary Sinusitis Associated with Internal Sinus Lifting: Report of a Case. *Eur J Dent*. 2008;2(1):69-72.
11. Sharan A, Madjar D. Maxillary Sinus pneumatization following extraction: a radiographic study. *Int J oral Maxillofac Implants*. 2008;23(1):48-56.
12. Thomson EM, Johnson ON. *Essential of Dental Radiography for Dental Assistant and Hygienist*. 9th ed. United State: Pearson Education; 2012.
13. MacDonald D. *Oral and Maxillofacial Radiology: A Diagnostic Approach*. West Sussex; Wiley-Blackwell; 2011.
14. White SC, Pharoah MJ. *Oral Radiology: Principles and Interpretation*. 6th ed. Missouri: Mosby Elsevier; 2009.
15. Whaites E. *Essentials of Dental Radiography and Radiology*, 4th ed. London: Churchill Livingstone Elsevier; 2007.
16. Kim MJ, Jung UW, Kim CS, Kim KD, Choi SH, Kim CK, et al. Maxillaris sinus septa: prevalence, height, location and morphology. A reformatted computed tomography scan analysis. *J Periodontol* 2006; 77(5):903-8. DOI: 10.1902/jop.2006.050247
17. William MB, Krupinski EA, Strauss KJ, Breedon WK, Rzeszotarski MS, Applegate K, et al. Digital

- Radiography Image Quality: Image Acquisition. *J Am Coll Radiol*. 2007;4(6):371-88.
DOI: 10.1016/j.jacr.2007.02.002
18. Whaites, E. *Radiography and Radiology for Dental Care Professionals*, 2nd ed. Churchill Livingstone Elsevier; 2009.
19. Bansal GJ. Digital Radiography. A Comparison with Modern Conventional Imaging. *Post Grad Med J*. 2006; 82(969): 425-8.
DOI: 10.1136/pgmj.2005.038448
20. Hardanti S, Azhari, Oscandar F. Description of mandibular bone quality based on measurements of cortical thickness using Mental Index of male and female patients between 40-60 years old. *Imaging Sci Dent*. 2011; 41(4): 151-3.
DOI: 10.5624/isd.2011.41.4.151
21. Bruning JL, Kintz BL. *Computational Handbook of Statistics*. 2nd Ed. Scott, Foresman and Company; 1977.
22. Zarb G, Bolender C, Eckert S, Jacob R, Fenton A, Meriscke-Stern R. Prosthodontic treatment for edentulous patients. *J Res Pers*. 2004; 169: 25-7.
23. Andres-Veiga M, Brona-Dorado C, Martinez-Gonzales MJS, Martinez JLQ, Martinez-Gonzales JS. Influence on the patients' sex, type of dental prosthesis and antagonist on residual bone resorption at the level of premaxilla. *Med Oral Patol Oral Cir Bucal*. 2012 17(1): e178-82.
DOI: 10.4317/medoral.17079
24. Clarke B. Normal Bone Anatomy and Physiology. *Clin J Am Soc Nephrol* 2008;3 Suppl 3:S131-9.
DOI: 10.2215/CJN.04151206
25. Rizzoli R, Bonjour JP, Ferrari SL. Osteoporosis, Genetics and Hormones. *J Mol Endocrinol* 2001;26(2):76-94.
26. Ahlborg HG, Johnell O, Turnder CH, Rannevik G, Karlsson MK. Bone loss and bone size after Menopause. *N Engl J Med*. 2003; 349(4):327-34.
DOI: 10.1056/NEJMoa022464
27. Jeong KL. *Bone Biology for Implant Dentistry in Atrophic Alveolar Ridge - Theory and Practice*, Implant Dentistry Ilser Turkyilmaz, IntechOpen; 2011 [cite December 2013]. DOI: 10.5772/16509

Rosalina Tjandrawinata

Analyzing the Width of the Maxillary Sinus from Private Practice in Bogor, Indonesia

Artikel 1

Document Details

Submission ID

trn:oid::3618:138466138

Submission Date

May 11, 2026, 11:26 AM GMT+7

Download Date

May 11, 2026, 11:29 AM GMT+7

File Name

analyzing_the_width_of_the_maxillary_sinus_from.3.pdf

File Size

863.0 KB

8 Pages

4,049 Words

21,139 Characters

9% Overall Similarity

The combined total of all matches, including overlapping sources, for each database.

Filtered from the Report

- ▶ Bibliography
- ▶ Quoted Text
- ▶ Small Matches (less than 15 words)

Exclusions

- ▶ 3 Excluded Sources

Match Groups

- 6 Not Cited or Quoted 6%**
Matches with neither in-text citation nor quotation marks
- 4 Missing Quotations 3%**
Matches that are still very similar to source material
- 0 Missing Citation 0%**
Matches that have quotation marks, but no in-text citation
- 0 Cited and Quoted 0%**
Matches with in-text citation present, but no quotation marks

Top Sources

- 8% Internet sources
- 3% Publications
- 1% Submitted works (Student Papers)

Integrity Flags

0 Integrity Flags for Review

Our system's algorithms look deeply at a document for any inconsistencies that would set it apart from a normal submission. If we notice something strange, we flag it for you to review.

A Flag is not necessarily an indicator of a problem. However, we'd recommend you focus your attention there for further review.

Match Groups

- **6 Not Cited or Quoted 6%**
Matches with neither in-text citation nor quotation marks
- **4 Missing Quotations 3%**
Matches that are still very similar to source material
- **0 Missing Citation 0%**
Matches that have quotation marks, but no in-text citation
- **0 Cited and Quoted 0%**
Matches with in-text citation present, but no quotation marks

Top Sources

- 8% Internet sources
- 3% Publications
- 1% Submitted works (Student Papers)

Top Sources

The sources with the highest number of matches within the submission. Overlapping sources will not be displayed.

1	Internet		
		3dj.gums.ac.ir	3%
2	Internet		
		www.researchgate.net	2%
3	Internet		
		krambalsfemsxehydg.wixsite.com	2%
4	Student papers		
		Universitas Indonesia on 2019-12-11	<1%
5	Internet		
		garuda.kemdikbud.go.id	<1%
6	Internet		
		www.ingentaconnect.com	<1%



Analyzing the Width of the Maxillary Sinus from Private Practice in Bogor, Indonesia

Steven A. Tjang¹, Rosalina Tjandrawinata², Muhammad Novo Perwira Lubis³

¹ Private Practice, Siliwangi 146, Bogor, West Java – Indonesia

² Department of Dental Material, Faculty of Dentistry, Trisakti University – Indonesia

³ Department of Radiology, Faculty of Dentistry, Trisakti University – Indonesia

Corresponding Author: Rosalina Tjandrawinata, Faculty of Dentistry, Trisakti University – Indonesia.

Email: rosalinatjandrawinata@gmail.com

Received date: January 30, 2018. **Accepted date:** April 21, 2018. **Published date:** May 29, 2018.

Copyright: ©2018 Tjang SA, Tjandrawinata R, Lubis MNP. This is an open access article distributed under the terms of the Creative Commons Attribution License, which permits unrestricted use, distribution, and reproduction in any medium provided the original author and sources are credited.

DOI: <http://dx.doi.org/10.26912/sdj.v2i2.2504>

ABSTRACT

Background: X-ray examinations are still a frequent diagnostic tool used by doctors in Indonesia. However, there is an apparent lack of descriptive data regarding the size and location of the maxillary sinus in Indonesian people. **Objective:** The aim of this study is to provide descriptive data on the size and location of the maxillary sinus among patients in the city of Bogor, West Java, Indonesia. **Methods:** Sixty eligible subjects aged 17 to 70 years old were randomized into six groups: male and female patients between 17 and 25 years old; male and female patients between 26 and 45 years old; and male and female patients aged 46 or older. Radiographic pictures were taken using the *X-mind Novus Digital Panoramic X-ray unit* and data were measured using the software *Digora for Windows*. **Results:** Using an analysis of variance, we found that men have significantly larger maxillary sinus dimensions than women (79.05 mm compared to 66.33 mm). It also reveals that there are significant differences ($p < 0.05$) between male and female groups; whereas 2 groups aged less than 46 years old are significantly different with group aged 46 years or older in both gender. **Conclusion:** The study demonstrates that the size and location of maxillary sinus differ significantly between men and women in Bogor and that they follow a specific trend.

Keywords : dental implant, digital radiography, maxillary sinus, panoramic radiography

Background

The maxillary sinus, the largest sinus in the cranium, is an important structure to consider when carrying out treatments on the maxillary region, especially when placing dental implants.¹⁻⁴ Failing to allow adequate bone width surrounding the structure may cause a dental implant to be placed incorrectly, causing oro-antral communication involving the maxillary, ethmoid, frontal and/or sphenoid sinuses.^{1,4-7} If left untreated, oro-antral

communication can further cause undesirable conditions such as pansinusitis, panophthalmitis and orbital cellulitis.⁸⁻¹¹ Early detection of oro-antral communication may help dentists to determine a more beneficial treatment plan, which in turn may lead to greater success in restoring normal tooth function and mastication.^{6,7}

During a treatment plan, dentists must use non-invasive techniques such as radiography to diagnose

conditions that cannot easily be seen. Panoramic radiography¹²⁻¹⁵ is one of the most commonly used techniques due to its ability to reveal the overall condition of patients' teeth and supporting structures, including bone and sinus. Panoramic radiography has many limitations by comparison to newer techniques such as cone beam computed tomography (CBCT) and magnetic resonance imaging (MRI).¹⁶

The existence of new technologies such as digital X-rays has led to more frequent use of X-rays in dentists' daily repertoires.^{12,17} Digital technology allows dentists to perform radiographic examinations more easily, with less radiation and with greater accuracy.¹⁷⁻¹⁹ In panoramic radiography, images can become blurred due to the difference in the concentric and eccentric rotational axes of the radiation source and the object. Image distortion or inaccurate images can also occur due to the difference in distance factor and the alignment of the radiation source and object.^{14,15,17} These factors, combined with the fact that any two dimensional image inevitably causes the superimposition of three dimensional structures, can reduce dentists' diagnostic confidence.^{15,17} Despite the many limitations of panoramic radiography, it is still frequently used by dentists because it is relatively easy to use, generates a diagnostic image quickly and is available in most hospitals throughout Indonesia.²⁰

The ability to understand and interpret radiographic imaging is crucial in determining treatment plan.¹⁴⁻¹⁹ When considering dental implant placement, there are insufficient data on the dimensions of the maxillary sinus among the Indonesian population. Some studies have successfully determined the location of maxillary sinus structures using panoramic X-ray images,^{2,16} however, there have been few studies examining the variance of maxillary sinus width and position among different populations in Indonesia. An effort was made to gather panoramic radiography data in one private practice clinic in Bogor, West Java, Indonesia, in order to determine the maxillary sinus variance among the local residents. The purpose of this study is to make these data available to those who wish to study further the variance in the location and dimension of the maxillary sinus based on age and gender, with the goal of supporting diagnosis and treatment plans for their patients.

Materials and Methods

Study Design

This study was designed to describe the panoramic image from subjects. Three variable groups were applied to each gender. Federer formula showed that the minimum sample size per variable group needed to be at least 10 people. Therefore, the total sample size for each gender in the study is 30 people.

Subjects were classified according to gender and age. The three age groups were determined according to the criteria previously set by the Ministry of Health Republic of Indonesia, with the first variable group being adolescents aged 17 to 25 years old; the second variable group consisting of adults aged 26 to 45 years old; and the third variable group being adults aged 46 years and older.

The variable of interest was maxillary sinus width, which was defined as the radiolucent region demarcated by the radiopaque line located apical to the maxillary dentition. Measurements were determined using the software *Digora for Windows*, which is integrated into the *X-mind Novus Digital Panoramic X-ray unit*, the device that was used to produce the panoramic radiographic imaging.

Study Population

The study population consisted of 60 patients between the ages of 17 and 70 years old (30 males and 30 females) who received treatment in this particular private practice in the city of Bogor. All patients received panoramic radiographic examination using the *X-mind Novus Digital Panoramic X-ray unit*, the data from which were measured using the software *Digora for Windows*. The inclusion criteria for subjects were: 1) complete maxillary permanent dentition, up to 28 teeth; 2) an age range from 17 to 70 years old, further divided into three variables to be grouped according to Ministry of Health Republic of Indonesia; 3) non-smokers; 4) no pathological conditions within or around the maxillary sinus. Patients were excluded from the study if: 1) the panoramic image was distorted; or 2) their maxillary sinus could not be identified.

Sample Collection

Patients were instructed to place their chin on a chin rest and bite the bite block. The X-ray machine was adjusted according to the height of the patient and a lead apron was used. Patients were instructed to remove any metal jewelry. The angle of the patient's head was adjusted so that their mid-sagittal plane and Frankfort plane were aligned with the positioning light on the X-ray equipment. Patients were instructed to press their tongue against their palate and close their lips. They remained stationary for approximately 12 seconds while the X-ray image was taken. The resulting image was then downloaded onto *Digora for Windows* and processed for data collection. The software was calibrated to produce an image that replicated the exact dimension of the patient's anatomy. An example measurement is presented in Fig. 1. In this example, it can be determined that the

width of the left maxillary sinus is 70.97 mm and the width of the right maxillary sinus is 69.12 mm. The palatal apices of teeth 17, 27 and apices of teeth 13, 23 were used as reference points in determining the location of the maxillary sinus. Teeth 13 and 23 were used because their sizes, which do not change significantly, can be used to determine the vertical dimension.²⁰ Teeth 17 and 27 were used as reference points because their locations are the most distal of all the teeth in maxillary dentition. Using an imaginary line drawn between these reference points and the most mesial or most distal points, we can accurately determine the location of maxillary sinus. Two methods of statistical analysis were used: an analysis of variance (ANOVA)²¹ and a Bonferroni post hoc test completed with the help of the SPSS 15.0 computer software.

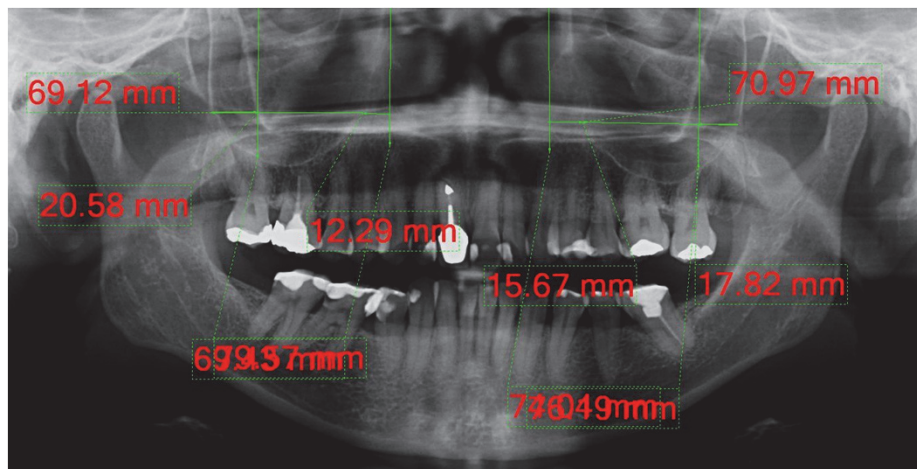


Figure 1. A sample measurement of the dimension and location of the maxillary sinus using the software *Digora for Windows*.

Result

Table 1 shows the data as observed. The data suggests that, on average, men had larger maxillary sinuses than women. The total mean value for men was 79.05 mm, whereas for women it is 66.33 mm. Overall, there was a reduction in the width of the maxillary sinus of older subjects. Subjects aged 17-25 years old, the

mean width was 78.78 mm; subjects aged 26-45 years old the mean width was 77.03 mm; and aged >46 years old the mean width was 67.27 mm.

The data from Table 1 were then analyzed using ANOVA. The results showed statistically significant

differences (ANOVA; $p < 0.05$) between gender categories (men and women), between all three age categories (17-25, 26-45, and ≥ 46) and when both gender and age were compared. The Bonferroni post hoc analysis showed no significant differences between the 17-25 and 26-45 groups and gender ($p > 0.05$). However, both groups showed significant differences by comparison to the ≥ 46 group category in relation to gender, the values were far below the other groups (Fig. 2). ANOVA also showed that gender and age were significantly ($p < 0.05$) affected the width of maxillary sinus.

Table 1. Maxillary sinus width

Gender	Age (years old)	Mean \pm SD (mm)	N
Male	17-25	82.02 \pm 11.42	10
	26-45	80.21 \pm 8.56	10
	≥ 46	74.94 \pm 14.74	10
	Total mean	79.05 \pm 11.83	30
Female	17-25	75.54 \pm 9.20	10
	26-45	73.85 \pm 7.90	10
	≥ 46	49.61 \pm 22.21	10
	Total mean	66.33 \pm 18.54	30

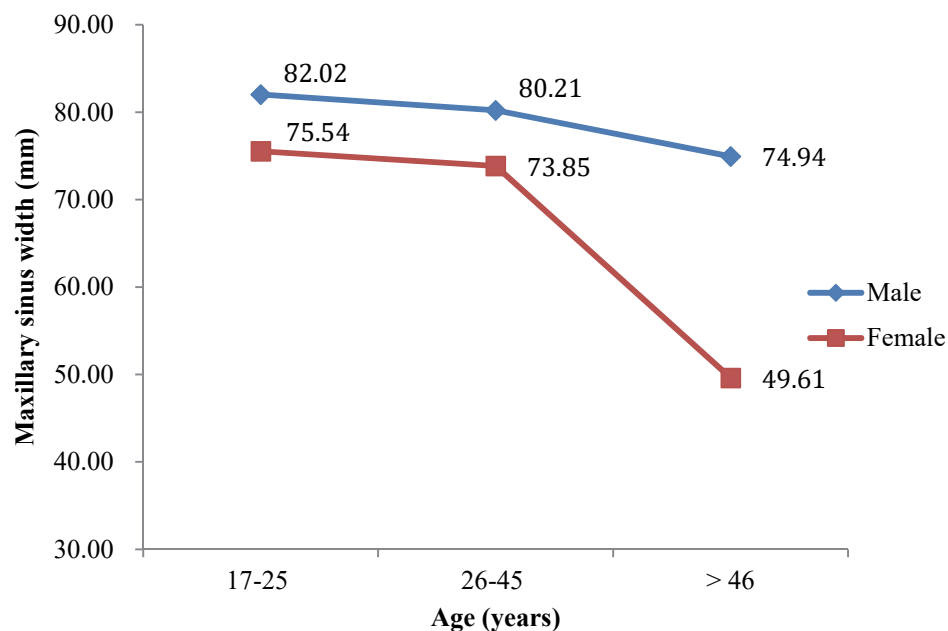


Figure 2. Mean index of maxillary sinus width (mm) for groups aged 17-25, 26-45 and ≥ 46

Discussion

The panoramic X-rays used in this study showed several unexpected anatomical features. As shown in Fig. 3, the mesial aspect of the maxillary sinus was adjacent to teeth numbers 12 and 22. This finding shows that the location of maxillary sinus varies from patient to patient.

Mesial reference points were chosen at the tips of teeth 13 and 23 because the root structure of these teeth is the longest and therefore the most stable. These teeth are important in determining vertical dimension. They are also rarely displaced in the event of extraction of the neighboring teeth.^{18,20,22-24} The reliability of the root structure makes these teeth a consistent reference point.^{19,22,23} In this study, we did not measure the distal aspect of the maxillary sinus toward the reference point of palatal root teeth number 17 and 27 because almost all patients have a distal maxillary sinus location both to the right and left beyond the distal of the reference point. We also did not take into account the maxillary sinus floor location toward the posterior maxillary roots because this was difficult to determine from a panoramic X-ray alone.

The mean value of the mesial side of the patients' maxillary sinus located mesially is about the same as the mesial side of the patients' maxillary sinus located distally from these reference points. This finding suggests that the maxillary sinus does not always begin at the premolar teeth.

In this study, the Ministry of Health Republic of Indonesia's age classifications were used because each age range has its own distinct characteristics. Between the ages of 17 to 25 years old, the growth of teeth numbers 18 and 28 shows a complete pneumatization process at the maxillary sinus. In patients aged 46 and older, hormonal changes for both males and females cause an alteration in bone quality, with the bones becoming more porous. A decrease in bone quality is caused by changes in the activity of osteoclast and osteoblast cells, differences in estrogen production and decreases in calcium absorption in the colon.^{1,24-26} Other factors that influence bone quality include lifestyle, exercise, genetics and nutrition. Bones becoming more porous is often caused by metabolic factors than functional factors.⁶ These factors are consistent with this study's findings that there was no statistically significant difference in maxillary sinus width between the 17 to 25 and 26 to 45 age groups, but there was a statistically significant difference between those groups and the 46 and older group.

The post-hoc analysis demonstrated that there was a reduction in maxillary sinus width among patients aged 46 and older. In other words, there was an increase in bone structure. This phenomenon is supported by Ahlborg *et al.* finding that the bone size increases in conjunction

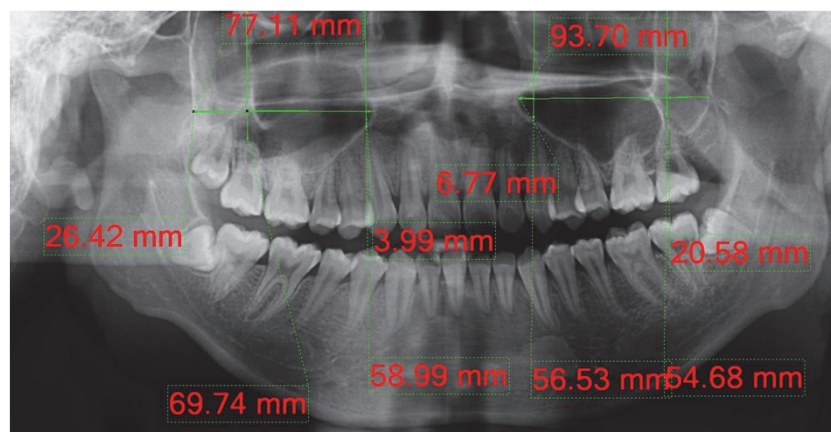


Figure 3. Measurement of the maxillary sinus using panoramic X-ray, mesial aspects of the maxillary sinus going toward the anterior region sextant. (Teeth number 12 and 22)

with increase in age. The data also showed that women aged 46 and older have smaller maxillary sinus width. Hormonal changes might be the main reason for this tendency.²⁶ In addition, as the force of the alveolar bone increases, other bone will increase its own width as a physiological counter-response.²⁴ This is also known as an ontological adaptation, whereby form follows function. Since alveolar bone is sensitive to mechanical stimuli, a process called mechanotransduction causes increased bone width to withstand an increase in force. This process is achieved by reducing sclerotin production in order to increase bone mass. The bone of the upper jaw has a thin cortical bone with equal spreading to the trabecular bone, with bone quality of D3 and D4. Preventing bone fractures is not possible by changing the quality of the bone; it must be done by changing the quantity of the bone.²⁷

A smaller maxillary sinus size, increased bone width, bone mass and bone quantity are some of the things that can lead to a greater chance of successfully restoring normal tooth function and mastication.^{6,7} This is because these factors reduce the difficulties of placing dental implants, especially in the posterior region, which has a risk of oro-antral communication.⁴ This topic will hopefully contribute to further discussion, with the aim of finding out whether there is any correlation between stress and increased thickness of the cortical bone among the Indonesian population.

Radiographic magnification which varies considerably is one of the disadvantages of panoramic radiography. A number of factors, including patient position, the type of equipment, the anatomic location on the maxillary and mandibular arch, gender and the patient's jaw size and shape, may affect the degree of both horizontal and vertical magnification in panoramic radiography.^{28,29} The magnification factor when measuring width was lowest in the maxillary molar region and greatest in the mandibular anterior region. While the lowest magnification value of length was observed in the mandibular molar region, the highest value appeared in the maxillary premolar area.²⁸ In this study, all radiographic records were taken with the same machine and by the same operator, and then analyzed using the same software. This can reduce the possibility

of radiographic magnification issues during measurement.

Knowledge of the anatomy of the maxillary sinus, as well as variations in the width and pneumatization of the sinus, are very important in determining treatment plans for the maxillary region, especially in relation to placing dental implants. Panoramic radiography can be used to determine the size of dental implants inserted and is considered the standard radiographic modality for dental implant planning because it provides an overview of the teeth and surrounding structure.¹²⁻¹⁵ However, the dentist must understand the limitations of this technique, especially its inability to measure buccolingual dimension.

To increase the rate of success and reduce the risk of complications in dental implant procedures, dentists should consider the degree of magnification when selecting the implant site and size, since there are some vital neighboring structures that may be in close proximity to the implant site. A few studies on dental implant procedures have investigated the issue of image magnification in panoramic radiography in relation to anatomical position and gender. Factors such as the difference in jaw size and shape due to variation in patient ethnicity, the type of dental implant used and the type of radiographic machine are important, which explains the disparity between these studies' differing results.²⁸

Conclusion

Our descriptive analysis showed that the size and location of the maxillary sinus among male and female patients at one private clinic in Bogor have a significant and meaningful impact on performing procedures on the maxillary region, especially in relation to the placement of dental implants. These findings showed that maxillary sinus location can be as close to incisor teeth and that younger patients have a larger maxillary sinus size than older patients. Men tend to have larger maxillary sinuses than women, however, both genders exhibit a similar pattern of reduction in size of the maxillary sinus according to their age. The reduction in the size of the maxillary sinus occurs at a faster rate among women than

men, which may be caused by hormonal changes.

Since using panoramic radiograph as a chief point of reference results in two-dimensional images only, this can make it more difficult to determine the width of the bone at the base of sinus. In addition, the magnification issues related to panoramic images should be taken into consideration, since it can be a factor in the success of implant and prosthetic treatments that involve the bone near the maxillary sinus. Further research may utilize more accurate data gathering equipment, such as cone beam computed tomography, to determine the extent of the bone mass surrounding the maxillary sinus and thus obtain more accurate results. This research may also be expanded by determining the variation in the location of the maxillary sinus septa among Indonesian individuals, because a lack of understanding the septa can increase the chances of perforation during sinus elevation surgery.

Acknowledgment

We want to thank you to Dr. Armelia Sari Widyanman for all important suggestion in this study.

Conflict of Interest

Researchers guarantee that there is no conflict of interest in collecting the data for this research. All patients' identities will be kept confidential and are only used for this study.

References

1. Kim YK, Park JY, Kim SG, Kim JS, Kim JD. Magnification rate of digital panoramic radiographs and its effectiveness for pre-operative assessment of dental implants. *Dentomaxillofac Radiol*. 2011;40(2):76-83.
2. Kim JH. A review of the Maxillary Sinus. Oklahoma: Perio-implant advisory; 2012 Sept 12 [cite 2081 Jan 11]. Available from: <http://www.surgicalrestorative.com/articles/2012/09/a-review-of-the-maxillary-sinus.html>
3. Gosau M, Rink D, Driemel O, Draenert FG. Maxillary Sinus Anatomy: A Cadaveric Study with Clinical Implication. *Anat Rec (Hoboken)*. 2009; 292 (3):352-4. DOI: 10.1002/ar.20859
4. Fusari P, Doto M, Chiapasco M. Removal of a dental implant displaced into the maxillary sinus by means of bone lid technique. *Case Rep Dent*. 2013;2013:260707. DOI: 10.1155/2013/260707
5. Taschieri S, Fabbro MD, Tsesis I, Corbella S. Maxillary Sinus in Relation to Modern Oral and Maxillofacial Surgery. *Int J Dent*. 2012;391012. DOI: 10.1155/2012/391012
6. Borgonovo AE, Berardinelli FV, Favale M, Mariorana C. Surgical option in Oroantral Fistula treatment. *Open Dent J*. 2012;6:94-8. DOI: 10.2174/1874210601206010094
7. Batra H., Jindal G., & Kaur S. Evaluation of different treatment modalities for closure of oro antral communication and formulation of a rational approach. *J Maxillofac Oral Surg*. 2010;9(1) 13-8. DOI: 10.1007/s12663-010-0006-y
8. Pynn BR, Nish IA. Oral Surgery: Maxillary Sinusitis: A Review for the dental practitioner. [journal] 2001 [cited 2001 November 2013] Available: <http://www.oralhealthgroup.com/news/oral-surgery-maxillary-sinusitis-a-review-for-the-dental-practitioner/1000107403/?&er=NA>
9. Finegold SM, Flynn MJ, Rose FV, Jousimies-Somer H, Jakielaszek C, McTeague M, et al. Bacteriologic Findings Associated with Chronic Bacterial Maxillary Sinusitis in Adults. *Clin Infec Dis*. 2002;.35(4):.428-33. DOI: 10.1086/341899
10. Alkan A, Celebi N, Bas B. Acute Maxillary Sinusitis Associated with Internal Sinus Lifting: Report of a Case. *Eur J Dent*. 2008;2(1):69-72.
11. Sharan A, Madjar D. Maxillary Sinus pneumatization following extraction: a radiographic study. *Int J oral Maxillofac Implants*. 2008;23(1):48-56.
12. Thomson EM, Johnson ON. *Essential of Dental Radiography for Dental Assistant and Hygienist*. 9th ed. United State: Pearson Education; 2012.
13. MacDonald D. *Oral and Maxillofacial Radiology: A Diagnostic Approach*. West Sussex; Wiley-Blackwell; 2011.
14. White SC, Pharoah MJ. *Oral Radiology: Principles and Interpretation*. 6th ed. Missouri: Mosby Elsevier; 2009.
15. Whaites E. *Essentials of Dental Radiography and Radiology*, 4th ed. London: Churchill Livingstone Elsevier; 2007.
16. Kim MJ, Jung UW, Kim CS, Kim KD, Choi SH, Kim CK, et al. Maxillaris sinus septa: prevalence, height, location and morphology. A reformatted computed tomography scan analysis. *J Periodontol* 2006; 77(5):903-8. DOI: 10.1902/jop.2006.050247
17. William MB, Krupinski EA, Strauss KJ, Breedon WK, Rzeszotarski MS, Applegate K, et al. Digital

- Radiography Image Quality: Image Acquisition. *J Am Coll Radiol*. 2007;4(6):371-88.
DOI: 10.1016/j.jacr.2007.02.002
18. Whaites, E. *Radiography and Radiology for Dental Care Professionals*, 2nd ed. Churchill Livingstone Elsevier; 2009.
19. Bansal GJ. Digital Radiography. A Comparison with Modern Conventional Imaging. *Post Grad Med J*. 2006; 82(969): 425-8.
DOI: 10.1136/pgmj.2005.038448
20. Hardanti S, Azhari, Oscandar F. Description of mandibular bone quality based on measurements of cortical thickness using Mental Index of male and female patients between 40-60 years old. *Imaging Sci Dent*. 2011; 41(4): 151-3.
DOI: 10.5624/isd.2011.41.4.151
21. Bruning JL, Kintz BL. *Computational Handbook of Statistics*. 2nd Ed. Scott, Foresman and Company; 1977.
22. Zarb G, Bolender C, Eckert S, Jacob R, Fenton A, Meriscke-Stern R. Prosthodontic treatment for edentulous patients. *J Res Pers*. 2004; 169: 25-7.
23. Andres-Veiga M, Brona-Dorado C, Martinez-Gonzales MJS, Martinez JLQ, Martinez-Gonzales JS. Influence on the patients' sex, type of dental prosthesis and antagonist on residual bone resorption at the level of premaxilla. *Med Oral Patol Oral Cir Bucal*. 2012 17(1): e178-82.
DOI: 10.4317/medoral.17079
24. Clarke B. Normal Bone Anatomy and Physiology. *Clin J Am Soc Nephrol* 2008;3 Suppl 3:S131-9.
DOI: 10.2215/CJN.04151206
25. Rizzoli R, Bonjour JP, Ferrari SL. Osteoporosis, Genetics and Hormones. *J Mol Endocrinol* 2001;26(2):76-94.
26. Ahlborg HG, Johnell O, Turnder CH, Rannevik G, Karlsson MK. Bone loss and bone size after Menopause. *N Engl J Med*. 2003; 349(4):327-34.
DOI: 10.1056/NEJMoa022464
27. Jeong KL. *Bone Biology for Implant Dentistry in Atrophic Alveolar Ridge - Theory and Practice*, Implant Dentistry Ilser Turkyilmaz, IntechOpen; 2011 [cite December 2013]. DOI: 10.5772/16509