

Case Report of Management of Increased Intracranial Pressure in Epidural Hematoma

Rikki Oktrian Putra¹, Yudhisman Imran^{2,3*}, Mulia Rahmansyah^{4,5}, Triasti Khusfiani⁶, Mustika Anggiane Putri⁷, Ainaya Az zahra⁸

¹ Alumni of Universitas Trisakti, Indonesia

² Department of Neurology, Faculty of Medicine, Universitas Trisakti, Indonesia

³ Department of Neurology, Hermina Daan Mogot Hospitals, Indonesia


⁴ Department of Radiology, Universitas Trisakti, Indonesia

⁵ Department of Radiology, Hermina Daan Mogot Hospitals, Indonesia

⁶ Department of Pharmacology, Universitas Trisakti, Indonesia

⁷ Department of Physiology, Universitas Trisakti, Indonesia

⁸ Medical Education Study Programme, Universitas Trisakti, Indonesia

*Corresponding Author: Yudhisman Imran, E-mail: yudhisman.imran@trisakti.ac.id 

ARTICLE INFO

Article history:

Received

03 January 2024

Revised

20 March 2024

Accepted

31 March 2024

Manuscript ID:

JSOCMED-030124-33-2

Checked for Plagiarism: Yes

Language Editor: Rebecca

Editor-in-Chief: Prof. Aznan Lelo, PhD

Keywords

ABSTRACT

Epidural haematoma (EDH) is an abnormal collection of blood between the bone and the dura mater. A 26-year-old male was brought by his family to the Hospital Emergency Department with complaints of headache after a traffic accident. The patient was unconscious for 5 minutes and had one seizure. After the seizure, the patient regained consciousness and complained of headache and vomiting. Neurological status examination was within normal limits. CT-Scan examination of the head found a linear fracture accompanied by a picture of epidural haemorrhage (EDH) 59.34 cc in the right parietal, and midline shift to the left. The patient received conservative management in the form of mannitol. The patient also underwent operative management in the form of decompressive craniotomy for haematoma evacuation. This case describes a patient with EDH with symptoms of increased intracranial pressure and received medical and operative management.

Epidural haematoma, Increased intracranial pressure, Mannitol, Craniotomy

How to cite: Putra RO, Imran Y, Rahmansyah M, Khusfiani T, Putri MA, Az zahra A. Role of Intravenous Immunoglobulin (IVIG) in Patients with Guillain Barre Syndrome with Severe Community Pneumonia in The Intensive Care Unit (ICU). *Journal of Society Medicine*. 2024; 3(3): 497-501. DOI: <https://doi.org/10.47353/jsocmed.v3i3.123>

INTRODUCTION

Head trauma is the most common cause of disability in both young and old in many countries.[1] It is estimated that around 69 million people worldwide experience traumatic brain injury each year. The effects of traumatic brain injury can include extra-axial (outside the brain tissue) and intra-axial haemorrhage, which is bleeding from the brain parenchyma. Extra-axial haemorrhage includes subdural haematoma (SDH) and epidural haematoma (EDH).[2]

EDH is a type of intracranial haemorrhage that commonly occurs due to a skull fracture from a head injury, causing blood vessels to rupture and blood to accumulate in the space between the dura mater and the skull. EDH will occupy the intracranial space, so rapid expansion of the lesion can lead to pressure on the brain which can result in loss of consciousness, reversible or irreversible disability and even death. Rapid disease progression can lead to increased intracranial pressure leading to brain herniation, a potentially deadly problem that requires immediate medical or operative management.[3]

This case report presents a case of EDH with medical and operative management of symptoms of increased intracranial pressure.

CASE REPORT

A 26-year-old man was brought by his family to the Emergency Unit of Hermina Daan Mogot Hospital with complaints of headache after a traffic accident when the patient was riding a motorbike. In the anamnesis, the patient said he fell off the motorbike after hitting a person who was repairing a chain on the side of the road. The patient fell with the right side of his head touching the asphalt. The patient was wearing a helmet. After falling, the patient was unconscious for 5 minutes after the incident and had one seizure at the scene. After the seizure, the patient regained consciousness and was taken to his home by a resident not far from the scene. At home the patient complained of headache and vomiting. The patient was taken to the nearest clinic by his family, then the doctor at the clinic suggested that the patient be referred to the hospital for further examination.

Upon arrival at the emergency room of Hermina Daan Mogot Hospital, the patient was conscious, and there were no symptoms of regression of consciousness from the time the patient was at home until he arrived at the hospital. On physical examination, blood pressure was 130/70mmHg, pulse rate: 82 beats per minute, respiratory rate: 24 beats per minute and temperature 37.2 degrees centigrade. The patient's pain scale was measured by numeric rating scale and obtained a value of 5. Neurological status examination was within normal limits. CT-Scan examination of the head found a linear fracture accompanied by a picture of acute epidural haemorrhage (EDH) with a volume of +/- 59.34 cc in the right parietal region, there was also an increase in intracranial pressure with a midline shift of +/- 3 mm to the left. (Fig. 1)

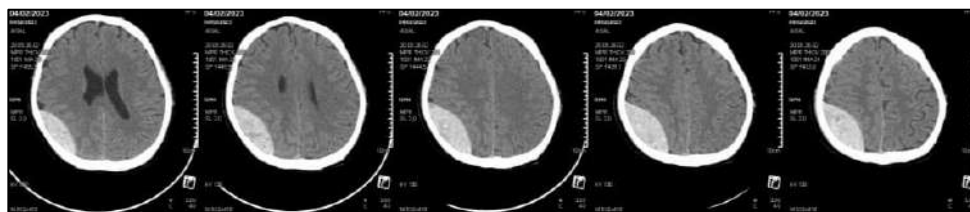


Figure 1. Preoperative CT-Scan results

Laboratory examination results showed leucocytosis with a value of $19.24 \times 10^3/\text{mL}$. Thorax x-ray and ekg examination were within normal limits. Initial management was IVFD NaCl 500ml/12h, mannitol 1x250ml then continued with a follow-up dose of 4x125ml, ketorolac 3x30mg IV, omeprazole 1x40mg, tranexamic acid 3x500mg, ceftriaxone 1x2gr IV, citicolin 2x500mg IV, phenytoin 3x100mg IV. The headache decreased after the patient received mannitol. The patient was also referred to a neurosurgeon but the family did not agree to surgery. The patient received conservative treatment. During treatment the patient remained conscious, vital signs were stable, and was still receiving continued doses of mannitol. Complaints of headache pain decreased so the dose of mannitol was gradually reduced. On the 6th day of treatment, the patient agreed to craniotomy surgery. Postoperatively, the headache complaints decreased. The dose of mannitol was reduced to 1x125ml and planned to be stopped the next day. On the 11th day of treatment, the patient had no complaints of headache so the patient was planned to be outpatient. Before the patient was discharged, a repeat head CT-Scan was performed, the results of post craniotomy CT-Scan showed a picture of epidural haemorrhage (EDH) with a reduced volume of +/- 21.99 cc (previously +/- 59.34 cc) and increased intracranial pressure improvement (midline shift +/- 2.1 mm to the left) (Fig. 2). There was no seizure during treatment and the patient was discharged the next day.

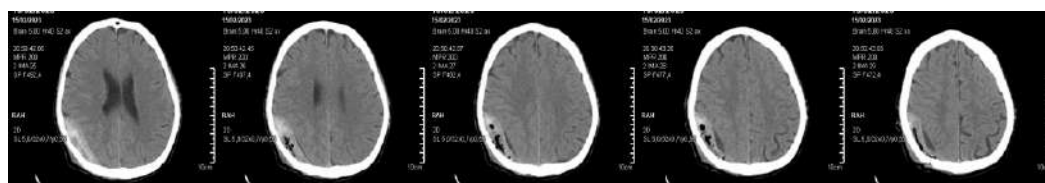

Figure 2 Postoperative head CT scan

DISCUSSION

Epidural haematoma (EDH) is an abnormal collection of blood between the bone and the dura mater. Epidural haematomas usually occur in young adults (20-40 years old), less commonly in children younger than 2 years

old and people over 60 years old.[4] EDHs comprise 2-4% of all traumatic brain injuries, but the mortality rate is as high as 1.2%-33%. Traffic accidents are the most frequent cause of EDH, accounting for 53% (approximately 30%-86%) of all EDH, followed by other causes including falls, assaults, sports injuries, and so on. 5 Among all head trauma EDH is the most deadly. EDH occurs due to skull fracture from a head injury resulting in rupture of the media meningeal artery and accumulation of blood in the space between the dura mater and the skull.[6] The most common locations of EDH are temporo-parietal and temporal, due to the susceptibility of these areas to external trauma and their close anatomical relationship with the middle meningeal artery. 7 Blood in cases of EDH will occupy space within the intracranial space, so rapid expansion of these lesions can cause pressure on the brain which can result in increased intracranial pressure, decreased consciousness, reversible or irreversible disability and even death.[3]

The patient was a young adult male who sustained a head injury due to a traffic accident. Based on age, the highest incidence of EDH is young adults (18-39 years old). Young adults are an age group that often performs activities that have a risk of head injury because this age period is the most active period in life. EDH cases rarely occur at the age of over 60 years, this is due to anatomically old age, the attachment of the dura mater to the skull bone is getting stronger so it is difficult to provide a gathering place for epidural bleeding.[8]

The patient fainted for 5 minutes, after regaining consciousness the patient had 1x seizures. The patient complained of headache (NRS: 5) and vomiting when conscious. CT scan examination of the head bone window found a linear fracture in the dextra parietal region, and EDH with a volume of 59.34cc in the right parietal region, and a picture of increased intracranial pressure with a midline shift of +/- 3mm to the left.

The patient in this case also experienced headache and vomiting, which are symptoms of increased intracranial pressure. This is also supported by the radiological examination results of the head CT scan in the form of +/- 59.34 cc in the right parietal region, and a picture of increased intracranial pressure with a midline shift of +/- 3mm to the left. EDH volume is usually stable, and can reach maximum volume only minutes or hours after trauma.8 In most EDH patients who receive conservative management, enlargement of bleeding volume occurs 8 hours after injury (up to 36 hours maximum). In head trauma the presence of oedema and mass effect due to haemorrhage can result in increased intracranial pressure, reduced cerebral perfusion pressure and global ischaemia.[10] Increased intracranial pressure is associated with mortality and morbidity. In the period following brain trauma, intracranial hypertension, systemic hypotension, hypoxia, hyperpyrexia, hypocapnia and hypoglycaemia occur and these parameters can be used to predict worsening outcomes following head trauma.[11]

In this case, the patient complained of headache and received mannitol therapy both in the emergency room and in the inpatient room. After the administration of mannitol, the complaints of headache decreased so that the dose of mannitol was gradually reduced. EDH management can be divided into 2, namely conservatively and surgically. Conservative management attempts to minimise secondary brain injury with haemodynamic monitoring and intracranial pressure management 5 The use of osmotic agents (mannitol and hypertonic saline) is recommended to reduce the increase in intracranial pressure and to increase cerebral blood flow to hypoperfused brain regions. Mannitol has been used as a nonsurgical treatment option to control intracranial hypertension, tissue displacement, decrease brain volume and prevent herniation, increase cerebral blood flow, thereby improving oxygen supply In cases of head trauma in an attempt to reduce the intensity and duration of ICP elevation, mannitol administration has been recommended as a first-line agent for many years.[10,11]

Mannitol doses of 0.5-1 g/kg are given over 5-15 minutes and can be repeated every 4-6 hours. A reduction in the increase in intracranial pressure occurs within 30 to 45 minutes after mannitol administration. Mannitol cannot be given to patients with hypotension or renal failure due to its mechanism of action as a diuretic that can lower blood pressure and is excreted through the kidneys. Repeated administration of mannitol may cause a rebound phenomenon, an increase in intracranial pressure due to the accumulation of mannitol in the extracellular fluid. Due to this side effect, discontinuation of mannitol should be done gradually by reducing the dose when mannitol is administered.[12]

In this patient during conservative treatment still complained of headache despite improvement, this was due to the large epidural haemorrhage volume of 59.34cc and accompanied by a midline shift of +/- 3mm to the left. The patient then underwent hematoma evacuation craniotomy surgery. Postoperatively, the patient's headache complaints decreased. On repeat head CT scan examination, the blood volume was reduced to +/- 21.99 cc and increased intracranial pressure improved (midline shift +/- 2.1 mm to the left). Mannitol administration was stopped a few days later. When the patient no longer complained of headache and general medical condition was good, the patient was discharged.

Indications for surgery for epidural haematoma with craniotomy are when the volume of the haematoma is >40 ml in the supratentorial or >10ml in the infratentorial, midline shift >1cm and pressure on the ventricles or cisterna, progressively increasing intracranial pressure >2.7 kPa (270mmH₂O), and gradual deterioration of consciousness.[13] It is strongly recommended that patients with acute EDH in a state of decreased consciousness with a GCS score < 9 with pupillary anisocoria undergo surgical evacuation as soon as possible.[14]

Decompressive craniotomy (DC) has proven to be a useful means of lowering intracranial pressure, and is usually performed as a last resort in patients with malignant oedema. Although technically straightforward, the procedure is not without significant complications. A sudden drop in cerebral vascular pressure after DC can sometimes lead to progressive haemorrhage. In another study it was also found that after craniectomy to evacuate an epidural haematoma, some patients suffered clinical deterioration such as cerebral infarction, due to a sharp postoperative increase in intracranial pressure. Although the incidence was relatively low.[6]

CONCLUSION

In cases of EDH, there may be symptoms of increased intracranial pressure that can be obtained clinically or by supporting CT-Scan examination of the head. The management of EDH based on clinical and supporting examinations can be conservative to reduce intracranial pressure or operative to reduce oedema or to evacuate haematoma.

DECLARATIONS

Thank you to Hermina Daan Mogot Hospital and all those who helped write the case report.

CONSENT FOR PUBLICATION

The Authors agree to publication in Journal of Society Medicine.

FUNDING

This research has received no external funding

COMPETING INTERESTS

The authors declare that there is no conflict of interest in this report.

ACKNOWLEDGMENTS

None

REFERENCE

1. Pramana R, Imran Y. Hubungan antara trauma kepala dan fungsi kognitif pada usia dewasa muda. J Biomedika dan Kesehatan. 2019; 2(4):149-53.
2. Chen H, Guo Y, Chen SW, Wang G, Cao HL, Chen J, et al. Progressive epidural hematoma in patients with head trauma: incidence, outcome, and risk factors. Emerg Med Int. 2012; 2012: 134905.

3. Istiadjid ES M, Rahayu M, Balafif F. Correlation of severe head injury epidural hematoma trepanation respond time with outcome. *MNJ*. 2016; 2 (1): 8–12.
4. Kulesza B, Mazurek M, Rams Ł, Nogalski A. Acute epidural and subdural hematomas after head injury: Clinical distinguishing features. *Indian J Surg*. 2021; 83 (S1): 96–104.
5. Jeong YH, Oh JW, Cho S, Korean Trauma Data Bank System Committee. Clinical Outcome of Acute Epidural Hematoma in Korea: Preliminary Report of 285 Cases Registered in the Korean Trauma Data Bank System. *Korean J Neurotrauma*. 2016; 12 (2): 47–54
6. Yang C, Hui J, Xie L, Feng J, Jiang J. Comparative effectiveness of different surgical procedures for traumatic acute epidural haematoma: study protocol for Prospective, Observational Real-world Treatments of AEDH in Large-scale Surgical Cases (PORTALS-AEDH). *BMJ Open*. 2022; 12 (3): e051247.
7. Rosyidi RM, Priyanto B, Al Fauzi A, Sutiono AB. Toward zero mortality in acute epidural hematoma: A review in 268 cases problems and challenges in the developing country. *Interdiscip Neurosurg*. 2019; 17: 12–8.
8. Apriliyanty RJT, Sabri, Delyuzar, Dharmajaya R. Correlation Between Epidural Hematoma Volume In Temporal Region With Glasgow Coma Scale On Patients With Head Injury At Haji Adam Malik General Hospital Medan In The Year Of 2018. *Asian Australasian Neuro and Health Science Journal*. 2020; 2 (1): 1-7
9. Tahir AM. Patofisiologi kesadaran menurun. *UMI Medical Journal*. 2018; 3 (1): 1-9
10. Agrawal A, Rao M. Expansion of Contralateral Extradural Hematoma following Mannitol Therapy. *Indian J Neurotrauma*. 2023; 20: 159–160
11. Bisri DY. Mannitol untuk Hipertensi Intrakranial pada Cedera Otak Traumatik: apakah masih diperlukan? *JNI*. 2013; 2 (3): 177–87
12. Arifianto MR, Ma'ruf AZ, Ibrahim A. Efficacy comparison of mannitol and hypertonic saline for Traumatic Brain Injury (TBI) treatment. *Bali Med J*. 2016; 5 (3): 516-521
13. Wang W. Minimally Invasive Surgical Treatment of Acute Epidural Hematoma: Case Series. *Biomed Res Int*. 2016; 2016: 6507350: 1-8.
14. Bullock RM, Chesnut R, Ghajar J, Gordon D, Hartl R, Newel DW. et al. Surgical Management of Acute Epidural Hematomas. *Neurosurgery*. 2006; 58 (3): 7-15