

Get More with  
SINTA Insight

Go to Insight



## JURNAL RADIOLOGI DENTOMAKSILOFASIAL INDONESIA (JRDI)

📍 [IKATAN RADIOLOGI KEDOKTERAN GIGI INDONESIA](#)

★ P-ISSN : 26850249 <> E-ISSN : 26861321



0.3

Impact Factor



115

Google Citations



Sinta 4

Current  
Accreditation
[📖 Google Scholar](#)
[📖 Garuda](#)
[🌐 Website](#)
[🌐 Editor URL](#)

### History Accreditation

2018

2019

2020

2021

2022

2023

2024

### Citation Per Year By Google Scholar



### Journal By Google Scholar

	All	Since 2018
Citation	115	115
h-index	6	6
i10-index	3	3

## Garuda

## Google Scholar

[A suspect of large dentigerous cyst associated with impacted canine evaluated by CBCT: a case report in a young patient](#)

[Ikatan Radiologi Kedokteran Gigi Indonesia](#) [Jurnal Radiologi Dentomaksilofasial Indonesia \(JRDI\) Vol 7 No 1 \(2023\): Jurnal Radiologi Dentomaksilofasial Indonesia \(JRDI\) 41-46](#)

📅 2023 [DOI: 10.32793/jrdi.v7i1.1001](#) [Accred : Sinta 4](#)

[Bilateral bifid condyle mandibula features in panoramic radiography: a case report](#)

[Ikatan Radiologi Kedokteran Gigi Indonesia](#) [Jurnal Radiologi Dentomaksilofasial Indonesia \(JRDI\) Vol 7 No 1 \(2023\): Jurnal Radiologi Dentomaksilofasial Indonesia \(JRDI\) 31-34](#)

📅 2023 [DOI: 10.32793/jrdi.v7i1.1005](#) [Accred : Sinta 4](#)

[Variation of normal condyle shape based on gender in panoramic radiographs](#)

[Ikatan Radiologi Kedokteran Gigi Indonesia](#) [Jurnal Radiologi Dentomaksilofasial Indonesia \(JRDI\) Vol 7 No 1 \(2023\): Jurnal Radiologi Dentomaksilofasial Indonesia \(JRDI\) 21-26](#)

📅 2023 [DOI: 10.32793/jrdi.v7i1.1007](#) [Accred : Sinta 4](#)

[Panoramic radiograph measurement of upper mandibular ramus breadth for sex determination](#)

[Ikatan Radiologi Kedokteran Gigi Indonesia](#) [Jurnal Radiologi Dentomaksilofasial Indonesia \(JRDI\) Vol 7 No 1 \(2023\): Jurnal Radiologi Dentomaksilofasial Indonesia \(JRDI\) 27-30](#)

📅 2023 [DOI: 10.32793/jrdi.v7i1.830](#) [Accred : Sinta 4](#)

[Diagnostic accuracy of periapical radiolucency using periapical radiography and cone-beam computed tomography](#)

[Ikatan Radiologi Kedokteran Gigi Indonesia](#) [Jurnal Radiologi Dentomaksilofasial Indonesia \(JRDI\) Vol 7 No 1 \(2023\): Jurnal Radiologi Dentomaksilofasial Indonesia \(JRDI\) 1-8](#)

2023 DOI: 10.32793/jrdi.v7i1.934 Accred : Sinta 4

### [Third molar impaction prevalence and pattern: a panoramic radiography investigation](#)

Ikatan Radiologi Kedokteran Gigi Indonesia [Jurnal Radiologi Dentomaksilofasial Indonesia \(JRDI\) Vol 7 No 1 \(2023\): Jurnal Radiologi Dentomaksilofasial Indonesia \(JRDI\) 9-14](#)

2023 DOI: 10.32793/jrdi.v7i1.951 Accred : Sinta 4

### [The correlation of the change in vertical angulation of the beam in the bisecting technique to the length of the tooth](#)

Ikatan Radiologi Kedokteran Gigi Indonesia [Jurnal Radiologi Dentomaksilofasial Indonesia \(JRDI\) Vol 7 No 1 \(2023\): Jurnal Radiologi Dentomaksilofasial Indonesia \(JRDI\) 15-20](#)

2023 DOI: 10.32793/jrdi.v7i1.978 Accred : Sinta 4

### [Non-syndromic multiple odontogenic keratocyst finding with Cone-beam Computed Tomography \(CBCT\): A rare case report](#)

Ikatan Radiologi Kedokteran Gigi Indonesia [Jurnal Radiologi Dentomaksilofasial Indonesia \(JRDI\) Vol 7 No 1 \(2023\): Jurnal Radiologi Dentomaksilofasial Indonesia \(JRDI\) 35-40](#)

2023 DOI: 10.32793/jrdi.v7i1.989 Accred : Sinta 4

### [Comparative analysis of impacted maxillary canine and dentigerous cyst diagnosis using panoramic and CBCT imaging](#)

Ikatan Radiologi Kedokteran Gigi Indonesia [Jurnal Radiologi Dentomaksilofasial Indonesia \(JRDI\) Vol 6 No 1 \(2022\): Jurnal Radiologi Dentomaksilofasial Indonesia \(JRDI\) 27-30](#)

2022 DOI: 10.32793/jrdi.v6i1.742 Accred : Sinta 4

### [Interprocessus distances based on gender using panoramic radiographs](#)

Ikatan Radiologi Kedokteran Gigi Indonesia [Jurnal Radiologi Dentomaksilofasial Indonesia \(JRDI\) Vol 6 No 1 \(2022\): Jurnal Radiologi Dentomaksilofasial Indonesia \(JRDI\) 13-16](#)

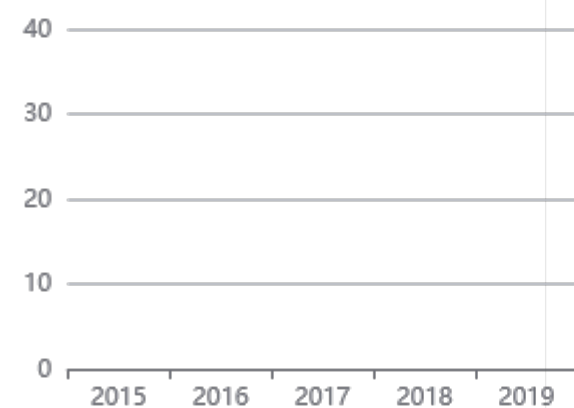
2022 DOI: 10.32793/jrdi.v6i1.748 Accred : Sinta 4

[View more ...](#)

Get More with  
SINTA Insight

[Go to Insight](#)

Citation Per Year By Google Scholar



Journal By Google Scholar

	All	Since 2018
Citation	115	115
h-index	6	6
i10-index	3	3



SCAN ME

# JADI

JURNAL RADIOLOGI DENTOMAKSILOFASIAL INDONESIA

Vol.7/No.1/April 2023



INDONESIAN  
DENTOMAXILLOFACIAL  
RADIOLOGY  
ASSOCIATION



[Announcements](#) [Current](#) [Archives](#) [About](#)

[Home](#) / [Editorial Team](#)

## EDITORIAL BOARD



**Haris Nasutianto, DDS, MSc, DMFR (Consultant), PhD** | *General Advisor*

Chairman of IKARGI (Ikatan Radiologi Kedokteran Gigi Indonesia / *Indonesian Dentomaxillofacial Radiology Association*) and current staff in Oral Radiology Department, Universitas Mahasaraswati, Denpasar, Indonesia.



**Azhari, DDS, MS, DMFR (Consultant), PhD** | *Editor-in-Chief*

Founder of JRDI and Associate Professor in the Department of Dentomaxillofacial Radiology, Universitas Padjadjaran, Bandung, Indonesia. His research projects are mainly focused on bone quality, bone microarchitecture, digital radiograph assessment, systemic disease and osteoporosis.









**Lusi Epsilawati, DDS, MSc, DMFR (Consultant)** | *Duty Editor*



Co-founder of JRDI and current staff in the Department of Dentomaxillofacial Radiology, Universitas Padjadjaran, Bandung, Indonesia. Systemic diseases, clinical radiopathology and imaging modalities become the most concerning topics in her previous and remaining research works.








## EDITORIAL MEMBERS




**Prof. Hanna H. Bachtiar Iskandar** | Universitas Indonesia, Jakarta, Indonesia |   




**Prof. Suhardjo Sitam** | Universitas Padjadjaran, Bandung, Indonesia |   




**Prof. Munakhir Mudjosemedi** | Universitas Gadjah Mada, Yogyakarta, Indonesia |  

**Prof. Barunawaty Yunus** | Universitas Hasanuddin, Makassar, Indonesia |  



**Prof. Trelia Boel** | Universitas Sumatra Utara, Medan, Indonesia |   


**Dr. Eha Renwi Astuti** | Universitas Airlangga, Surabaya, Indonesia |   

**Dr. Menik Priaminiarti** | Universitas Indonesia, Jakarta, Indonesia |   



**Farina Pramanik** | Universitas Padjadjaran, Bandung, Indonesia |   


## MANAGING EDITOR


**Aga Satria Nurrachman** | Universitas Airlangga, Surabaya, Indonesia |  

**Norlaila Sarifah** | Universitas Lambung Mangkurat, Banjarmasin, Indonesia | 

## PRODUCTION STAFF

**Rellyca Sola Gracea** | Universitas Gadjah Mada, Yogyakarta, Indonesia |  

**Merry Annisa Damayanti** | Universitas Padjadjaran, Bandung, Indonesia | 

**Fahri Reza Ramadhan** | Universitas Padjadjaran, Bandung, Indonesia | 

ONLINE SUBMISSION

FOCUS & SCOPE

EDITORIAL BOARD

PEER REVIEWER

AUTHOR GUIDELINES

AUTHOR FEES

REVIEW GUIDELINES

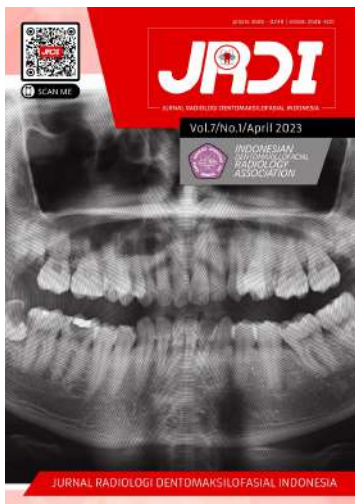
PUBLICATION ETHICS

PLAGIARISM POLICY

COPYRIGHT TRANSFER



MANUSCRIPT TEMPLATE

[Register](#) [Login](#)[Announcements](#) [Current](#) [Archives](#) [About](#)[Home](#) / [Archives](#) / Vol 7 No 1 (2023): Jurnal Radiologi Dentomaksilofasial Indonesia (JRDI)

Jurnal Radiologi Dentomaksilofasial Indonesia (JRDI), April 2023, Vol. 7, No. 1

**Published:** 2023-04-29

### [Table of Contents](#)



## Original Research Article

### [Diagnostic accuracy of periapical radiolucency using periapical radiography and cone-beam computed tomography](#)

I Putu Gede Andyka Yasa, Haris Nasutianto, Tomohiro Okano

1-8

 PDF

### **Third molar impaction prevalence and pattern: a panoramic radiography investigation**

Andi Nurul Azizah Tenrilili, Barunawaty Yunus, Fadhlil Ulum Abdul Rahman

9-14

 PDF

### **The correlation of the change in vertical angulation of the beam in the bisecting technique to the length of the tooth**

Kharidah Khairullah Nabihah, Muhammad Novo Perwira Lubis

15-20

 PDF

### **Variation of normal condyle shape based on gender in panoramic radiographs**

Sri Wigati Mardi Mulyani, Eha Renwi Astuti, Otty Ratna Wahyuni, Ramadhan Hardani Putra, Aga Satria Nurrachman, Nastiti Faradilla Ramadhani, Farah Tariza Harlens, Lailatul Hikmah Mazlan

21-26

 PDF

### **Panoramic radiograph measurement of upper mandibular ramus breadth for sex determination**

Dinda Priscilia Septiani, Rizki Tanjung, Intan Farizka

27-30

 PDF

## **Case Report**

### **Bilateral bifid condyle mandibula features in panoramic radiography: a case report**

Gunawan Gunawan, Ivony Fitria

31-34

 PDF

### **Non-syndromic multiple odontogenic keratocyst finding with Cone-beam Computed Tomography (CBCT): A rare case report**

Ichda Nabiela Amiria Asykarie, Farina Pramanik



35-40

 PDF

### **A suspect of large dentigerous cyst associated with impacted canine evaluated by CBCT: a case report in a young patient**

Galih Rahmadini, Fahri Reza Ramadhan, Aga Satria Nurrachman, Farina Pramanik

41-46

 PDF

**ONLINE SUBMISSION**

**FOCUS & SCOPE**

**EDITORIAL BOARD**

**PEER REVIEWER**

**AUTHOR GUIDELINES**

**AUTHOR FEES**

**REVIEW GUIDELINES**

**PUBLICATION ETHICS**

# PLAGIARISM POLICY

# COPYRIGHT TRANSFER



# MANUSCRIPT TEMPLATE



# The correlation of the change in vertical angulation of the beam in the bisecting technique to the length of the tooth

Kharidah Khairullah Nabihah<sup>1\*</sup>, Muhammad Novo Perwira Lubis<sup>2</sup>

## ABSTRACT

**Objectives:** To find out the correlation between changes in vertical angle beam in periapical radiography of bisecting techniques to the length dimension of the tooth.

**Materials and Methods:** This study was a study using laboratory experimental methods. The samples used in this study were incisor 1, incisor 2, canine, premolar 1, premolar 2, molar 1, and molar 2 region 1. Based on the results of the minimum number of samples at G\*power, measures of effect size f (0.4512937),  $\alpha$  err prob (0.05), power (1- $\beta$  err prob) (0.8), number of groups (5), number of measurements (2), corr among rep measurements (0.6), nonpersphericity correction  $\epsilon$  (1). All teeth are treated in the form of a change in angle from the standard angle recommended by White and Pharoah to -10°, -5°, 0°, +5°, +10°, +10° in each

tooth using the Dental X-ray unit of Veraview V080 type EX-2 70 kV. 7 mA.

**Results:** Based on Saphiro-Wilk, Kruskall-Wallis, and Paired t-test tests, it is known that there is a significant relationship between the actual length of the tooth and the length of the radiograph result in the change of angle + foreshortening, and the change of angle - the elongation. However, this does not apply to molar teeth 1 and 2 at positive angle changes However, this does not apply to molar teeth 1 and 2. A change in angle -10° is a change in angle with a better degree.

**Conclusion:** There is a correlation between the change in vertical angle beam in the periapical radiography of bisecting techniques to the length dimension of the tooth.

**Keywords:** Bisecting technique, vertical angulation, tooth length

**Cite this article:** Nabihah KK, Lubis MNP. *The correlation of the change in vertical angulation of the beam in the bisecting technique to the length of the tooth.* Jurnal Radiologi Dentomaksilofasial Indonesia 2023;7(1)15-20. <https://doi.org/10.32793/jrdi.v7i1.978>

## INTRODUCTION

Radiography is one part of the supporting examination.<sup>1</sup> The purpose of radiography is to produce high-quality images that can accurately show the anatomical structure of the teeth so that no distortion or enlargement occurs so that optimal results will be obtained. Radiography can be said to have optimal quality if it can provide clear and complete information to establish a diagnosis.<sup>2</sup> Intraoral radiography consists of 3 techniques, one of which is periapical radiography.<sup>3</sup> Periapical radiographs can show an overall picture of the teeth, surrounding bone tissue, less radiation exposure, and simpler techniques.<sup>4</sup> One of the periapical radiographs is the bisecting technique.<sup>1,5</sup>

The bisecting technique is a technique used when the ideal receptor cannot be achieved, generally in patients who have trauma, or anatomical obstructions. When performing the bisecting technique, the horizontal and vertical angles must be assessed to avoid errors.<sup>6,7</sup> There are two errors in performing the bisecting technique: errors in determining the vertical and horizontal angles. If there is an error in setting the

vertical and horizontal angles, it can cause distortion in the form of foreshortening and elongation of the teeth which will result in errors in measurement, such as during endodontic treatment which results in suboptimal treatment results.<sup>8</sup>

Based on research conducted by Anggara et al. in the study of the actual tooth length with the tooth length from the radiograph, the vertical angle beam was changed at angles of +20°, +30°, +40°, +50°, and +60°. According to the results of the study, the vertical angle change with an angle other than +40° for maxillary premolars will experience distortion because the incident direction of the beam does not perpendicularly intersect the plane of division between the film and the long axis of the tooth.<sup>9</sup>

The impact of errors made in the bisecting technique resulted in continuous image capture. Continuous repetition of radiographs does not coincide with the ALARA (As Low As Reasonably Achievable) principle, which is the use of the minimum possible dose to get maximum results.<sup>9</sup>



This work is licensed under a Creative Commons Attribution 4.0 which permits use, distribution and reproduction, provided that the original work is properly cited, the use is non-commercial and no modifications or adaptations are made.

<sup>1</sup>Faculty of Dentistry, Universitas Trisakti, Jakarta, Indonesia, 11410

<sup>2</sup>Departement of Dentomaxillofacial Radiology, Faculty of Dentistry, Universitas Trisakti, Jakarta, Indonesia, 11410

\*Correspondence to:  
Kharidah Khairullah Nabihah  
✉ [khoridahori@gmail.com](mailto:khoridahori@gmail.com)

Received on: February 2023  
Revised on: March 2023  
Accepted on: April 2023

This research is aimed to determine the relationship between changes in vertical angle beam in periapical radiography of bisecting techniques to the length dimension of the tooth.

## MATERIALS AND METHODS

This study was a study using laboratory experimental methods. The data obtained were primary data conducted at the Radiology Installation, Educational Dental and Oral Hospital, Faculty of Dentistry, Trisakti University which was conducted in September - November 2022.

The population used in this study is all maxillary dental elements, region one in the jaw model. The samples used in this study used teeth that had been implanted in the region 1 phantom, incisor 1, incisor 2, canine, premolar 1, premolar 2, molar 1, and molar 2.

The inclusion criteria in this study are having a crown that is still intact, if there are defects (abrasion, attrition, caries) it does not affect the vertical and horizontal dimensions of the tooth, the root is still intact and, the apical foramen is still good. The exclusion criteria in this study were crown fracture, and root fracture.

The tools used in this study are digital calipers, arcs, lecrons, wax knives, water passes, glass plates, white cloth mats, spiritus lamps, HP all-in-one 22-c0xx devices with a resolution of 1920 x 1080, dental X-ray unit Veraview V080 type EX-2 70 kV. 7mA. 2 sec, DBSWIN 5.11.0 software, microsoft excel software, dürr dental vistascan mini plus.

In this study, the teeth of incisor 1, incisor 2,

canine, premolar 1, premolar 2, molar 1 and molar 2 of region 1 were measured first using digital calipers vertically and horizontally to obtain the actual tooth length. After measurement, all teeth were planted using baseplate wax on the maxillary model by shaping according to the angulation in humans so that the position of the teeth in the phantom matches the original. Furthermore, radiographs were taken using the provisions of the standard angle of vertical angulation by White and Pharoah, all teeth were treated by changing the angle from the standard angle to  $-10^\circ$ ,  $-5^\circ$ ,  $0^\circ$ ,  $+5^\circ$ ,  $+10^\circ$  on each tooth using a Dental X-ray unit Veraview V080 type EX-2 70 kV. 7mA. The angle was changed to see if the change could cause distortion in the form of elongation, and foreshortening. The results of taking radiographs were observed and measured vertically and horizontally using DBSWIN 5.11.0 software. Data processing of this research used the SPSS program.

## RESULTS

In this study, all subjects were treated by taking radiography from the standard angle recommended by White and Pharoah to change angles of  $-10^\circ$ ,  $-5^\circ$ ,  $0^\circ$ ,  $+5^\circ$ ,  $+10^\circ$  with the results in Table 1. According to Table 1, it can be seen that the average length of the teeth of the radiograph given a negative angle change of  $-10$  and  $-5$  is elongated, and the positive angle changes of  $+10$  and  $+5$  are foreshortened. In incisor 1 to premolar 2 regions 1 there occurs foreshortening or what may be called tooth shortening. However, for positive angle changes of

**Table 1.** Research Results and Descriptive Statistics

Teeth	Angle Change				
	$-10^\circ$	$-5^\circ$	$0^\circ$	$+5^\circ$	$+10^\circ$
Incisor 1	30,7mm (Elongation 6,5%)	26,8mm (Elongation 2,6%)	23,1mm (Foreshortening 1,1%)	19,4mm (Foreshortening 4,8%)	18,2mm (Foreshortening 6%)
Incisor 2	29,4mm (Elongation 4,7%)	26,8mm (Elongation 2,1%)	24,9mm (Elongation 0,2%)	23,0mm (Foreshortening 1,7%)	21,3mm (Foreshortening 3,4%)
Canine	28,0mm (Elongation 2,4%)	26,4mm (Elongation 0,8%)	25,8mm (Elongation 0,2%)	24,9mm (Foreshortening 0,7%)	24,0mm (Foreshortening 1,6%)
Premolar 1	30,4mm (Elongation 7,3%)	26,7mm (Elongation 3,6%)	23,6mm (Elongation 0,5%)	22,9mm (Foreshortening 0,2%)	21,1mm (Foreshortening 2%)
Premolar 2	24,5mm (Elongation 2,6%)	23,0mm (Elongation 2,1%)	20,6mm (Foreshortening 0,3%)	18,7mm (Foreshortening 2,2%)	18,2mm (Foreshortening 2,7%)
Molar 1	28,0mm (Elongation 6,1%)	26,4mm (Elongation 4,5%)	25,6mm (Elongation 3,7%)	25,2mm (Elongation 3,3%)	25,0mm (Elongation 3,1%)
Molar 2	24,6mm (Elongation 5,4%)	22,8mm (Elongation 3,6%)	22,4mm (Elongation 3,2%)	21,9mm (Elongation 2,7%)	21,8mm (Elongation 2,6%)
Average	27,9mm	25,6mm	23,7mm	22,3mm	21,4mm
Medians	28,0mm	26,4mm	23,6mm	22,9mm	21,3mm
Standar Deviations	2,5mm	1,8mm	1,9mm	2,5mm	2,6mm

**Table 2.** Result Of Data Normality Test With Saphiro Wilk Method

	Shapiro-Wilk			Description
	Statistic	df	Sig.	
A Change Of Angle -10°	0.873	7	0.195	Normally Distributed
A Change Of Angle -5°	0.681	7	0.002	Not Normally Distributed
A Change Of Angle 0°	0.943	7	0.667	Normally Distributed
A Change Of Angle +5°	0.918	7	0.456	Normally Distributed
A Change Of Angle +10°	0.918	7	0.453	Normally Distributed

**Table 3.** Kruskal Wallis Test Data for Dental Length Measurement

Chi-Square	df	Sig.	Description
17,727	4	0,001	Significant Difference

**Table 4.** Paired t-Test

Paired Samples Statistics				
Pair	Mean	N	Std. Deviation	Std. Error Mean
-10°	27.9 mm	7	2.5 mm	0.000211
-5°	25.6 mm	7	1.8 mm	0.001055
0°	23.7 mm	7	1.9 mm	0.230392
+5°	22.3 mm	7	2.5 mm	0.6462523
+10°	21.4 mm	7	2.6 mm	0.289411

**Table 5.** Results of taking radiographs with a change in vertical irradiation angle of 0°

Teeth	Results
Incisor 1	<i>Foreshortening</i> 1,1%
Incisor 2	Elongation 0,2%
Canine	Elongation 0,2%
Premolar 1	Elongation 0,5%
Premolar 2	<i>Foreshortening</i> 0,3%
Molar 1	Elongation 3,7%
Molar 2	Elongation 3,2%

**Table 6.** Results of taking radiographs with a change in vertical irradiation angle of -10°

Teeth	Results
Incisor 1	Elongation 6,5%
Incisor 2	Elongation 4,7%
Canine	Elongation 2,4%
Premolar 1	Elongation 7,3%
Premolar 2	Elongation 2,6%
Molar 1	Elongation 6,1%
Molar 2	Elongation 5,4%

**Table 7.** Results of taking radiographs with a change in vertical irradiation angle of  $-5^{\circ}$ 

Teeth	Results
Incisor 1	Elongation 2,6 %
Incisor 2	Elongation 2,1%
Canine	Elongation 0,8%
Premolar 1	Elongation 3,6%
Premolar 2	Elongation 2,1%
Molar 1	Elongation 4,5%
Molar 2	Elongation 3,6%

**Table 8.** Results of taking radiographs with a change in vertical irradiation angle of  $+10^{\circ}$ 

Teeth	Results
Insisor 1	<i>Foreshortening</i> 6%
Incisor 2	<i>Foreshortening</i> 3,4%
Canine	<i>Foreshortening</i> 1,6%
Premolar 1	<i>Foreshortening</i> 2%
Premolar 2	<i>Foreshortening</i> 2,7%
Molar 1	Elongation 3,1%
Molar 2	Elongation 2,6%

**Table 9.** Results of taking radiographs with a change in vertical irradiation angle of  $+5^{\circ}$ 

Teeth	Results
Incisor 1	<i>Foreshortening</i> 4,8%
Incisor 2	<i>Foreshortening</i> 1,7%
Canine	<i>Foreshortening</i> 0,7%
Premolar 1	<i>Foreshortening</i> 0,2%
Premolar 2	<i>Foreshortening</i> 2,2%
Molar 1	Elongation 3,3%
Molar 2	Elongation 2,7%

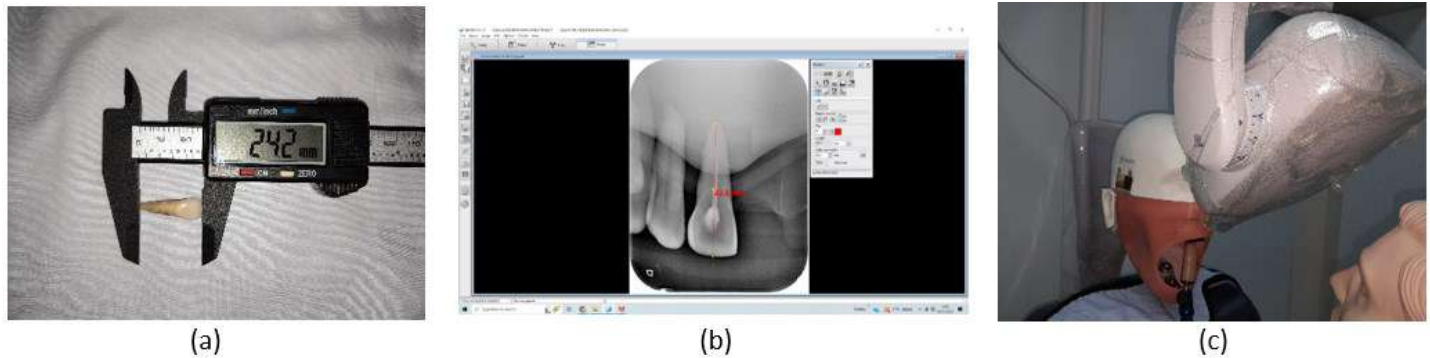
+10 and +5 in molar teeth 1 and molar 2 there is an increase in the size of the teeth of the actual length of the teeth which is elongation or commonly called tooth extension.

Data analysis is performed using a data normality test, which is the Shapiro-Wilk test because the number of samples is less than 50 data. In Table 2, it was found that not all data groups produced p-values greater than 0.05. This means that not all data is normally distributed.

Further comparison is performed using the Kruskal-Wallis method, and it can be seen that the resulting p-value is 0.001 which is less than the error rate of 5% or 0.05. This means that the

angular changes of  $-10^{\circ}$ ,  $-5^{\circ}$ ,  $0^{\circ}$ ,  $+5^{\circ}$ , and  $+10^{\circ}$  give significant differences in the length of the tooth.

After a comparison test is performed, a paired t-test is performed to see the mean difference in each variable from the change in vertical angle beam to the length of the tooth. According to Table 4, the mean at the change of angle  $-10^{\circ}$  is greater than the mean at the change of angle  $-5^{\circ}$ ,  $0^{\circ}$ ,  $+5^{\circ}$ , and  $+10^{\circ}$ . Thus, it can be concluded that the change of angle  $-10^{\circ}$  is a change of angle with a better degree than the change of angles  $-5^{\circ}$ ,  $0^{\circ}$ ,  $+5^{\circ}$ , and  $+10^{\circ}$ .



**Figure 1.** Research process on incisor 1 (a). Measurement of actual tooth length (b). Radiograph of angle change 0° and measurement of radiograph (c). X-ray tube alignment

## DISCUSSION

The result of a 0° angle change to the length of the tooth is actually a reduction and an increase in the size of the tooth in the radiograph image. The results of the 0° angle change can be seen in Table 5. Thus it can be said that with the angle recommended by White and Pharoah without modification, there is a discrepancy between the original tooth and the radiograph image on the inclination and angulation of the standard arrangement of teeth.

The results of measurements on all teeth of a change in vertical angle beam of -10° result in radiographic removal of teeth or elongation. The results of the -10° angle change can be seen in Table 6. The results of measurements on all teeth of a change in vertical angle beam of -5° result in radiographic extraction of the tooth extension or what can be called elongation. The results of the -5° angle change can be seen in Table 7. The results of measurements on all teeth of a change in vertical angle beam of +10° result in radiographic shortening of the teeth or foreshortening. The results of the +10° angle change can be seen in Table 8. The results of measurements on all teeth of a change in vertical angle beam +5° result in radiographic shortening or foreshortening. The results of the +5° angle change can be seen in Table 9. Based on these results, it can be said that the standard angle of vertical angulation by White and Pharoah has similarities to that of human angulation by Zarc Boucher.

At positive vertical angle beam changes the result of radiography shortens the teeth or foreshortening, but only applies to incisors teeth up to premolar 2 and does not apply to molar teeth 1 and molar teeth 2, as the change in vertical angle beam + to molar teeth results in the radiographic result being elongated. This difference can be said that there is a direct relationship, that the larger the light was given to the molar tooth, the greater the elongation or extension of the tooth. Thus, White and Pharoah's theory did not apply to this study, namely, the change in the angle of positive vertical angle beam in molar teeth 1 and molar 2 teeth.

This can be caused by several factors such as, a) At the palatal root length of the molar tooth in this

study, if the direction of the X-ray beam is not perpendicular to the long axis of the tooth, the appearance of the radiographic results of the tooth root will be distorted, the elongation of the root length in the palatal part of the upper molar tooth so that the inclination of the tooth root affects the elongation; b) In this study using a jaw model with limited area and width of the jaw model. Another possibility can occur if the X-ray is oriented perpendicular to the object but not to the image receptor; c) In this study using a jaw model with limitations on the width and width of the jaw model is different from the width and width conditions in the human oral cavity so that it affects the results of the angle change; d) At the time of the study, no specialized tools were used for the radiography of the tooth root. A special tool was not used to ensure that the position of the X-ray tube was upright so that there might be bias in measurement and recording by the operator either in placing the film position, jaw model position, X-ray tube position so that it could result in bias in the final measurement value.<sup>10</sup>

In research conducted by Anggara et al (2018), at changes in vertical angle beam of +20°, +30°, +40°, +50° and +60° on maxillary premolars 1, changes in vertical angle beam of +30 produce tolerable tooth lengths of less than 1 mm.<sup>9</sup> In Dita Cynthia's research (2021), a change in the vertical angle beam of +30° on the maxillary premolar 1 and premolar 2 teeth resulted in a tolerable tooth length because the tooth length was less than 1 mm.<sup>11</sup>

This study uses digital radiography with photostimulable phosphor receptors. These receptors have greater sensitivity, quality and versatility compared to conventional film.<sup>12</sup> In digital radiography, the image can be enhanced by adjusting the contrast of the image, unlike conventional film which cannot be manipulated or enhanced.<sup>13,14</sup>

Errors when taking radiographs will cause the results of taking radiographs to be incorrect and will result in errors in diagnosis and treatment plans. If there is an error when determining the vertical angulation, the radiograph results will be difficult to interpretation. Both errors in determining the vertical angulation angle, elongation and foreshortening, will result in errors when performing endodontic measures related to the

root apex. As a result, any decision to adjust the working length may pose a risk of apex perforation especially if this is done by an inexperienced dentist.<sup>15</sup>

## CONCLUSION

Based on the results of this study, there is a correlation between the change in vertical angle beam in the periapical radiography of bisecting techniques to the length dimension of the tooth. For further research, it can be done using mandibular teeth so as to get maximum results and more varied angle changes are made to get accurate results.

## ACKNOWLEDGMENTS

None.

## FOOTNOTES

All authors have no potential conflict of interest to declare for this article. This study has received ethical approval by the Research Ethics Commission of the Faculty of Dentistry, Trisakti University with number 614/S1/KEPK/FKG/8/2022. All procedures conducted were in accordance with the ethical standards.

## REFERENCES

- Desyaningrum H, Epsilawati L, Rusyandi Y. Karakteristik kerusakan tulang alveolar pada penderita periodontitis kronis dan agresif dengan pencitraan Cone Beam Computed Tomography. *Padjadjaran J Dent Res Students*. 2017;1(1):139-44.
- Carestream Dental. Dental Radiography Series. Carestream Health, Inc. 2016 [Cited on 2022]. Accessed on [https://www.carestream.com/en/us/-/media/publicsite/products\\_and\\_solutions/dental/pdf/8170\\_us\\_exposure\\_processing\\_broch.pdf?sc\\_lang=en](https://www.carestream.com/en/us/-/media/publicsite/products_and_solutions/dental/pdf/8170_us_exposure_processing_broch.pdf?sc_lang=en)
- Dayo AF, Wolff MS, Syed AZ, Mupparapu M. Radiology of Dental Caries. *Dent Clin North Am*. 2021;65(3):428-30.
- Kusumawati KY, Yanuarieska RD. The accuracy of extraoral periapical radiography on determining the working length in endodontic treatment : narrative review. 2022;6(1):41-8.
- Ramadhan AZ, Sitam S, Azhari A, Epsilawati L. Gambaran kualitas dan mutu radiograf. *J Radiol Dentomaksilofasial Indones*. 2020;3(3):43-8.
- Gupta A, Devi P, Srivastava R, Jyoti B. Intra oral periapical radiography - basics yet intrigue: A review. *Bangladesh J Dent Res Educ*. 2014;4(2):83-7.
- Whaites E, Drage N. *Essentials of Dental Radiography and Radiology*. 6th ed. Elsevier Health Sciences; 2020. p.117.
- Williamson GF. *Intraoral Radiography: Positioning and Radiation Protection*. ADA CERP; 2006.
- Anggara A, Iswani R, Darmawangsa D. Perubahan Sudut Penyinaran Vertikal pada Bisecting Technique Radiography Terhadap Keakuratan Dimensi Panjang Gigi Premolar Satu Atas. *J B-Dent*. 2018;5(1):1-8.
- White SC, Pharoah MJ. *Oral Radiography Principles and Interpretation*. 7th ed. Amsterdam: Elsevier; 2014. p.91-113.
- Cynthia D. Gambaran Rata-Rata Panjang Gigi Premolar Rahang Atas dan Rahang Bawah Menggunakan Radiografi Periapikal Digital Antara Teknik Paraleling dan Bisecting ( Penelitian In Vitro ). Skripsi. Universitas Sumatera Utara. 2021. p.31.
- Vasconcelos K de F, Rovaris K, Nascimento EHL, Oliveira ML, Távora D de M, Bóscolo FN. Diagnostic accuracy of phosphor plate systems and conventional radiography in the detection of simulated internal root resorption. *Acta Odontol Scand*. 2017;75(8):573-6.
- Yoon DC, Mol A, Benn DK, Benavides E. Digital Radiographic Image Processing and Analysis. *Dent Clin North Am*. 2018;62(3):341-59.
- Takehita WM, Iwaki LCV, Da Silva MC, Tonin RH. Evaluation of diagnostic accuracy of conventional and digital periapical radiography, panoramic radiography, and cone-beam computed tomography in the assessment of alveolar bone loss. *Contemp Clin Dent*. 2014;5(3):318-23.
- Yueniwati Y, Rachmawati YL, Prismahany IP. Apical Cuts off as the Highest Prevalence of Errors during the Process of Periapical Radiograph Bisecting Technique by Dentistry Students. *Indones Med Life Sci J*. 2021;1(1):8-14.



# The correlation of the change in vertical angulation of the beam in the bisecting technique to the length of the tooth

*by* M Novo Perwira Lubis FKG

---

**Submission date:** 04-Dec-2023 01:51PM (UTC+0700)

**Submission ID:** 2247169964

**File name:** e\_beam\_in\_the\_bisecting\_technique\_to\_the\_length\_of\_the\_tooth.pdf (483.62K)

**Word count:** 3662

**Character count:** 18229

<http://jurnal.pdgi.ac.id/index.php/jrdi/index>

# The correlation of the change in vertical angulation of the beam in the bisecting technique to the length of the tooth

Kharidah Khairullah Nabihah<sup>1\*</sup>, Muhammad Novo Perwira Lubis<sup>2</sup>

## ABSTRACT

**Objectives:** To find out the correlation between changes in vertical angle beam in periapical radiography of bisecting techniques to the length dimension of the tooth.

**Materials and Methods:** This study was a study using laboratory experimental methods. The samples used in this study were incisor 1, incisor 2, canine, premolar 1, premolar 2, molar 1, and molar 2 region 1. Based on the results of the minimum number of samples at G\*power, measures of effect size f (0.4512937),  $\alpha$  err prob (0.05), power (1- $\beta$  err prob) (0.8), number of groups (5), number of measurements (2), corr among rep measurements (0.6), nonpersphericity correction  $\epsilon$  ( 1). All teeth are treated in the form of a change in angle from the standard angle recommended by White and Pharoah to -10°, -5°, 0°, +5°, +10°, +10° in each

tooth using the Dental X-ray unit of Veraview V080 type EX-2 70 kV. 7 mA.

**Results:** Based on Saphiro-Wilk, Kruskal-Wallis, and Paired t-test tests, it is known that there is a significant relationship between the actual length of the tooth and the length of the radiograph result in the change of angle + foreshortening, and the change of angle - the elongation. However, this does not apply to molar teeth 1 and 2 at positive angle changes However, this does not apply to molar teeth 1 and 2. A change in angle -10° is a change in angle with a better degree.

**Conclusion:** There is a correlation between the change in vertical angle beam in the periapical radiography of bisecting techniques to the length dimension of the tooth.

**Keywords:** Bisecting technique, vertical angulation, tooth length

**Cite this article:** Nabihah KK, Lubis MNP. The correlation of the change in vertical angulation of the beam in the bisecting technique to the length of the tooth. Jurnal Radiologi Dentomaksilofasial Indonesia 2023;7(1)15-20. <https://doi.org/10.32793/jrdi.v7i1.978>

## INTRODUCTION

Radiography is one part of the supporting examination.<sup>1</sup> The purpose of radiography is to produce high-quality images that can accurately show the anatomical structure of the teeth so that no distortion or enlargement occurs so that optimal results will be obtained. Radiography can be said to have optimal quality if it can provide clear and complete information to establish a diagnosis.<sup>2</sup> Intraoral radiography consists of 3 techniques, one of which is periapical radiography.<sup>3</sup> Periapical radiographs can show an overall picture of the teeth, surrounding bone tissue, less radiation exposure, and simpler techniques.<sup>4</sup> One of the periapical radiographs is the bisecting technique.<sup>1,5</sup>

The bisecting technique is a technique used when the ideal receptor cannot be achieved, generally in patients who have trauma, or anatomical obstructions. When performing the bisecting technique, the horizontal and vertical angles must be assessed to avoid errors.<sup>5,7</sup> There are two errors in performing the bisecting technique: errors in determining the vertical and horizontal angles. If there is an error in setting the

vertical and horizontal angles, it can cause distortion in the form of foreshortening and elongation of the teeth which will result in errors in measurement, such as during endodontic treatment which results in suboptimal treatment results.<sup>8</sup>

Based on research conducted by Anggara et al. in the study of the actual tooth length with the tooth length from the radiograph, the vertical angle beam was changed at angles of +20°, +30°, +40°, +50°, and +60°. According to the results of the study, the vertical angle change with an angle other than +40° for maxillary premolars will experience distortion because the incident direction of the beam does not perpendicularly intersect the plane of division between the film and the long axis of the tooth.<sup>9</sup>

The impact of errors made in the bisecting technique resulted in continuous image capture. Continuous repetition of radiographs does not coincide with the ALARA (As Low As Reasonably Achievable) principle, which is the use of the minimum possible dose to get maximum results.<sup>9</sup>



This work is licensed under a Creative Commons Attribution 4.0 International License, which permits use, distribution and reproduction in any medium or format, as long as you give appropriate credit to the original author(s) and the source, provide a link to the Creative Commons licence, and indicate if changes were made.

<sup>1</sup> Faculty of Dentistry, Universitas Trisakti, Jakarta, Indonesia, 11410

<sup>2</sup> Departement of Dentomaxillofacial Radiology, Faculty of Dentistry, Universitas Trisakti, Jakarta, Indonesia, 11410

\* Correspondence to:  
Kharidah Khairullah Nabihah  
✉ [kharidahori@gmail.com](mailto:kharidahori@gmail.com)

Received on: February 2023

Revised on: March 2023

Accepted on: April 2023

This research is aimed to determine the relationship between changes in vertical angle beam in periapical radiography of bisecting techniques to the length dimension of the tooth.

## MATERIALS AND METHODS

This study was a study using laboratory experimental methods. The data obtained were primary data conducted at the Radiology Installation, Educational Dental and Oral Hospital, Faculty of Dentistry, Trisakti University which was conducted in September - November 2022.

The population used in this study is all maxillary dental elements, region one in the jaw model. The samples used in this study used teeth that had been implanted in the region 1 phantom, incisor 1, incisor 2, canine, premolar 1, premolar 2, molar 1, and molar 2.

The inclusion criteria in this study are having a crown that is still intact, if there are defects (abrasion, attrition, caries) it does not affect the vertical and horizontal dimensions of the tooth, the root is still intact and, the apical foramen is still good. The exclusion criteria in this study were crown fracture, and root fracture.

The tools used in this study are digital calipers, arcs, lecrons, wax knives, water passes, glass plates, white cloth mats, spiritus lamps, HP all-in-one 22-c0xx devices with a resolution of 1920 x 1080, dental X-ray unit Veraview V080 type EX-2 70 kV. 7mA. 2 sec, DBSWIN 5.11.0 software, microsoft excel software, dürr dental vistascan mini plus.

In this study, the teeth of incisor 1, incisor 2,

canine, premolar 1, premolar 2, molar 1 and molar 2 of region 1 were measured first using digital calipers vertically and horizontally to obtain the actual tooth length. After measurement, all teeth were planted using baseplate wax on the maxillary model by shaping according to the angulation in humans so that the position of the teeth in the phantom matches the original. Furthermore, radiographs were taken using the provisions of the standard angle of vertical angulation by White and Pharoah, all teeth were treated by changing the angle from the standard angle to -10°, -5°, 0°, +5°, +10° on each tooth using a Dental X-ray unit Veraview V080 type EX-2 70 kV. 7mA. The angle was changed to see if the change could cause distortion in the form of elongation, and foreshortening. The results of taking radiographs were observed and measured vertically and horizontally using DBSWIN 5.11.0 software. Data processing of this research used the SPSS program.

## RESULTS

In this study, all subjects were treated by taking radiography from the standard angle recommended by White and Pharoah to change angles of -10°, -5°, 0°, +5°, +10° with the results in Table 1. According to Table 1, it can be seen that the average length of the teeth of the radiograph given a negative angle change of -10 and -5 is elongated, and the positive angle changes of +10 and +5 are foreshortened. In incisor 1 to premolar 2 regions 1 there occurs foreshortening or what may be called tooth shortening. However, for positive angle changes of

Table 1. Research Results and Descriptive Statistics

Teeth	Angle Change				
	-10°	-5°	0°	+5°	+10°
Incisor 1	30,7mm (Elongation 6,5%)	26,8mm (Elongation 2,6%)	23,1mm (Foreshortening 1,1%)	19,4mm (Foreshortening 4,8%)	18,2mm (Foreshortening 6%)
Incisor 2	29,4mm (Elongation 4,7%)	26,8mm (Elongation 2,1%)	24,9mm (Elongation 0,2%)	23,0mm (Foreshortening 1,7%)	21,3mm (Foreshortening 3,4%)
Canine	28,0mm (Elongation 2,4%)	26,4mm (Elongation 0,8%)	25,8mm (Elongation 0,2%)	24,9mm (Foreshortening 0,7%)	24,0mm (Foreshortening 1,6%)
Premolar 1	30,4mm (Elongation 7,3%)	26,7mm (Elongation 3,6%)	23,5mm (Elongation 0,5%)	22,9mm (Foreshortening 0,2%)	21,1mm (Foreshortening 2%)
Premolar 2	24,5mm (Elongation 2,6%)	23,0mm (Elongation 2,1%)	20,6mm (Foreshortening 0,3%)	18,7mm (Foreshortening 2,2%)	18,2mm (Foreshortening 2,7%)
Molar 1	28,0mm (Elongation 6,1%)	26,4mm (Elongation 4,5%)	25,6mm (Elongation 3,7%)	25,2mm (Elongation 3,3%)	25,0mm (Elongation 3,1%)
Molar 2	24,6mm (Elongation 5,4%)	22,8mm (Elongation 3,6%)	22,4mm (Elongation 3,2%)	21,9mm (Elongation 2,7%)	21,8mm (Elongation 2,6%)
Average	27,9mm	25,6mm	23,7mm	22,3mm	21,4mm
Medians	28,0mm	26,4mm	23,6mm	22,9mm	21,3mm
Standar Deviations	2,5mm	1,8mm	1,9mm	2,5mm	2,6mm

**Table 2.** Result Of Data Normalty Test With Saphiro Wilk Method

	Shapiro-Wilk			Description
	Statistic	df	Sig.	
A Change Of Angle -10°	0.873	7	0.195	Normally Distributed
A Change Of Angle -5°	0.681	7	0.002	Not Normally Distributed
A Change Of Angle 0°	0.943	7	0.667	Normally Distributed
A Change Of Angle +5°	0.918	7	0.456	Normally Distributed
A Change Of Angle +10°	0.918	7	0.453	Normally Distributed

**Table 3.** Kruskal Wallis Test Data for Dental Length Measurement

Chi-Square	df	Sig.	Description
17,727	4	0,001	Significant Difference

**Table 4.** Paired t-Test

Pair	Paired Samples Statistics			
	Mean	N	Std. Deviation	Std. Error Mean
-10°	27.9 mm	7	2.5 mm	0.000211
-5°	25.6 mm	7	1.8 mm	0.001055
0°	23.7 mm	7	1.9 mm	0.230392
+5°	22.3 mm	7	2.5 mm	0.6462523
+10°	21.4 mm	7	2.6 mm	0.289411

**Table 5.** Results of taking radiographs with a change in vertical irradiation angle of 0°

Teeth	Results
Incisor 1	Foreshortening 1,1%
Incisor 2	Elongation 0,2%
Canine	Elongation 0,2%
Premolar 1	Elongation 0,5%
Premolar 2	Foreshortening 0,3%
Molar 1	Elongation 3,7%
Molar 2	Elongation 3,2%

**Table 6.** Results of taking radiographs with a change in vertical irradiation angle of -10°

Teeth	Results
Incisor 1	Elongation 6,5%
Incisor 2	Elongation 4,7%
Canine	Elongation 2,4%
Premolar 1	Elongation 7,3%
Premolar 2	Elongation 2,6%
Molar 1	Elongation 6,1%
Molar 2	Elongation 5,4%

**Table 7.** Results of taking radiographs with a change in vertical irradiation angle of  $-5^{\circ}$ 

Teeth	Results
Incisor 1	Elongation 2,6 %
Incisor 2	Elongation 2,1%
Canine	Elongation 0,8%
Premolar 1	Elongation 3,6%
Premolar 2	Elongation 2,1%
Molar 1	Elongation 4,5%
Molar 2	Elongation 3,6%

**Table 8.** Results of taking radiographs with a change in vertical irradiation angle of  $+10^{\circ}$ 

Teeth	Results
Insisor 1	<i>Foreshortening</i> 6%
Incisor 2	<i>Foreshortening</i> 3,4%
Canine	<i>Foreshortening</i> 1,6%
Premolar 1	<i>Foreshortening</i> 2%
Premolar 2	<i>Foreshortening</i> 2,7%
Molar 1	Elongation 3,1%
Molar 2	Elongation 2,6%

**Table 9.** Results of taking radiographs with a change in vertical irradiation angle of  $+5^{\circ}$ 

Teeth	Results
Incisor 1	<i>Foreshortening</i> 4,8%
Incisor 2	<i>Foreshortening</i> 1,7%
Canine	<i>Foreshortening</i> 0,7%
Premolar 1	<i>Foreshortening</i> 0,2%
Premolar 2	<i>Foreshortening</i> 2,2%
Molar 1	Elongation 3,3%
Molar 2	Elongation 2,7%

+10 and +5 in molar teeth 1 and molar 2 there is an increase in the size of the teeth of the actual length of the teeth which is elongation or commonly called tooth extension.

Data analysis is performed using a data normality test, which is the Shapiro-Wilk test because the number of samples is less than 50 data. In Table 2, it was found that not all data groups produced p-values greater than 0.05. This means that not all data is normally distributed.

Further comparison is performed using the Kruskal-Wallis method, and it can be seen that the resulting p-value is 0.001 which is less than the error rate of 5% or 0.05. This means that the

angular changes of  $-10^{\circ}$ ,  $-5^{\circ}$ ,  $0^{\circ}$ ,  $+5^{\circ}$ , and  $+10^{\circ}$  give significant differences in the length of the tooth.

After a comparison test is performed, a paired t-test is performed to see the mean difference in each variable from the change in vertical angle beam to the length of the tooth. According to Table 4, the mean at the change of angle  $-10^{\circ}$  is greater than the mean at the change of angle  $-5^{\circ}$ ,  $0^{\circ}$ ,  $+5^{\circ}$ , and  $+10^{\circ}$ . Thus, it can be concluded that the change of angle  $-10^{\circ}$  is a change of angle with a better degree than the change of angles  $-5^{\circ}$ ,  $0^{\circ}$ ,  $+5^{\circ}$ , and  $+10^{\circ}$ .

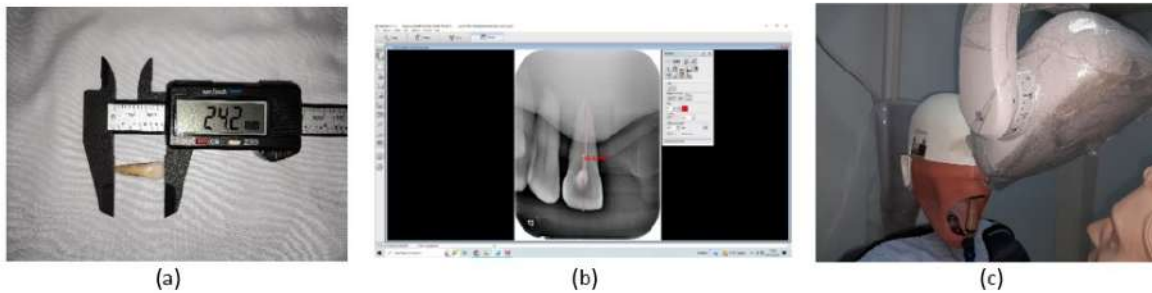


Figure 1. Research process on incisor 1 (a). Measurement of actual tooth length (b). Radiograph of angle change 0° and measurement of radiograph (c). X-ray tube alignment

## DISCUSSION

The result of a 0° angle change to the length of the tooth is actually a reduction and an increase in the size of the tooth in the radiograph image. The results of the 0° angle change can be seen in Table 5. Thus it can be said that with the angle recommended by White and Pharoah without modification, there is a discrepancy between the original tooth and the radiograph image on the inclination and angulation of the standard arrangement of teeth.

The results of measurements on all teeth of a change in vertical angle beam of -10° result in radiographic removal of teeth or elongation. The results of the -10° angle change can be seen in Table 6. The results of measurements on all teeth of a change in vertical angle beam of -5° result in radiographic extraction of the tooth extension or what can be called elongation. The results of the -5° angle change can be seen in Table 7. The results of measurements on all teeth of a change in vertical angle beam of +10° result in radiographic shortening of the teeth or foreshortening. The results of the +10° angle change can be seen in Table 8. The results of measurements on all teeth of a change in vertical angle beam +5° result in radiographic shortening or foreshortening. The results of the +5° angle change can be seen in Table 9. Based on these results, it can be said that the standard angle of vertical angulation by White and Pharoah has similarities to that of human angulation by Zarc Boucher.

At positive vertical angle beam changes the result of radiography shortens the teeth or foreshortening, but only applies to incisors teeth up to premolar 2 and does not apply to molar teeth 1 and molar teeth 2, as the change in vertical angle beam + to molar teeth results in the radiographic result being elongated. This difference can be said that there is a direct relationship, that the larger the light was given to the molar tooth, the greater the elongation or extension of the tooth. Thus, White and Pharoah's theory did not apply to this study, namely, the change in the angle of positive vertical angle beam in molar teeth 1 and molar 2 teeth.

This can be caused by several factors such as, a) At the palatal root length of the molar tooth in this

study, if the direction of the X-ray beam is not perpendicular to the long axis of the tooth, the appearance of the radiographic results of the tooth root will be distorted, the elongation of the root length in the palatal part of the upper molar tooth so that the inclination of the tooth root affects the elongation; b) In this study using a jaw model with limited area and width of the jaw model. Another possibility can occur if the X-ray is oriented perpendicular to the object but not to the image receptor; c) In this study using a jaw model with limitations on the width and width conditions in the human oral cavity so that it affects the results of the angle change; d) At the time of the study, no specialized tools were used for the radiography of the tooth root. A special tool was not used to ensure that the position of the X-ray tube was upright so that there might be bias in measurement and recording by the operator either in placing the film position, jaw model position, X-ray tube position so that it could result in bias in the final measurement value.<sup>10</sup>

In research conducted by Anggara et al (2018), at changes in vertical angle beam of +20°, +30°, +40°, +50° and +60° on maxillary premolars 1, changes in vertical angle beam of +30 produce tolerable tooth lengths of less than 1 mm.<sup>9</sup> In Dita Cynthia's research (2021), a change in the vertical angle beam of +30° on the maxillary premolar 1 and premolar 2 teeth resulted in a tolerable tooth length because the tooth length was less than 1 mm.<sup>11</sup>

This study uses digital radiography with photostimulable phosphor receptors. These receptors have greater sensitivity, quality and versatility compared to conventional film.<sup>12</sup> In digital radiography, the image can be enhanced by adjusting the contrast of the image, unlike conventional film which cannot be manipulated or enhanced.<sup>13,14</sup>

Errors when taking radiographs will cause the results of taking radiographs to be incorrect and will result in errors in diagnosis and treatment plans. If there is an error when determining the vertical angulation, the radiograph results will be difficult to interpretation. Both errors in determining the vertical angulation angle, elongation and foreshortening, will result in errors when performing endodontic measures related to the

root apex. As a result, any decision to adjust the working length may pose a risk of apex perforation especially if this is done by an inexperienced dentist.<sup>15</sup>

## CONCLUSION

Based on the results of this study, there is a correlation between the change in vertical angle beam in the periapical radiography of bisecting techniques to the length dimension of the tooth. For further research, it can be done using mandibular teeth so as to get maximum results and more varied angle changes are made to get accurate results.

## ACKNOWLEDGMENTS

None.

## FOOTNOTES

<sup>1</sup> All authors have no potential conflict of interest to declare for this article. This study has received ethical approval by the Research Ethics Commission of the Faculty of Dentistry, Trisakti University with number 614/S1/KEPK/FKG/8/2022. All procedures conducted were in accordance with the ethical standards.

## REFERENCES

- Desyaningrum H, Epsilawati L, Rusyandi Y. Karakteristik kerusakan tulang alveolar pada penderita periodontitis kronis dan agresif dengan pencitraan Cone Beam Computed Tomography. *Padjadjaran J Dent Res Students*. 2017;1(1):139-44.
- Carestream Dental. Dental Radiography Series. Carestream Health, Inc. 2016 [Cited on 2022]. Accessed on [https://www.carestream.com/en/us/-/media/publicsite/products\\_and\\_solutions/dental/pdf/8170\\_us\\_exposure\\_processing\\_broch.pdf?cc\\_lang=en](https://www.carestream.com/en/us/-/media/publicsite/products_and_solutions/dental/pdf/8170_us_exposure_processing_broch.pdf?cc_lang=en)
- Dayo AF, Wolff MS, Syed AZ, Mupparapu M. Radiology of Dental Caries. *Dent Clin North Am*. 2021;65(3):428-30.
- Kusumawati KY, Yanuaryska RD. The accuracy of extraoral periapical radiography on determining the working length in endodontic treatment : narrative review. 2022;6(1).41-8.
- Ramadhan AZ, Sitam S, Azhari A, Epsilawati L. Gambaran kualitas dan mutu radiograf. *J Radiol Dentomaksilofasial Indones*. 2020;3(3):43-8.
- Gupta A, Devi P, Srivastava R, Jyoti B. Intra oral periapical radiography - basics yet intrigue: A review. *Bangladesh J Dent Res Educ*. 2014;4(2):83-7.
- Whaites E, Drage N. *Essentials of Dental Radiography and Radiology*. 6th ed. Elsevier Health Sciences; 2020. p.117.
- Williamson GF. *Intraoral Radiography: Positioning and Radiation Protection*. ADA CERP; 2006.
- Anggara A, Iswani R, Darmawangsa D. Perubahan Sudut Penyinaran Vertikal pada Bisecting Technique Radiography Terhadap Keakuratan Dimensi Panjang Gigi Premolar Satu Atas. *J B-Dent*. 2018;5(1):1-8.
- White SC, Pharoah MJ. *Oral Radiography Principles and Interpretation*. 7th ed. Amsterdam: Elsevier; 2014. p.91-113.
- Cyntia D. Gambaran Rata-Rata Panjang Gigi Premolar Rahang Atas dan Rahang Bawah Menggunakan Radiografi Periapikal Digital Antara Teknik Paraleling dan Bisecting ( Penelitian In Vitro ). Skripsi. Universitas Sumatera Utara. 2021. p.31.
- Vasconcelos K de F, Rovaris K, Nascimento EHL, Oliveira ML, Távora D de M, Bóscolo FN. Diagnostic accuracy of phosphor plate systems and conventional radiography in the detection of simulated internal root resorption. *Acta Odontol Scand*. 2017;75(8):573-6.
- Yoon DC, Mol A, Benn DK, Benavides E. Digital Radiographic Image Processing and Analysis. *Dent Clin North Am*. 2018;62(3):341-59.
- Takehita WM, Iwaki LCV, Da Silva MC, Tonin RH. Evaluation of diagnostic accuracy of conventional and digital periapical radiography, panoramic radiography, and cone-beam computed tomography in the assessment of alveolar bone loss. *Contemp Clin Dent*. 2014;5(3):318-23.
- Yueniwati Y, Rachmawati YL, Prismahany IP. Apical Cuts off as the Highest Prevalence of Errors during the Process of Periapical Radiograph Bisecting Technique by Dentistry Students. *Indones Med Life Sci J*. 2021;1(1):8-14.

# The correlation of the change in vertical angulation of the beam in the bisecting technique to the length of the tooth

## ORIGINALITY REPORT

10%

SIMILARITY INDEX

9%

INTERNET SOURCES

3%

PUBLICATIONS

5%

STUDENT PAPERS

## PRIMARY SOURCES

1	<a href="https://repository.unair.ac.id">repository.unair.ac.id</a> Internet Source	2%
2	<a href="https://repository.trisakti.ac.id">repository.trisakti.ac.id</a> Internet Source	1%
3	<a href="http://www.lwcag.org">www.lwcag.org</a> Internet Source	1%
4	Submitted to Universitas Prof. Dr. Moestopo (Beragama) Student Paper	1%
5	<a href="http://www.scielo.org.za">www.scielo.org.za</a> Internet Source	1%
6	<a href="http://link.springer.com">link.springer.com</a> Internet Source	1%
7	Priscila Fernanda da Silveira Tiecher, Nádia Assein Arús, Eduarda Adams Hilgert, Heloisa Emilia Dias da Silveira et al. "Exploring digital filters for internal root resorption: how can we improve the diagnosis of small lesions?", Dentomaxillofacial Radiology, 2021	1%



**8** [repositori.usu.ac.id:8080](https://repositori.usu.ac.id:8080) 1 %  
Internet Source

---

**9** [www.mdpi.com](http://www.mdpi.com) 1 %  
Internet Source

---

**10** [nveo.org](http://nveo.org) <1 %  
Internet Source

---

**11** [123dok.com](http://123dok.com) <1 %  
Internet Source

---

Exclude quotes  On

Exclude matches  < 15 words

Exclude bibliography  On

# The correlation of the change in vertical angulation of the beam in the bisecting technique to the length of the tooth

---

## GRADEMARK REPORT

---

FINAL GRADE

GENERAL COMMENTS

**/0**

---

PAGE 1

---

PAGE 2

---

PAGE 3

---

PAGE 4

---

PAGE 5

---

PAGE 6

---