


CASE REPORTS


Painless Placental Abruption with 80% Retroplacental Bleeding: Case Report


Kejadian Solusio Plasenta tanpa Rasa Nyeri dengan Perdarahan Retroplasenta 80%: Laporan Kasus

Atut Cich Mayasari¹ , Nugroho Abikusno², Laksmi Maharani¹, Raditya Wratsangka¹

¹Department of Obstetrics and Gynecology, Faculty of Medicine, Universitas Trisakti

²Department of Nutrition Sciences, Faculty of Medicine, Universitas Trisakti

 atutcichmayasari@trisakti.ac.id

 <https://doi.org/10.18051/JBiomedKes.2024.v7.91-97>

ABSTRACT

The maternal mortality rate in Indonesia is still high. According to the Indonesian Household Health Survey (SKRT) in 2001 found that bleeding in pregnancy contributes as the main cause of maternal mortality. Antepartum hemorrhage can be caused by placental abruption (PA) and placenta previa. This bleeding condition is an emergency case because it threatens the lives of both mother and fetus (mother-fetal dyad). Placental abruption is usually accompanied by pain due to continuous uterine contractions. In this case, although concealed hematoma exists in almost 80% of PA cases, the mother shows no sign or symptom even though the fetus is severely at risk. This condition can cause delayed management that leads to mother and fetal mortality, known as asymptomatic placental abruption.

Keywords: placental abruption; Maternal death; asymptomatic

ABSTRAK

Angka kematian ibu di Indonesia masih cukup tinggi. Berdasarkan Survei Kesehatan Rumah Tangga Indonesia (SKRT) tahun 2001, perdarahan memberikan kontribusi terbesar terhadap kematian ibu. Perdarahan antepartum dapat disebabkan oleh solusio plasenta dan plasenta previa. Keadaan ini merupakan kondisi gawat darurat, karena mengancam jiwa ibu maupun janinnya. Solusio plasenta biasanya disertai oleh rasa nyeri akibat kontraksi uterus yang terus menerus. Namun pada kasus ini, walaupun perdarahan retroplasenta terjadi hampir 80% dan menimbulkan morbiditas pada janin, namun pasien tidak memberikan tanda dan gejala nyeri tersebut. Keadaan ini bisa menyebabkan terlambatnya diagnosis dan penanganan yang berujung pada kematian ibu dan janin. Kondisi ini disebut asimtomatis solusio plasenta.

Kata Kunci: Solusio plasenta; Kematian ibu; asimtomatis

INTRODUCTION

Placental abruption is one of the causes of antepartum hemorrhage. This bleeding occurs when pregnancy reaches more than 20 weeks of gestational age, even though there are some

occurrences after 22 weeks. This bleeding occurs due to the separation of the placenta from the uterus. This placental abruption can occur totally or partially. Separation of the placenta can begin from the edge or the center part of the placenta, which is close to where the umbilical cord attaches. Early separation of the placenta can have a direct impact on the fetus. If placental abruption occurs in the center part of the placenta, sudden intrauterine fetal death can happen.^{1,3}

Placental abruption can cause hypovolemic shock because of bleeding, DIC, renal failure because of hypoxia in the renal tissue, and maternal death. It can increase fetal morbidity and mortality rates. Premature birth and fetal hypoxia occur most, followed by fetal death.^{4,5} The incidence rate of placental abruption is 0,4-1% of pregnancies. This incidence rate can be stated to be low, but it is a quite serious obstetric emergency because placental abruption can cause fetal and maternal death. That said, placental abruption can increase maternal and fetal mortality rates by 10%.^{5,6}

In terms of establishing the diagnosis of placental abruption, there are symptoms and signs that often occur, such as abdominal pain, vaginal bleeding, continuous uterine contractions, and abnormalities of fetal heart rate.³ Ultrasonography (USG) also becomes the supporting examination tool to confirm the diagnosis of placental abruption by finding retroplacental bleeding images. Abnormalities were found when fetal heart rate was recorded with cardiotocography (CTG).^{7,8}

Some of the risk factors that can cause placental abruption are premature ruptures of the membrane, hypertension, preeclampsia, history of cesarean section, smoking, trauma, young gestational age, uterus overdistention because of multiple pregnancies, polyhydramnios, and multiparity.⁹⁻¹²

CASE REPORT

A 33-year-old woman, 30 weeks pregnant, came to the emergency department with amniotic fluid leaks 3 hours ago. This amniotic fluid leak, accompanied by a slight discharge of blood from the birth canal. This is her third pregnancy, and two previous deliveries occurred by cesarean section. The indication of the first cesarean section was oligohydramnios, and the second cesarean section was the oblique presentation of the fetus. Her first child was five years old, and the second was two years old. Vital sign examination shows blood pressure at 120/80mmHg, respiration rate at 20 breaths per minute, heart rate at 89 beats per minute, and temperature at 36,6°C. General status examination shows ordinary signs.

CTG result shows category 2 with no acceleration (Picture 1). In this patient, intrauterine resuscitation and movement stimulation were performed to cause acceleration on the CTG image. The patient was given oxygen 2 liters per minute with a nasal cannula for 30 to 60 minutes, with the patient lying on her side, and given tocolytics with nifedipine 10mg orally also and planned to another CTG after that.

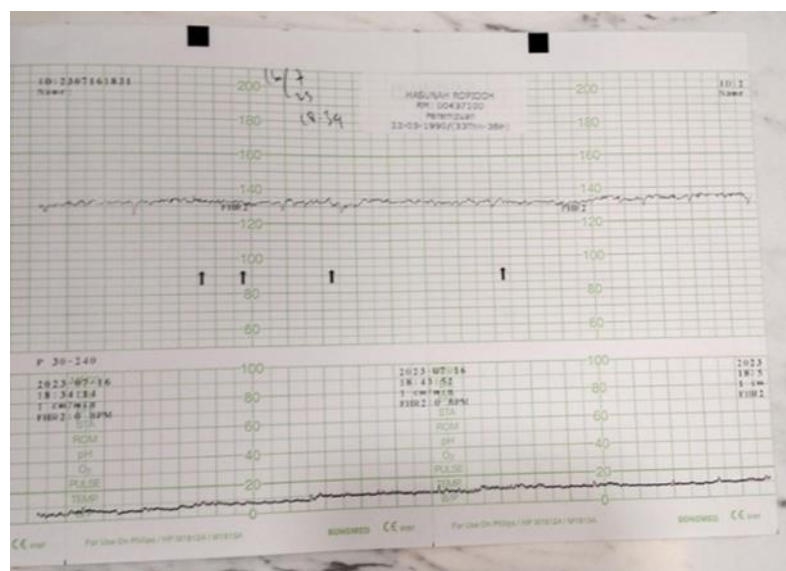
USG examination shows a single and living fetus with head presentation. Estimated fetal weight was 1450 g. The placenta was implanted at the posterior corpus of the uterus with sufficient amniotic fluid.

This patient's diagnosis was premature rupture of the membrane with the risk of contraction. Prophylaxis antibiotics Ceftriaxone was given 2x1 g intravenous, and Dexamethasone 2x6 mg intravenous was given for pulmonary maturation. Tocolytics with Nifedipine are planned to be given routinely.

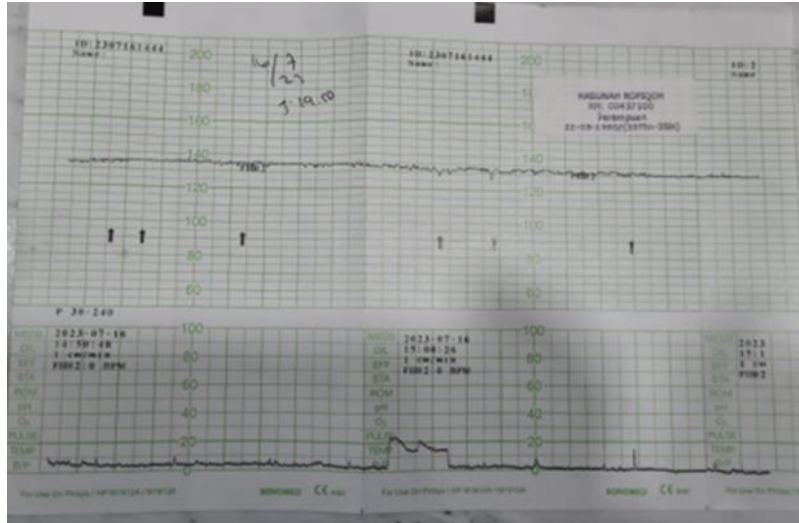
Blood laboratory test results when a patient came showed Haemoglobin at 12,3 g/dl, leukocyte at 14.250/ μ l, and thrombocyte at 182.000/ μ l. Intrauterine resuscitation was performed for 30 minutes, and after that, another CTG examination was accomplished. The result shows that the fetus is still in category 2 (Picture 2). The patient has been consulted by the fetomaternal department, with no improvement in CTG results after intrauterine resuscitation. A cesarean section was planned due to fetal hypoxia.

A cesarean section was performed approximately 3 hours after the patient came to the hospital. During the operation, after the fascia was opened, a cave-like uterus was found (Picture 3). The baby was born weighing 1600g with an APGAR score of 0 and 0 at the 1st and 5th minutes. Retroplacental bleeding was found. Blood and blood clots at the retroplacental part were around 700cc (Picture 4). The edge of the placenta is still attached to the endometrium, with blood trapped at the retroplacental part. Amniotic fluid was few and clear. Uterus cauelair was present with good contraction and no hemorrhages post-cesarean section.

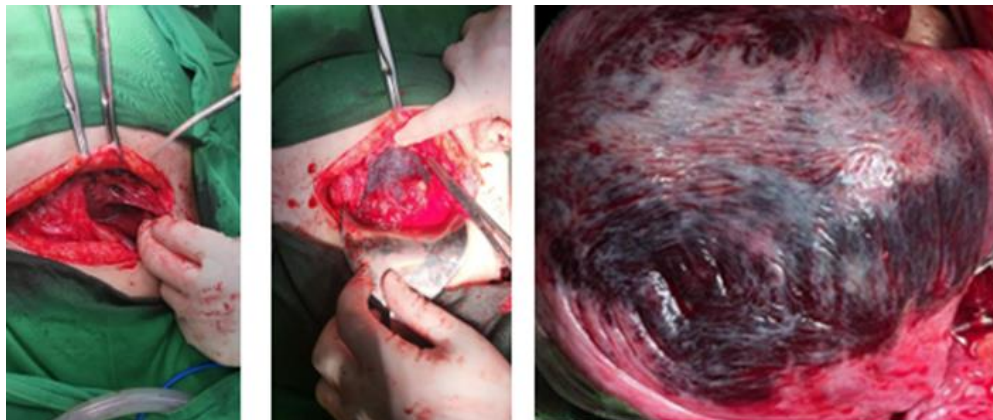
Postoperative peripheral blood laboratory showed hemoglobin at 8,8g/dl, leukocyte at 11.630 / μ l, and thrombocyte at 151.000/ μ l. On the second day of post-op observation, the patient was actively mobilized, uterus contraction was good, and there was normal vaginal bleeding suitable with the lochia rubra. Operation Scar was good, with no blood seepage. The patient was discharged on the third day. The patient was given an iron tablet and breastmilk suppression management.



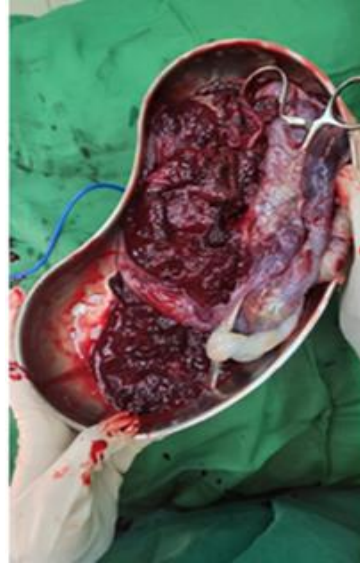Picture 1. CTG results when the patient came to the ED



Picture 2. CTG after intrauterine resuscitation



Picture 3. Uterus Cauvelair before and after birth



Picture 4. Placenta with retroplacental bleeding

DISCUSSION

The patient presents with leakages of clear amniotic fluid at the gestational age of 30 weeks and no abdominal pain. The fetal movement was still present. According to premature gestational age (30 weeks), premature pregnancy and premature rupture of membrane become this patient's diagnosis. With this diagnosis, conservative management was planned. Conservation management meant giving times for fetal pulmonary maturation and administering antibiotics to prevent infection.

Placental abruption was not confirmed at that time, because abdominal pain typically present with placental abruption was absent in this patient. USG examination also does not show the images of placental abruption. It stated that USG has a sensitivity of 24% and specificity of 96% to confirm the diagnosis of placental abruption. USG has a positive predictive value (PPV) of 88% and a negative predictive value (NPV) of 50% to diagnose placenta previa.¹³ The undiagnosed placental abruption at that time could be caused by an abruption process that still occurs.

The risk factors of placental abruption in this patient are rupture of membranes and the history of 2 previous cesarean sections. Blood and blood clots inside the retroplacental pouch are trapped, therefore no vaginal bleeding. In this patient, abdominal pain and continuous contractions are absent whereas blood and blood clots trapped inside the retroplacental pouch are plenty (700cc). This asymptomatic placental abruption can occur because the patient has a high threshold of pain. This uterus cauvclair can cause hypotonia uteri and there was a probability of postpartum hemorrhages to be worried. However, in this patient, uterus contractions are quite good. The results of laboratory examination when patients come to the ED until post-operation show 4,5g/dl hemoglobin decreases, from 12.3 g/dl to 8,8 g/dl. This hemoglobin decrease is suitable with the patient's placental abruption that occurred at the patient's arrival to ED until a cesarean section was performed.^{12,14,15}

CONCLUSION

Placental abruption with typical symptoms such as vaginal bleeding, abdominal pain, and fetal distress are relatively easier to diagnose, so management is quicker. If placental abruption occurs with no abdominal pain, it needs sharp observation so that the case won't worsen and increase maternal morbidity and mortality.

ACKNOWLEDGEMENT

None

AUTHORS CONTRIBUTION

All authors contributed to this article

FUNDING

This case report is not funded by any institution.

CONFLICT OF INTEREST

The authors declared no conflict of interest related to this article

REFERENCES

1. Abhirami GR, Sathyavani C, Alexander MC, et al. Abruptio placenta: an obstetrician's nightmare. *The New Indian Journal of OBGYN*. 2023;10(1):149–53.
2. Brandt JS, Ananth CV. Placental abruption at near-term and term gestations: pathophysiology, epidemiology, diagnosis, and management. Vol. 228, *American Journal of Obstetrics and Gynecology*. Elsevier Inc.; 2023. p. S1313–29.
3. Baczkowska M, Kosińska-Kaczyńska K, Zgliczyńska M, et al. Epidemiology, Risk Factors, and Perinatal Outcomes of Placental Abruption—Detailed Annual Data and Clinical Perspectives from Polish Tertiary Center. *Int J Environ Res Public Health*. 2022;19(9): 5148. doi: 10.3390/ijerph19095148
4. Lokhande V, Jadhav K, Kadam M, et al. Study of Maternal and Foetal Outcome in Abruptio Placentae. *Int J Med Sci Clin Invent*. 2021;8(01):5208–13.
5. de Moreuil C, Hannigsberg J, Chauvet J, et al. Factors associated with poor fetal outcome in placental abruption. *Pregnancy Hypertens*. 2021;23:59–65.
6. Li Y, Tian Y, Liu N, et al. Analysis of 62 placental abruption cases: Risk factors and clinical outcomes. *Taiwan J Obstet Gynecol*. 2019;58(2):223–6.
7. Hapdijaya I, Tessalina E, Herdiana EMN, et al. Placental Abruption as a Complication of Preeclampsia that Causes Fetal Distress. *Medical Clinical Update*. 2022;1(1):36–8.
8. Qiu Y, Wu L, Xiao Y, et al. Clinical analysis and classification of placental abruption. *Journal of Maternal-Fetal and Neonatal Medicine*. 2021;34(18):2952–6.
9. Mushtaq R, Afridi U, Bakhsh FM. A Retrospective Analysis of Risk Factors and Fetomaternal Outcome of Placental Abruption. *JIIIMC*. 2020;15(1):9-13
10. Akadri A, Ogunsowo K, Odelola O. Abruptio Placenta: A retrospective analysis in a tertiary hospital, Sagamu, Nigeria. *Trop J Obstet Gynaecol*. 2018;35(2):142.

11. Schur E, Baumfeld Y, Rotem R, et al. Placental abruption: assessing trends in risk factors over time. *Arch Gynecol Obstet.* 2022;306(5):1547–54.
12. Wulandari IA. Hubungan Paritas Ibu (Primipara Dan Multipara) Terhadap Kejadian Solusio Plasenta Di RSUD Syekh Yusuf Gowa Tahun 2018. *Jurnal Kesehatan Delima Pelamonia.* 2018;2(1):36-40
13. Sherer DM, Kheyman M, Benayoun J, et al. Incidental sonographic finding of a concealed placental abruption leading to delivery at 37 weeks' gestation. *Journal of Clinical Ultrasound.* 2021;49(6):630–1.
14. Devabhaktuni P, Konkathi AK. Placental abruption an obstetric emergency: management and outcomes in 180 cases. *Int J Reprod Contracept Obstet Gynecol.* 2020;9(8):3188.
15. Li Y, Tian Y, Liu N, et al. Analysis of 62 placental abruption cases: Risk factors and clinical outcomes. *Taiwan J Obstet Gynecol.* 2019;58(2):223–6.



This work is licensed under a Creative Commons Attribution Non-Commercial 4.0 International License
