



JOURNAL OF INDOONESIAN DENTAL ASSOCIATION

[PERSATUAN DOKTER GIGI INDONESIA](#)

★ P-ISSN : 26216183 <> E-ISSN : 26216175

2
Impact Factor

45
Google Citations

S3
Current Accreditation

[Google Scholar](#) [Garuda](#) [Website](#) [Editor URL](#)

History Accreditation

2018 2019 2020 2021 2022

Garuda [Google Scholar](#)

Effect of Glycerin Application on Discoloration of Nanofiller Composite in Instant Coffee

Indonesian Dental Association [Journal of Indonesian Dental Association Vol 5 No 1 \(2022\): May 33-38](#)

📅 2022 📄 DOI: [10.32793/jida.v5i1.749](#) 📄 [S3 Journal](#)

Effect of Pineapple Juice (Ananas comosus) on Surface Roughness of Preheated and Non-Preheated Nanohybrid Composite Resins

Indonesian Dental Association [Journal of Indonesian Dental Association Vol 5 No 1 \(2022\): May 1-5](#)

📅 2022 📄 DOI: [10.32793/jida.v5i1.757](#) 📄 [S3 Journal](#)

The Effect of Immersion in Soda Containing Sucrose and Aspartame on The Compressive Strength of Bulk-fill Composite Resin

Indonesian Dental Association [Journal of Indonesian Dental Association Vol 5 No 1 \(2022\): May 39-43](#)

📅 2022 📄 DOI: [10.32793/jida.v5i1.767](#) 📄 [S3 Journal](#)

Synthesis and Physical Characterization of Nano-Hydroxyapatite-Collagen-Epigallocatechin-3-Gallate Hydrogel Composite

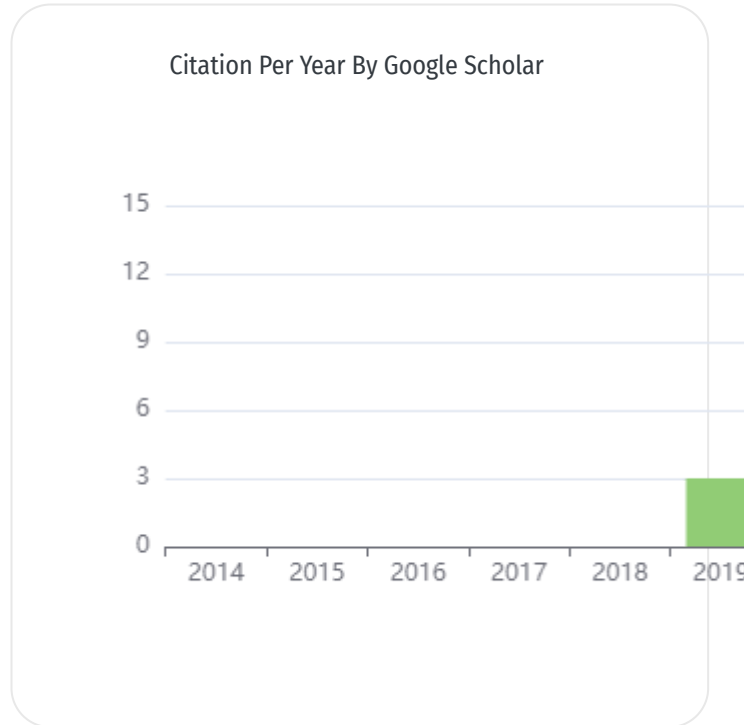
Indonesian Dental Association [Journal of Indonesian Dental Association Vol 5 No 1 \(2022\): May 7-13](#)

📅 2022 📄 DOI: [10.32793/jida.v5i1.769](#) 📄 [S3 Journal](#)

Tooth-Supported Overdenture Retained with Ball Attachments and Custom-made Coping: A Case Report

Indonesian Dental Association [Journal of Indonesian Dental Association Vol 5 No 1 \(2022\): May 45-48](#)

📅 2022 📄 DOI: [10.32793/jida.v5i1.782](#) 📄 [S3 Journal](#)



Journal By Google Scholar

	All	Since 2017
Citation	45	45
h-index	3	3
i10-index	1	1

[The Effect of Glycerin Application on The Surface of Microhybrid Composite Resin to Its Compressive Strength with Immersed in Pure Coffee Solution](#)

Indonesian Dental Association [Journal of Indonesian Dental Association Vol 5 No 1 \(2022\): May 15-19](#)

2022 [DOI: 10.32793/jida.v5i1.744](#) [S3 Journal](#)

[Intra- and Extraoral Signs of Probable Bruxism \(Scoping Review\)](#)

Indonesian Dental Association [Journal of Indonesian Dental Association Vol 5 No 1 \(2022\): May 49-56](#)

2022 [DOI: 10.32793/jida.v5i1.721](#) [S3 Journal](#)

[The Effect of Horn Beetle Nanochitosan \(Xylotrupes gideon\) Addition on The Hardness of Glass-ionomer Cement](#)

Indonesian Dental Association [Journal of Indonesian Dental Association Vol 5 No 1 \(2022\): May 27-31](#)

2022 [DOI: 10.32793/jida.v5i1.719](#) [S3 Journal](#)

[Effects of Clinacanthus nutans and Aloe vera Extracts on bFGF Synthesis in Fibroblasts](#)

Indonesian Dental Association [Journal of Indonesian Dental Association Vol 5 No 1 \(2022\): May 21-26](#)

2022 [DOI: 10.32793/jida.v5i1.726](#) [S3 Journal](#)

[Dental and Oral Health Status of Elementary School Children in Central Lampung](#)

Indonesian Dental Association [Journal of Indonesian Dental Association Vol 4 No 1 \(2021\): April 7-13](#)

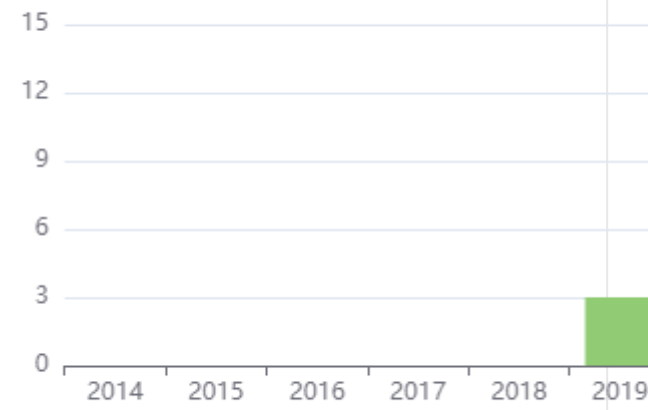2021 [DOI: 10.32793/jida.v4i1.669](#) [S3 Journal](#)

[View more ...](#)

Get More with
SINTA Insight

[Go to Insight](#)

Citation Per Year By Google Scholar



Journal By Google Scholar

	All	Since 2017
Citation	45	45
h-index	3	3
i10-index	1	1

J I D A



JOURNAL OF INDONESIAN
DENTAL ASSOCIATION



[Home](#) / [Editorial Team](#)

EDITOR IN-CHIEF

Armelia Sari Widyarman, [\[57203892772\]](#) Department of Microbiology, Division of Oral Biology, Faculty of Dentistry, Trisakti University, Indonesia

BOARD OF EDITORS

Citra Fragrantia Theodora, [\[57190048861\]](#) Department of Oral Biology, Faculty of Dentistry, University of Indonesia, Indonesia

Muhamad Orliando Roeslan, [\[57202022094\]](#) Department of Histology, Faculty of Dentistry, Trisakti University, Indonesia

Muhammad Ihsan Rizal, Department of Biochemistry and Molecular Biology, Faculty of Dentistry, Trisakti University, Indonesia

Rosa Amalia, [\[48461008800\]](#) Department of Preventive and Community Dentistry, Faculty of Dentistry, Gadjah Mada University, Indonesia

Rahmi Amtha, [\[26031894400\]](#) Department of Oral Medicine, Faculty of Dentistry, Trisakti University, Indonesia

Yosi Kusuma Eriwati Arianto, Department of Dental Material, Faculty of Dentistry, Universitas Indonesia, Indonesia

SERTIFIKAT AKREDITASI

[Editorial Team](#)[Board of Reviewers](#)[Focus and Scope](#)[Author Fees](#)[Publication Ethics](#)[Peer Review Process](#)[Author Guidelines](#)[Plagiarism Screening Policy](#)[Open Access Policy](#)[Conflict Of Interest Policy](#)[Copyright Notice](#)[Unique Visits](#)



Current Issue

Vol 3 No 2 (2020): October

Published: 2020-10-30

Research Article

The Correlation between Mandibular Condyle Shape and Temporomandibular Joint Conditions in Adult Females

Dominica Dian Saraswati Sumantri, Rosalina Tjandrawinata, Joko Kusnoto

55-60

[PDF](#)

The Effect of Curcuma zedoaria Extract on Enterococcus faecalis

Danica Anastasia, Aina Desmarani, Merryca Bellinda

61-64

[PDF](#)

Effect of Ethanol Extracts from Persea americana Leaves on HSC-3 Proliferation

Svetlana Tesselonica, Moehamad Orliando Roeslan

65-70

[PDF](#)

SERTIFIKAT AKREDITASI



[Editorial Team](#)

[Board of Reviewers](#)

[Focus and Scope](#)

[Author Fees](#)

[Publication Ethics](#)

[Peer Review Process](#)

[Author Guidelines](#)

[Plagiarism Screening Policy](#)

[Open Access Policy](#)

[Conflict Of Interest Policy](#)

[Copyright Notice](#)

[Unique Visits](#)



Indonesian Dental Association

Journal of Indonesian Dental Association

<http://jurnal.pdgi.or.id/index.php/jida>
ISSN: 2621-6183 (Print); ISSN: 2621-6175 (Online)



Research Article

The Correlation between Mandibular Condyle Shape and Temporomandibular Joint Conditions in Adult Females

Dominica Dian Saraswati Sumantri^{1,2}, Rosalina Tjandrawinata³, Joko Kusnoto^{4,5}

¹ Postgraduate program of Dental Science, Faculty of Dentistry, Trisakti University, Jakarta, Indonesia

² Department of Dentomaxillofacial Radiology, Faculty of Dentistry, Maranatha Christian University, Indonesia

³ Department of Dental Material, Faculty of Dentistry, Trisakti University, Jakarta, Indonesia

⁴ Department of Orthodontic, Faculty of Dentistry, Trisakti University, Jakarta, Indonesia

Received date: February 21, 2020. Accepted date: June 18, 2020. Published date: October 30, 2020.

KEYWORDS

condyle shapes;
female adults;
panoramic radiograph;
temporomandibular joint;
temporomandibular joint
condition

ABSTRACT

Introduction: Conditions of the temporomandibular joint (TMJ) are affected by changes in movement and load during the joint's function, which can cause morphological changes in hard tissues, such as the condyle. Panoramic radiographs can provide an indication of changes in hard tissues in TMJ. **Objectives:** The aim of this study was to determine whether there was any correlation between mandibular condyle shapes as seen on panoramic radiographs and TMJ conditions in adult female participants. **Methods:** The participants of this study were 75 adult female patients who underwent a panoramic radiograph examination conducted at the Maranatha Dental Hospital Radiology Unit. The patients were clinically examined based on the Research Diagnostic Criteria for Clinical Temporomandibular Disorder (RDC/TMD) questionnaire and also their panoramic radiographs. The data from the patients were categorized into four groups according to the RDC/TMD: normal, muscle disorders, disc displacement, and other joint diseases. Next, the radiographs were analyzed by two observers to determine the condyle shapes. Condyle shapes were classified into four groups: ovoid, flat, erosion, and osteophyte. **Result:** This study showed that of 75 patients, the right TMJ was normal in 34 patients, 2 patients had muscle disorders, 24 demonstrated disc displacement, and 15 had other joint diseases. For the left side of the TMJ, 22 radiographs were normal, 2 revealed muscle disorders, 35 identified disc displacement, and 16 showed other joint diseases. There was a strong agreement between the two observers in determining the right ($\kappa=0.681$) and left condyle shapes ($\kappa=0.652$). All participants' findings indicated that condyle shapes and TMJ conditions are highly correlated for both the right ($\eta^2=0.889$) and left condyle ($\eta^2=0.762$). **Conclusion:** This study concluded that mandibular condyle shapes seen on panoramic radiographs and TMJ conditions in adult female participants were highly correlated.

⁵ Corresponding Author

E-mail address: j_kusno@hotmail.com (Kusnoto J)

DOI: [10.32793/jida.v3i2.597](https://doi.org/10.32793/jida.v3i2.597)

Copyright: ©2020 Sumantri DDS, Tjandrawinata R, Kusnoto J. This is an open access article distributed under the terms of the Creative Commons Attribution License, which permits unrestricted use, distribution, and reproduction in any medium provided the original author and sources are credited.

INTRODUCTION

The temporomandibular joint (TMJ) is an articular system located in the mandible and temporal bone that allows the mandible to function with a balanced dynamic mechanism.¹ TMJ disorders are influenced by many factors. These conditions can be symptomized by pain, masticatory muscle dysfunction, and bone changes.² TMJ disorders are community health problems that affect about 5–12% of the population, with the highest incidence in people from 20–40 years of age and the lowest prevalence rate in young and elderly patients.^{3,4}

One of the supporting modalities that is commonly used to diagnose TMJ disorders is radiological examination. TMJ disorders can be investigated using transcranial radiography, arthrography, computed tomography (CT), cone-beam computed tomography (CBCT), and magnetic resonance imaging (MRI).⁵ In Indonesia, the use of MRI to confirm the diagnose of TMJ disorders is rare since it is not widely available and the cost is considerably high. Instead, clinicians commonly rely on a panoramic radiographic examination to diagnose TMJ disorders.

Panoramic radiography has the advantages of greater availability, a lower cost, and the ability to image the entire lower one-third of the face. Due to these advantages, this modality is the most frequently used type of radiography for preliminary diagnosis purposes. Many studies have investigated TMJ disorders. Honda, Yoshiko, and Sasaki used panoramic radiography in 1994 to classify condyle head shapes. Their study showed that flattening has the highest rate of incidence in symptomatic TMJ disorders and also in patients with missing molars and premolars.⁶

In 2016, Borahan et al. reported that in a Turkish population, the normal shape of the mandibular condyle was oval.⁷ Another study that carried out panoramic radiograph examinations in patients with TMJ disorders both with and without clicking showed that there was no significant difference between with and without clicking groups.⁸ Obamiyi et al. investigated five racial groups and noted the frequent occurrence of condyle anomalies in Chinese patients compared to those from other races.⁹

These previous studies emphasized the need to know how condyle shapes affect TMJ disorders. Therefore, this study aimed to determine whether there was any correlation between the mandibular condyle shapes identified on panoramic radiographs and the incidence of TMJ conditions in adult female participants. This information will be important in supporting radiological interpretation, the prevention of diseases, and clinical care decisions.

MATERIAL AND METHODS

This study was an observational analytic study with a cross-sectional design. The study was conducted at the Maranatha Dental Hospital Radiology Unit. The ethical aspect of this research has been reviewed and approved by the Trisakti University Faculty of Dentistry Ethics Committee (Ethical Clearance No. 248/S2/KEPK/FKG/3/2019).

The study population included patients who came to the Maranatha Dental Hospital Radiology Unit for consultation and panoramic radiography. Samples were taken consecutively with inclusion criteria as follows: female patients ≥ 20 years of age; no prior history of trauma to the jaws, head, or neck; panoramic radiographs with complete imaging of the condyle, eminentia articularis, glenoid fossa, and meatus acusticus internus bilaterally.

The condition of the TMJ system was evaluated during a clinical examination and recorded according to the Research Diagnostic Criteria for Clinical Temporomandibular Disorder (RDC/TMD) questionnaire. The conditions of TMJ disorders were categorized as follows: Group 0: normal; Group 1: muscle disorders; Group 2: disc displacement; Group 3: arthralgia/arthritis/arthrosis.

Condyle shape data were collected by tracing the outer edge of the condyle on panoramic radiographs using Morita Veraviewpocs 3D R100 software (J. Morita Corp, Japan). The condyles were then categorized into ovoid, flat, erosion, or osteophyte shapes (Fig. 1).

The measurement of the mouth opening was carried out using a zero-pointed ruler (0) placed at the distance between the incisal maxillary incisors and the lower jaw. The patient was asked to make lateral biting movements to the right and left, and then the difference between the maxillary and mandibular labio-incisal embrasure was measured. The patient was asked to state the level of pain when the jaw was palpated in the upper back region of the ear, the lateral border of the eyebrows, above the cheekbones, under the cheekbones up to the mandibular angle, and the neck. These data were used to determine the TMJ condition along with the RDC/TMD algorithm.

If a patient reported having pain in the past month, then the level of pain in the extraoral and intraoral muscles was summed. If the muscle pain felt by the patient was present in three or more muscles and was located unilaterally, the vertical range of motion distance that could be achieved without pain and overlapping was added. In addition, results ≥ 40 mm were categorized as myofascial pain. A sum of < 40 mm was reached by

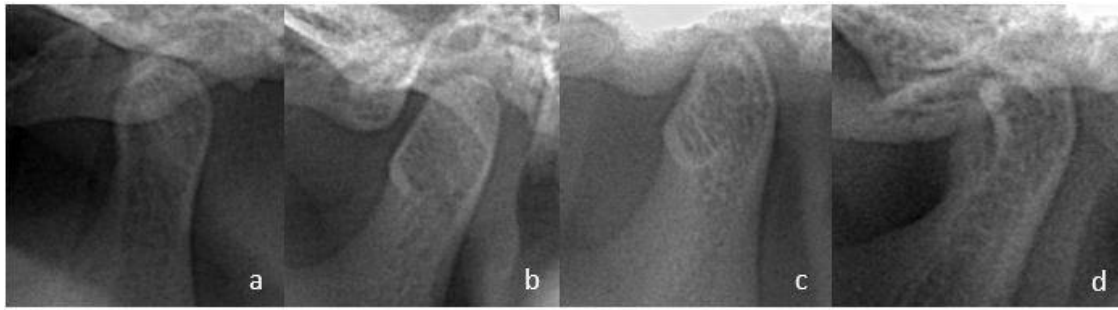


Figure 1. Condyle shape category. a. Ovoid. The condyle has convexity on its anterior, posterior, and superior aspects. b. Flat. The condyle has a flat contour that deviates from the convexity of the condyle's anterior/superior/posterior parts. c. Erosion. The condyle has a radiolucent appearance at the cortical (radiopaque) edge of the condyle head. d. Osteophyte. The condyle has a sharp radiopaque image resembling a notch on its outer edge.

calculating the vertical range of motion with the help of the operator minus the vertical range of motion without pain. Any results with a difference of < 5 mm were categorized as myofascial pain, while a > 5 mm difference was classified as myofascial pain with limited opening. Participants with myofascial pain and myofascial pain with limited opening were placed in Group 1.

Group 2 was distinguished by the presence or absence of clicking in the vertical range of motion. If clicking was found, then it was necessary to identify whether it occurred only when opening or closing the mouth or during both actions. If clicking occurred when opening and closing the mouth, then the difference between the distance of the clicking sound when opening or closing the mouth was calculated. In addition, any difference between the opening and closing of the mouth with clicking ≥ 5 mm with a loss of clicking when opening with protrusive movement or a difference between the opening and closing of the mouth with clicking and closing that was < 5 mm and was accompanied by clicking with lateral movement was included in the disc displacement. If no clicking was found when opening or closing the mouth, but a history of limited mouth opening was present, the patient was included in the disc displacement category except when no deviation or deflection and joint sounds were found. Patients who reported pain during palpation or complained of pain were included in Group 3 unless crepitus was not found during joint movement. Any patients who did not fit in with the Group 1 algorithm proceeded to the Group 2 and Group 3 algorithms for assessment.

Two dental radiology specialists who agreed on the landmarks of the radioanatomy section from the panoramic radiographs determined the condyle shape by tracing the condyle exactly on the radiopaque line of the edge of the condyle. The two observers' validity and reliability in determining the condyle shape were tested

using a double-blinded procedure for the first 30 samples. A Kappa test was carried out to verify the validity and reliability. In addition, an Eta-squared test was conducted to determine the relationship between TMJ conditions and condyle shapes. (SPSS, Chicago, IL).

RESULTS

The Kappa test results showed strong agreement between the observers with $\kappa = 0.681$ for right condyle shapes and $\kappa = 0.652$ for left condyle shapes. The number of participants in each TMJ condition can be seen in Table 1. The distribution of right and left TMJ disorders based on the condylar shape shown on the panoramic radiographs can be seen in Table 2.

The Eta-squared value between condylar shape and right-sided TMJ conditions was $\eta^2=0.889$. The F count (187,326) was larger than the F table, which indicated a very strong relationship between condylar shapes and right-sided TMJ conditions. The Eta-squared value between condylar shape and left-sided TMJ conditions was $\eta^2=0.762$. The F count (44,846) was larger than the F table, which suggested that there was a very strong relationship between condyle shapes and left-sided TMJ conditions.

Table 1. Participants' right and left TMJ conditions grouped by RDC/TMD criteria.

TMJ condition	Number of Patients	
	Right TMJ	Left TMJ
Group 0	34	22
Group 1	2	2
Group 2	24	35
Group 3	15	16

Group 0: Normal; Group 1: Muscle Disorders; Group 2: Disc Displacement; Group 3: Athralgia/athritis/arthrosis

Table 2. The distribution of right- and left-side TMJ conditions grouped by condyle shapes.

TMJ Condition	Condyle Shape							
	Ovoid		Flat		Erosion		Osteophyte	
	R	Left	Right	Left	Right	Left	Right	Left
Group 0	34	21	-	-	-	-	-	1
Group 1	-	-	2	2	-	-	-	-
Group 2	4	16	20	19	-	-	-	-
Group 3	-	-	4	4	7	8	4	4

Group 0: Normal; Group 1: Muscle Disorders; Group 2: Disc Displacement; Group 3: Athralgia/athritis/arthrosis

DISCUSSION

Panoramic radiography is a radiological technique that provides an overview of the jaw and its surrounding tissues and allows dentists to see a large area, including the maxilla and mandible, in just one radiograph.¹⁰ Panoramic radiography is useful for the early detection of defects before proceeding to further radiological examination. In temporomandibular cases, panoramic radiography may reveal a picture of advanced bone changes and is indicated in patients who have minimal mouth opening.¹¹

In this study, all female patients were over the age of 20 years. Previous studies have shown many TMJ disorders in women of reproductive age.¹² Hormonal, social, and cultural factors, along with stress levels, are thought to be the triggers for TMJ disorders.¹³ Levels of estrogen and prolactin hormones are influenced by changes in a woman's quality of life, which also affects stress levels, especially in women from 24–33 years.¹⁴ Increased levels of estrogen can reduce pain in TMJ disorders, while decreases in estrogen will increase pain.¹⁵ Estrogen and prolactin stimulate chondrogenesis and maintain chondrocytes against apoptosis. If there is a decrease in the levels of both hormones, degradation of cartilage and articular bones may occur.¹⁶ All of these conditions were identified in our patients' age group.

The results of our examination of TMJ conditions using the RDC/TMD questionnaire indicated that most of the right-sided TMJs were normal, while the left TMJ side was more likely to show conditions associated with disc displacement. These results indicate the possibility that TMJ disorders that only affect one side have a higher prevalence than TMJ disorders that affect both sides.¹⁷ One explanation for this finding is that some patients have a habit of chewing only on one side. Usually, the side that makes broader movements is more lubricated and therefore has a better metabolic exchange than the immobile side.¹⁸ The associated joint overload causes the

condyle to change shape by increasing the condyle surface area that is in contact with the articular surface so that the load received is lighter.¹⁹

Anatomically, the TMJ has several components including joint capsules, extracapsular ligaments, articular eminence, glenoid fossa, condyle, disc, ligamentous discs, and synovial membranes.²⁰ The mandibular condyle is part of the mandible, which is located in the glenoid fossa and affects the opening and closing movements of the mouth. In patients with TMJ disorders, there is a translation movement when first opening the mouth and then again at the end of the motion when closing the mouth. Sudden changes in movement that allow the condyle to return to its normal position cause a clicking sound when the mouth is opening or closing. If this condition persists, there will be an increase in joint dysfunction, which causes changes in disc morphology and produces secondary clicking sounds.²¹ The change in disc morphology will be followed by a biomechanical reaction in the TMJ.²²

Based on the distribution of condyle shapes in this study, most patients with normal TMJ conditions had an ovoid condyle shape. However, one of the research participants in Group 2 had an osteophyte condyle shape on the left side and a right side with a TMJ condition. This finding indicates that these disorders possibly cause a long-term change in joint movements, so the body begins to adapt to improve the joint. Osteophytes are formed as an expansion of the joint surface to stabilize the power load.²³ Subsequently, the patient showed facial skeleton remodeling, deviation of the affected area, unstable malocclusion, and occlusal discrepancy.²⁴

All condyle shapes in Group 1 were flat, while in Group 2, the condyle shapes found were flat and ovoid. In Group 3, three kinds of condyle shapes were identified: erosion, flat, and osteophyte. Sclerosis and pseudocyst condyle shapes were not present in any participants. The pseudocyst shape was thought to be an

advanced form of erosion distinct from the osteophyte shape.²⁵ Previous investigations into disc displacement and osteoarthritis suggest that osteoarthritis is a continuation of disc displacement.²⁶ Flat and sclerosis shapes on the surface of condyles are a sign of remodeling and increased load. Erosion is the early stage of a degenerative change.²³ Previous studies using CBCT have reported that flat and osteophyte condyle shapes are commonly found in cases of degenerative joint disorders.²⁷ Degenerative joint disorders are also caused by inflammatory processes. In addition, mechanical and metabolic factors play a role in the initial damage to the cartilage. These factors will initiate biomechanical changes in hard and soft tissues in the joint, which provoke an immune response that leads to the secretion of inflammatory mediators.²³ Chondrocytes will release mechanical responsive mechanisms, so metabolic mechanisms and pathological activation will increase and result in irreversible cartilage degradation.²²

This study showed that there was a relationship between condyle shapes and TMJ disorders. This conclusion is different from those of previous studies that have identified a poor correlation between condyle changes, pain, and other clinical symptoms in TMJ osteoarthritis.²⁸ This difference likely occurred because condyle shapes in this study were grouped based on the presence of any TMJ condition without dividing them into groups by factors of TMJ disorder symptoms. Different relationships between the right and left TMJ show that conditions that may produce clinical findings are not directly reflected in the radiograph.²⁹ The duration of TMJ disorders and factors involved with the contralateral side may also affect the radiograph's appearance. Symptoms may be detected only on one side, but the radiograph may indicate involvement on the other side.²⁵

CONCLUSION

This study found that mandibular condylar shapes revealed by panoramic radiography and the presence of TMJ conditions in adult female patients were highly correlated. In future studies, it will be necessary to investigate etiological factors that may indicate the existence of other TMJ disorders. It is also important to use other modalities, such as panoramic radiography specially developed for TMJ or CBCT, which will be more accurate in supporting the diagnosis of TMJ disorders.

CONFLICT OF INTEREST

The authors declare that there is no conflict of interest related to this study.

ACKNOWLEDGMENT

The authors would like to thank the Department of Dentomaxillofacial Radiology Maranatha Christian University Dental Hospital and Faculty of Dentistry for their continuous support.

REFERENCES

1. Sümbüllü M, Çağlayan F, Akgül H, Yılmaz A. Radiological examination of the articular eminence morphology using cone beam CT. *Dentomaxillofac Radiol.* 2012;41(3):234–40.
2. Veerappan R, Gopal M. Comparison of the diagnostic accuracy of CBCT and conventional CT in detecting degenerative osseous changes of the TMJ: A systematic review. *J Indian Acad Oral Med Radiol.* 2015;27(1):81-4.
3. Schiffman EL, Truelove EL, Ohrbach R, Anderson GC, John MT, List T, et al. The research diagnostic criteria for temporomandibular disorders: overview and methodology for assessment of validity. *J Orofac Pain.* 2010;24(1):7–24.
4. Schiffman EL, Ohrbach R, Truelove EL, Look JO, Anderson GC, Goulet JP, et al. Diagnostic criteria for temporomandibular disorders (DC/TMD) for clinical and research applications: Recommendations of the international RDC/TMD consortium network and orofacial pain special interest group. *J Oral Facial Pain H.* 2014;28(1):6–27.
5. Pietra LCF, Santiago M de O, Valerio CS, Taitson PF, Manzi FR, Seraidarian PI. Use of transcranial radiograph to detect morphological changes in mandibular condyles. *Rev CEFAC.* 2017;19(1):54–62.
6. Honda E, Yoshino N, Sasaki T. Condylar appearance in panoramic radiograms of asymptomatic subjects and patients with temporomandibular disorders. *Oral Radiol.* 1994;10(2):43–53.
7. Borahan MO, Mayil M, Pekiner FN. Using cone beam computed tomography to examine the prevalence of condylar bony changes in a Turkish subpopulation. *Niger J Clin Pract.* 2016;19(2):259–66.
8. Pramanik F, Firman RN, Sam B. Differences of temporomandibular joint condyle morphology with and without clicking using digital panoramic radiograph. *Padjadjaran J Dent.* 2016;28(3); 153-8.
9. Obamiyi S, Malik S, Wang Z, Singh S, Rossouw E P, Fishman L, et al. Radiographic features associated with temporomandibular joint disorders among African, White, Chinese, Hispanic, and Indian racial groups. *Niger J Clin Pract.* 2018;21(11):1495-500.
10. Capote TSO, Gonçalves MA, Gonçalves A, Gonçalves M. Panoramic radiography-diagnosis of

- relevant structures that might compromise oral and general health of the patient. In: Viridi MS, editor. *Emerging trends in oral health sciences and dentistry*. Rijeka (Croatia): InTech; 2015. pp. 734-62.
11. Ferreira LA, Grossmann E, Januzzi E, de Paula MVQ, Carvalho ACP. Diagnosis of temporomandibular joint disorders: indication of imaging exams. *Braz J Otorhinolaryngol*. 2016;82(3):341–52.
 12. Ahmad M, Chalkoo A. Possible role of estrogen in temporomandibular disorders in female subjects: A research study. *J Indian Acad Oral Med Radiol*. 2014;26(1):30-3.
 13. Bueno CH, Pereira DD, Pattussi MP, Grossi PK, Grossi ML. Gender differences in temporomandibular disorders in adult populational studies: A systematic review and meta-analysis. *J Oral Rehabil*. 2018;45(9):720–29.
 14. Pereira TC, Brasolotto AG, Conti PC, Berretin-Felix G. Temporomandibular disorders, voice and oral quality of life in women. *J Appl Oral Sci*. 2009;17(spe):50–6.
 15. Oliveira JA, Gonçalves TMSV, Vilanova LSR, Ambrosano GMB, Garcia RCMR. Female hormones fluctuation and chewing movement of patients with disc displacement. *Rev Odonto Ciênc*. 2012;27(1):20–5.
 16. Hegde S, Rao G, Sattur A, Nandimath K, Shetty R, Madi M. Role of digital volumetric tomography in assessing morphological variations in condyle and temporal components of patients with asymptomatic temporomandibular joint. *J Indian Acad Oral Med Radiol*. 2019;31(2):140-6.
 17. Progiante P, Pattussi M, Lawrence H, Goya S, Grossi P, Grossi M. Prevalence of temporomandibular disorders in an adult Brazilian community population using the research diagnostic criteria (Axis I and II) for temporomandibular disorders (The Maringá Study). *Int J Prosthodont*. 2015;28(6):600–9.
 18. Santana MU, López CJ, Mora MJ, Otero XL, Santana PU. Temporomandibular disorders: the habitual chewing side syndrome. *PLoS ONE*. 2013;8(4):e59980.
 19. Kuo C, Takahashi M, Maki K. Relationships among occlusal force, condylar surface area, and facial patterns. *Dent Med Res*. 2013;33(2):169–77.
 20. David CM, Elavarasi P. Functional anatomy and biomechanics of temporomandibular joint and the far-reaching effects of its disorders. *J Adv Clin Res Insights*. 2016;3(3):101–6.
 21. Ivkovic N, Racic M. Structural and functional disorders of the temporomandibular joint (Internal disorders). *IntechOpen*. 2018;1-26.
 22. Kuroda S, Tanimoto K, Izawa T, Fujihara S, Koolstra JH, Tanaka E. Biomechanical and biochemical characteristics of the mandibular condylar cartilage. *Osteoarthritis Cartilage*. 2009;17(11):1408–15.
 23. Krisjane Z, Urtane I, Krumina G, Neimane L, Ragovska I. The prevalence of TMJ osteoarthritis in asymptomatic patients with dentofacial deformities: a cone-beam CT study. *Int J Oral Maxillofac Surg*. 2012;41(6):690–5.
 24. Kalladka M, Quek S, Heir G, Eliav E, Mupparapu M, Viswanath A. Temporomandibular joint osteoarthritis: diagnosis and long-term conservative management: a topic review. *J Indian Prosthodont Soc*. 2014;14(1):6-15.
 25. Bae S, Park M-S, Han J-W, Kim Y-J. Correlation between pain and degenerative bony changes on cone-beam computed tomography images of temporomandibular joints. *Maxillofac Plast Reconstr Surg*. 2017;39(1):19.
 26. Mani MF, Sivasubramanian SS. A study of temporomandibular joint osteoarthritis using computed tomographic imaging. *Biomed J*. 2016;39(3):201–6.
 27. Talaat W, Bayatti SA, Kawas SA. CBCT analysis of bony changes associated with temporomandibular disorders. *Cranio*. 2016;34(2):88–94.
 28. Nah KS. Condylar bony changes in patients with temporomandibular disorders: a CBCT study. *Imaging Sci Dent*. 2012;42(4):249–53.
 29. Shahidi S, Salehi P, Abedi P, Dehbozorgi M, Hamedani S, Berahman N. Comparison of the bony changes of TMJ in patients with and without TMD complaints using CBCT. *J Dent Shiraz Univ Med Sci*. 2018;19(2):142-9.

Joko Kusnoto FKG

The Correlation between Mandibular Condyle Shape and Temporomandibular Joint Conditions in Adult Females

Artikel 1

Document Details

Submission ID

trn:oid::3618:137709384

Submission Date

May 5, 2026, 11:18 AM GMT+7

Download Date

May 5, 2026, 11:34 AM GMT+7

File Name

2020 Correlation Mandibular Condyle Shape (CA SINTA 3).pdf

File Size

1.4 MB

9 Pages

4,022 Words

21,779 Characters

6% Overall Similarity

The combined total of all matches, including overlapping sources, for each database.

Filtered from the Report

- ▶ Bibliography
- ▶ Quoted Text
- ▶ Small Matches (less than 15 words)

Exclusions

- ▶ 3 Excluded Sources

Match Groups

- 6 Not Cited or Quoted** 5%
Matches with neither in-text citation nor quotation marks
- 2 Missing Quotations** 1%
Matches that are still very similar to source material
- 0 Missing Citation** 0%
Matches that have quotation marks, but no in-text citation
- 0 Cited and Quoted** 0%
Matches with in-text citation present, but no quotation marks

Top Sources

- 4% Internet sources
- 3% Publications
- 4% Submitted works (Student Papers)

Integrity Flags

0 Integrity Flags for Review

Our system's algorithms look deeply at a document for any inconsistencies that would set it apart from a normal submission. If we notice something strange, we flag it for you to review.

A Flag is not necessarily an indicator of a problem. However, we'd recommend you focus your attention there for further review.

Match Groups

- **6 Not Cited or Quoted 5%**
Matches with neither in-text citation nor quotation marks
- **2 Missing Quotations 1%**
Matches that are still very similar to source material
- **0 Missing Citation 0%**
Matches that have quotation marks, but no in-text citation
- **0 Cited and Quoted 0%**
Matches with in-text citation present, but no quotation marks

Top Sources

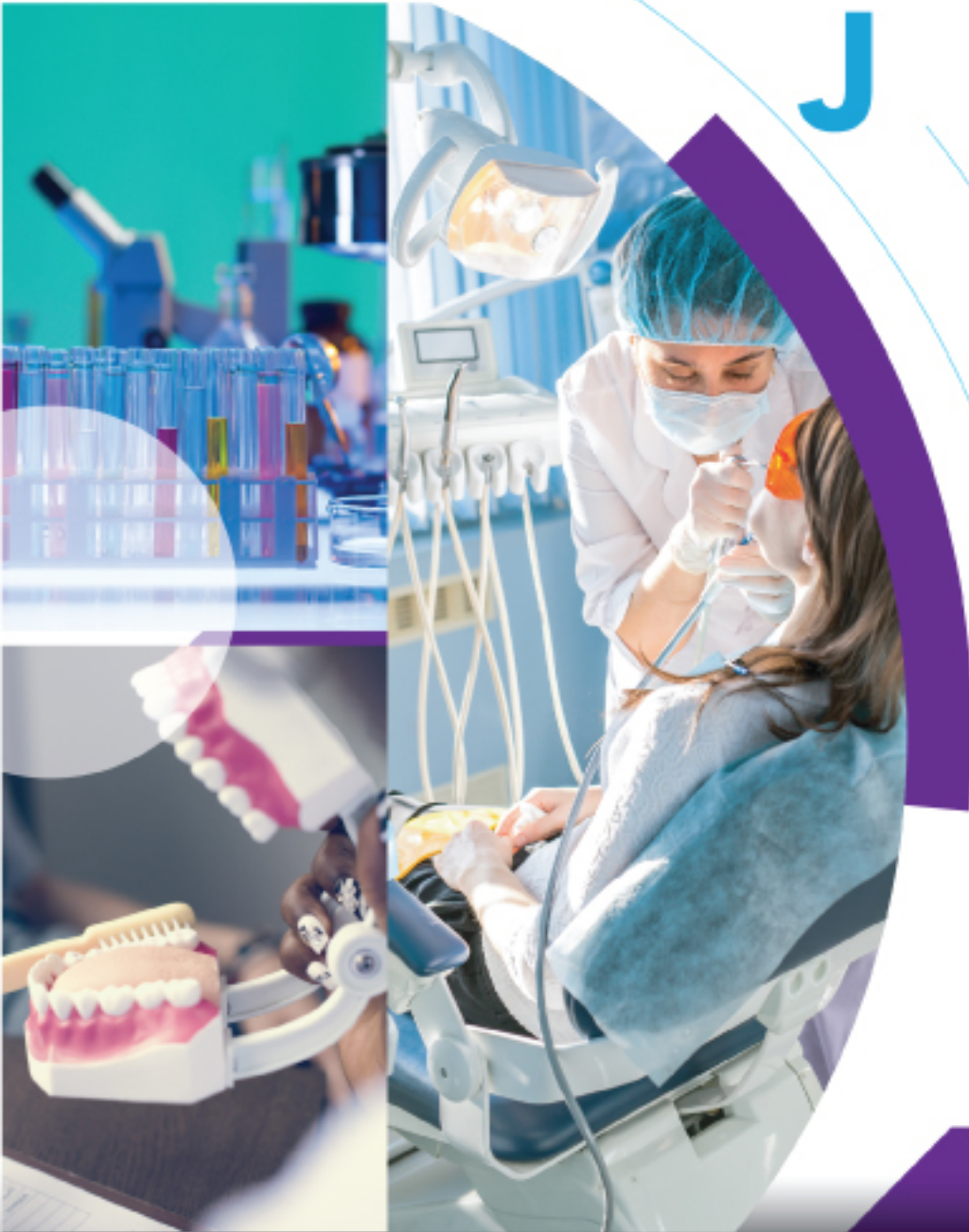- 4% Internet sources
- 3% Publications
- 4% Submitted works (Student Papers)

Top Sources

The sources with the highest number of matches within the submission. Overlapping sources will not be displayed.

1	Student papers		
	Universitas Prof. Dr. Moestopo (Beragama) on 2021-08-23	1%	
2	Student papers		
	Universitas Airlangga on 2021-04-21	1%	
3	Student papers		
	Universitas Indonesia on 2019-12-11	<1%	
4	Student papers		
	Universitas Prof. Dr. Moestopo (Beragama) on 2021-11-03	<1%	
5	Internet		
	journals.iium.edu.my	<1%	
6	Internet		
	journals.umkt.ac.id	<1%	
7	Publication		
	MA Sümbüllü, F Çağlayan, HM Akgül, AB Yılmaz. "Radiological examination of the ...	<1%	
8	Publication		
	D. Luo, Z. Yang, C. Qiu, Y. Jiang, R. Zhou, J. Yang. "A magnetic resonance imaging s...	<1%	

J I D A



JOURNAL OF INDONESIAN DENTAL ASSOCIATION



[Home](#) / [Editorial Team](#)

EDITOR IN-CHIEF

Armelia Sari Widyarman, [\[57203892772\]](#) Department of Microbiology, Division of Oral Biology, Faculty of Dentistry, Trisakti University, Indonesia

BOARD OF EDITORS

Citra Fragrantia Theodora, [\[57190048861\]](#) Department of Oral Biology, Faculty of Dentistry, University of Indonesia, Indonesia

Muhamad Orliando Roeslan, [\[57202022094\]](#) Department of Histology, Faculty of Dentistry, Trisakti University, Indonesia

Muhammad Ihsan Rizal, Department of Biochemistry and Molecular Biology, Faculty of Dentistry, Trisakti University, Indonesia

Rosa Amalia, [\[48461008800\]](#) Department of Preventive and Community Dentistry, Faculty of Dentistry, Gadjah Mada University, Indonesia

Rahmi Amtha, [\[26031894400\]](#) Department of Oral Medicine, Faculty of Dentistry, Trisakti University, Indonesia

Yosi Kusuma Eriwati Arianto, Department of Dental Material, Faculty of Dentistry, Universitas Indonesia, Indonesia

SERTIFIKAT AKREDITASI

[Editorial Team](#)[Board of Reviewers](#)[Focus and Scope](#)[Author Fees](#)[Publication Ethics](#)[Peer Review Process](#)[Author Guidelines](#)[Plagiarism Screening Policy](#)[Open Access Policy](#)[Conflict Of Interest Policy](#)[Copyright Notice](#)[Unique Visits](#)



Current Issue

Vol 3 No 2 (2020): October

Published: 2020-10-30

Research Article

The Correlation between Mandibular Condyle Shape and Temporomandibular Joint Conditions in Adult Females

Dominica Dian Saraswati Sumantri, Rosalina Tjandrawinata, Joko Kusnoto

55-60

[PDF](#)

The Effect of Curcuma zedoaria Extract on Enterococcus faecalis

Danica Anastasia, Aina Desmarani, Merryca Bellinda

61-64

[PDF](#)

Effect of Ethanol Extracts from Persea americana Leaves on HSC-3 Proliferation

Svetlana Tesselonica, Moehamad Orliando Roeslan

65-70

[PDF](#)

SERTIFIKAT AKREDITASI



[Editorial Team](#)

[Board of Reviewers](#)

[Focus and Scope](#)

[Author Fees](#)

[Publication Ethics](#)

[Peer Review Process](#)

[Author Guidelines](#)


[Plagiarism Screening Policy](#)

[Open Access Policy](#)

[Conflict Of Interest Policy](#)

[Copyright Notice](#)

[Unique Visits](#)



Research Article

The Correlation between Mandibular Condyle Shape and Temporomandibular Joint Conditions in Adult Females

Dominica Dian Saraswati Sumantri^{1,2}, Rosalina Tjandrawinata³, Joko Kusnoto^{4,5}

¹ Postgraduate program of Dental Science, Faculty of Dentistry, Trisakti University, Jakarta, Indonesia

² Department of Dentomaxillofacial Radiology, Faculty of Dentistry, Maranatha Christian University, Indonesia

³ Department of Dental Material, Faculty of Dentistry, Trisakti University, Jakarta, Indonesia

⁴ Department of Orthodontic, Faculty of Dentistry, Trisakti University, Jakarta, Indonesia

Received date: February 21, 2020. Accepted date: June 18, 2020. Published date: October 30, 2020.

KEYWORDS

condyle shapes;
female adults;
panoramic radiograph;
temporomandibular joint;
temporomandibular joint
condition

ABSTRACT

Introduction: Conditions of the temporomandibular joint (TMJ) are affected by changes in movement and load during the joint's function, which can cause morphological changes in hard tissues, such as the condyle. Panoramic radiographs can provide an indication of changes in hard tissues in TMJ. **Objectives:** The aim of this study was to determine whether there was any correlation between mandibular condyle shapes as seen on panoramic radiographs and TMJ conditions in adult female participants. **Methods:** The participants of this study were 75 adult female patients who underwent a panoramic radiograph examination conducted at the Maranatha Dental Hospital Radiology Unit. The patients were clinically examined based on the Research Diagnostic Criteria for Clinical Temporomandibular Disorder (RDC/TMD) questionnaire and also their panoramic radiographs. The data from the patients were categorized into four groups according to the RDC/TMD: normal, muscle disorders, disc displacement, and other joint diseases. Next, the radiographs were analyzed by two observers to determine the condyle shapes. Condyle shapes were classified into four groups: ovoid, flat, erosion, and osteophyte. **Result:** This study showed that of 75 patients, the right TMJ was normal in 34 patients, 2 patients had muscle disorders, 24 demonstrated disc displacement, and 15 had other joint diseases. For the left side of the TMJ, 22 radiographs were normal, 2 revealed muscle disorders, 35 identified disc displacement, and 16 showed other joint diseases. There was a strong agreement between the two observers in determining the right ($\kappa=0.681$) and left condyle shapes ($\kappa=0.652$). All participants' findings indicated that condyle shapes and TMJ conditions are highly correlated for both the right ($\eta^2=0.889$) and left condyle ($\eta^2=0.762$). **Conclusion:** This study concluded that mandibular condyle shapes seen on panoramic radiographs and TMJ conditions in adult female participants were highly correlated.

⁵ Corresponding Author

E-mail address: j_kusno@hotmail.com (Kusnoto J)

DOI: [10.32793/jida.v3i2.597](https://doi.org/10.32793/jida.v3i2.597)

Copyright: ©2020 Sumantri DDS, Tjandrawinata R, Kusnoto J. This is an open access article distributed under the terms of the Creative Commons Attribution License, which permits unrestricted use, distribution, and reproduction in any medium provided the original author and sources are credited.

INTRODUCTION

The temporomandibular joint (TMJ) is an articular system located in the mandible and temporal bone that allows the mandible to function with a balanced dynamic mechanism.¹ TMJ disorders are influenced by many factors. These conditions can be symptomized by pain, masticatory muscle dysfunction, and bone changes.² TMJ disorders are community health problems that affect about 5–12% of the population, with the highest incidence in people from 20–40 years of age and the lowest prevalence rate in young and elderly patients.^{3,4}

One of the supporting modalities that is commonly used to diagnose TMJ disorders is radiological examination. TMJ disorders can be investigated using transcranial radiography, arthrography, computed tomography (CT), cone-beam computed tomography (CBCT), and magnetic resonance imaging (MRI).⁵ In Indonesia, the use of MRI to confirm the diagnose of TMJ disorders is rare since it is not widely available and the cost is considerably high. Instead, clinicians commonly rely on a panoramic radiographic examination to diagnose TMJ disorders.

Panoramic radiography has the advantages of greater availability, a lower cost, and the ability to image the entire lower one-third of the face. Due to these advantages, this modality is the most frequently used type of radiography for preliminary diagnosis purposes. Many studies have investigated TMJ disorders. Honda, Yoshiko, and Sasaki used panoramic radiography in 1994 to classify condyle head shapes. Their study showed that flattening has the highest rate of incidence in symptomatic TMJ disorders and also in patients with missing molars and premolars.⁶

In 2016, Borahan et al. reported that in a Turkish population, the normal shape of the mandibular condyle was oval.⁷ Another study that carried out panoramic radiograph examinations in patients with TMJ disorders both with and without clicking showed that there was no significant difference between with and without clicking groups.⁸ Obamiyi et al. investigated five racial groups and noted the frequent occurrence of condyle anomalies in Chinese patients compared to those from other races.⁹

These previous studies emphasized the need to know how condyle shapes affect TMJ disorders. Therefore, this study aimed to determine whether there was any correlation between the mandibular condyle shapes identified on panoramic radiographs and the incidence of TMJ conditions in adult female participants. This information will be important in supporting radiological interpretation, the prevention of diseases, and clinical care decisions.

MATERIAL AND METHODS

This study was an observational analytic study with a cross-sectional design. The study was conducted at the Maranatha Dental Hospital Radiology Unit. The ethical aspect of this research has been reviewed and approved by the Trisakti University Faculty of Dentistry Ethics Committee (Ethical Clearance No. 248/S2/KEPK/FKG/3/2019).

The study population included patients who came to the Maranatha Dental Hospital Radiology Unit for consultation and panoramic radiography. Samples were taken consecutively with inclusion criteria as follows: female patients ≥ 20 years of age; no prior history of trauma to the jaws, head, or neck; panoramic radiographs with complete imaging of the condyle, eminentia articularis, glenoid fossa, and meatus acusticus internus bilaterally.

The condition of the TMJ system was evaluated during a clinical examination and recorded according to the Research Diagnostic Criteria for Clinical Temporomandibular Disorder (RDC/TMD) questionnaire. The conditions of TMJ disorders were categorized as follows: Group 0: normal; Group 1: muscle disorders; Group 2: disc displacement; Group 3: arthralgia/arthritis/arthrosis.

Condyle shape data were collected by tracing the outer edge of the condyle on panoramic radiographs using Morita Veraviewpocs 3D R100 software (J. Morita Corp, Japan). The condyles were then categorized into ovoid, flat, erosion, or osteophyte shapes (Fig. 1).

The measurement of the mouth opening was carried out using a zero-pointed ruler (0) placed at the distance between the incisal maxillary incisors and the lower jaw. The patient was asked to make lateral biting movements to the right and left, and then the difference between the maxillary and mandibular labio-incisal embrasure was measured. The patient was asked to state the level of pain when the jaw was palpated in the upper back region of the ear, the lateral border of the eyebrows, above the cheekbones, under the cheekbones up to the mandibular angle, and the neck. These data were used to determine the TMJ condition along with the RDC/TMD algorithm.

If a patient reported having pain in the past month, then the level of pain in the extraoral and intraoral muscles was summed. If the muscle pain felt by the patient was present in three or more muscles and was located unilaterally, the vertical range of motion distance that could be achieved without pain and overlapping was added. In addition, results ≥ 40 mm were categorized as myofascial pain. A sum of < 40 mm was reached by

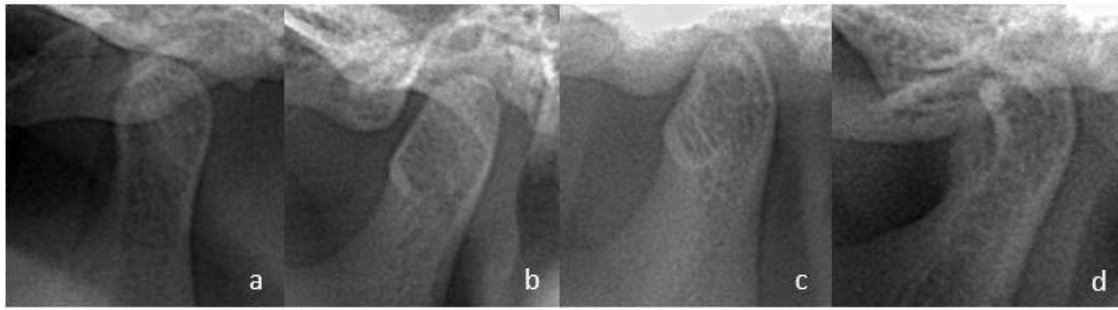


Figure 1. Condyle shape category. a. Ovoid. The condyle has convexity on its anterior, posterior, and superior aspects. b. Flat. The condyle has a flat contour that deviates from the convexity of the condyle’s anterior/superior/posterior parts. c. Erosion. The condyle has a radiolucent appearance at the cortical (radiopaque) edge of the condyle head. d. Osteophyte. The condyle has a sharp radiopaque image resembling a notch on its outer edge.

calculating the vertical range of motion with the help of the operator minus the vertical range of motion without pain. Any results with a difference of < 5 mm were categorized as myofascial pain, while a > 5 mm difference was classified as myofascial pain with limited opening. Participants with myofascial pain and myofascial pain with limited opening were placed in Group 1.

Group 2 was distinguished by the presence or absence of clicking in the vertical range of motion. If clicking was found, then it was necessary to identify whether it occurred only when opening or closing the mouth or during both actions. If clicking occurred when opening and closing the mouth, then the difference between the distance of the clicking sound when opening or closing the mouth was calculated. In addition, any difference between the opening and closing of the mouth with clicking ≥ 5 mm with a loss of clicking when opening with protrusive movement or a difference between the opening and closing of the mouth with clicking and closing that was < 5 mm and was accompanied by clicking with lateral movement was included in the disc displacement. If no clicking was found when opening or closing the mouth, but a history of limited mouth opening was present, the patient was included in the disc displacement category except when no deviation or deflection and joint sounds were found. Patients who reported pain during palpation or complained of pain were included in Group 3 unless crepitus was not found during joint movement. Any patients who did not fit in with the Group 1 algorithm proceeded to the Group 2 and Group 3 algorithms for assessment.

Two dental radiology specialists who agreed on the landmarks of the radioanatomy section from the panoramic radiographs determined the condyle shape by tracing the condyle exactly on the radiopaque line of the edge of the condyle. The two observers’ validity and reliability in determining the condyle shape were tested

using a double-blinded procedure for the first 30 samples. A Kappa test was carried out to verify the validity and reliability. In addition, an Eta-squared test was conducted to determine the relationship between TMJ conditions and condyle shapes. (SPSS, Chicago, IL).

RESULTS

The Kappa test results showed strong agreement between the observers with $\kappa = 0.681$ for right condyle shapes and $\kappa = 0.652$ for left condyle shapes. The number of participants in each TMJ condition can be seen in Table 1. The distribution of right and left TMJ disorders based on the condylar shape shown on the panoramic radiographs can be seen in Table 2.

The Eta-squared value between condylar shape and right-sided TMJ conditions was $\eta^2=0.889$. The F count (187,326) was larger than the F table, which indicated a very strong relationship between condylar shapes and right-sided TMJ conditions. The Eta-squared value between condylar shape and left-sided TMJ conditions was $\eta^2=0.762$. The F count (44,846) was larger than the F table, which suggested that there was a very strong relationship between condyle shapes and left-sided TMJ conditions.

Table 1. Participants’ right and left TMJ conditions grouped by RDC/TMD criteria.

TMJ condition	Number of Patients	
	Right TMJ	Left TMJ
Group 0	34	22
Group 1	2	2
Group 2	24	35
Group 3	15	16

Group 0: Normal; Group 1: Muscle Disorders; Group 2: Disc Displacement; Group 3: Athralgia/athritis/arthrosis

Table 2. The distribution of right- and left-side TMJ conditions grouped by condyle shapes.

TMJ Condition	Condyle Shape							
	Ovoid		Flat		Erosion		Osteophyte	
	R	Left	Right	Left	Right	Left	Right	Left
Group 0	34	21	-	-	-	-	-	1
Group 1	-	-	2	2	-	-	-	-
Group 2	4	16	20	19	-	-	-	-
Group 3	-	-	4	4	7	8	4	4

Group 0: Normal; Group 1: Muscle Disorders; Group 2: Disc Displacement; Group 3: Athralgia/athritis/arthritis

DISCUSSION

Panoramic radiography is a radiological technique that provides an overview of the jaw and its surrounding tissues and allows dentists to see a large area, including the maxilla and mandible, in just one radiograph.¹⁰ Panoramic radiography is useful for the early detection of defects before proceeding to further radiological examination. In temporomandibular cases, panoramic radiography may reveal a picture of advanced bone changes and is indicated in patients who have minimal mouth opening.¹¹

In this study, all female patients were over the age of 20 years. Previous studies have shown many TMJ disorders in women of reproductive age.¹² Hormonal, social, and cultural factors, along with stress levels, are thought to be the triggers for TMJ disorders.¹³ Levels of estrogen and prolactin hormones are influenced by changes in a woman's quality of life, which also affects stress levels, especially in women from 24–33 years.¹⁴ Increased levels of estrogen can reduce pain in TMJ disorders, while decreases in estrogen will increase pain.¹⁵ Estrogen and prolactin stimulate chondrogenesis and maintain chondrocytes against apoptosis. If there is a decrease in the levels of both hormones, degradation of cartilage and articular bones may occur.¹⁶ All of these conditions were identified in our patients' age group.

The results of our examination of TMJ conditions using the RDC/TMD questionnaire indicated that most of the right-sided TMJs were normal, while the left TMJ side was more likely to show conditions associated with disc displacement. These results indicate the possibility that TMJ disorders that only affect one side have a higher prevalence than TMJ disorders that affect both sides.¹⁷ One explanation for this finding is that some patients have a habit of chewing only on one side. Usually, the side that makes broader movements is more lubricated and therefore has a better metabolic exchange than the immobile side.¹⁸ The associated joint overload causes the

condyle to change shape by increasing the condyle surface area that is in contact with the articular surface so that the load received is lighter.¹⁹

Anatomically, the TMJ has several components including joint capsules, extracapsular ligaments, articular eminence, glenoid fossa, condyle, disc, ligamentous discs, and synovial membranes.²⁰ The mandibular condyle is part of the mandible, which is located in the glenoid fossa and affects the opening and closing movements of the mouth. In patients with TMJ disorders, there is a translation movement when first opening the mouth and then again at the end of the motion when closing the mouth. Sudden changes in movement that allow the condyle to return to its normal position cause a clicking sound when the mouth is opening or closing. If this condition persists, there will be an increase in joint dysfunction, which causes changes in disc morphology and produces secondary clicking sounds.²¹ The change in disc morphology will be followed by a biomechanical reaction in the TMJ.²²

Based on the distribution of condyle shapes in this study, most patients with normal TMJ conditions had an ovoid condyle shape. However, one of the research participants in Group 2 had an osteophyte condyle shape on the left side and a right side with a TMJ condition. This finding indicates that these disorders possibly cause a long-term change in joint movements, so the body begins to adapt to improve the joint. Osteophytes are formed as an expansion of the joint surface to stabilize the power load.²³ Subsequently, the patient showed facial skeleton remodeling, deviation of the affected area, unstable malocclusion, and occlusal discrepancy.²⁴

All condyle shapes in Group 1 were flat, while in Group 2, the condyle shapes found were flat and ovoid. In Group 3, three kinds of condyle shapes were identified: erosion, flat, and osteophyte. Sclerosis and pseudocyst condyle shapes were not present in any participants. The pseudocyst shape was thought to be an

advanced form of erosion distinct from the osteophyte shape.²⁵ Previous investigations into disc displacement and osteoarthritis suggest that osteoarthritis is a continuation of disc displacement.²⁶ Flat and sclerosis shapes on the surface of condyles are a sign of remodeling and increased load. Erosion is the early stage of a degenerative change.²³ Previous studies using CBCT have reported that flat and osteophyte condyle shapes are commonly found in cases of degenerative joint disorders.²⁷ Degenerative joint disorders are also caused by inflammatory processes. In addition, mechanical and metabolic factors play a role in the initial damage to the cartilage. These factors will initiate biomechanical changes in hard and soft tissues in the joint, which provoke an immune response that leads to the secretion of inflammatory mediators.²³ Chondrocytes will release mechanical responsive mechanisms, so metabolic mechanisms and pathological activation will increase and result in irreversible cartilage degradation.²²

This study showed that there was a relationship between condyle shapes and TMJ disorders. This conclusion is different from those of previous studies that have identified a poor correlation between condyle changes, pain, and other clinical symptoms in TMJ osteoarthritis.²⁸ This difference likely occurred because condyle shapes in this study were grouped based on the presence of any TMJ condition without dividing them into groups by factors of TMJ disorder symptoms. Different relationships between the right and left TMJ show that conditions that may produce clinical findings are not directly reflected in the radiograph.²⁹ The duration of TMJ disorders and factors involved with the contralateral side may also affect the radiograph's appearance. Symptoms may be detected only on one side, but the radiograph may indicate involvement on the other side.²⁵

CONCLUSION

This study found that mandibular condylar shapes revealed by panoramic radiography and the presence of TMJ conditions in adult female patients were highly correlated. In future studies, it will be necessary to investigate etiological factors that may indicate the existence of other TMJ disorders. It is also important to use other modalities, such as panoramic radiography specially developed for TMJ or CBCT, which will be more accurate in supporting the diagnosis of TMJ disorders.

CONFLICT OF INTEREST

The authors declare that there is no conflict of interest related to this study.

ACKNOWLEDGMENT

The authors would like to thank the Department of Dentomaxillofacial Radiology Maranatha Christian University Dental Hospital and Faculty of Dentistry for their continuous support.

REFERENCES

1. Sümbüllü M, Çağlayan F, Akgül H, Yılmaz A. Radiological examination of the articular eminence morphology using cone beam CT. *Dentomaxillofac Radiol.* 2012;41(3):234–40.
2. Veerappan R, Gopal M. Comparison of the diagnostic accuracy of CBCT and conventional CT in detecting degenerative osseous changes of the TMJ: A systematic review. *J Indian Acad Oral Med Radiol.* 2015;27(1):81-4.
3. Schiffman EL, Truelove EL, Ohrbach R, Anderson GC, John MT, List T, et al. The research diagnostic criteria for temporomandibular disorders: overview and methodology for assessment of validity. *J Orofac Pain.* 2010;24(1):7–24.
4. Schiffman EL, Ohrbach R, Truelove EL, Look JO, Anderson GC, Goulet JP, et al. Diagnostic criteria for temporomandibular disorders (DC/TMD) for clinical and research applications: Recommendations of the international RDC/TMD consortium network and orofacial pain special interest group. *J Oral Facial Pain H.* 2014;28(1):6–27.
5. Pietra LCF, Santiago M de O, Valerio CS, Taitson PF, Manzi FR, Seraidarian PI. Use of transcranial radiograph to detect morphological changes in mandibular condyles. *Rev CEFAC.* 2017;19(1):54–62.
6. Honda E, Yoshino N, Sasaki T. Condylar appearance in panoramic radiograms of asymptomatic subjects and patients with temporomandibular disorders. *Oral Radiol.* 1994;10(2):43–53.
7. Borahan MO, Mayil M, Pekiner FN. Using cone beam computed tomography to examine the prevalence of condylar bony changes in a Turkish subpopulation. *Niger J Clin Pract.* 2016;19(2):259–66.
8. Pramanik F, Firman RN, Sam B. Differences of temporomandibular joint condyle morphology with and without clicking using digital panoramic radiograph. *Padjadjaran J Dent.* 2016;28(3); 153-8.
9. Obamiyi S, Malik S, Wang Z, Singh S, Rossouw E P, Fishman L, et al. Radiographic features associated with temporomandibular joint disorders among African, White, Chinese, Hispanic, and Indian racial groups. *Niger J Clin Pract.* 2018;21(11):1495-500.
10. Capote TSO, Gonçalves MA, Gonçalves A, Gonçalves M. Panoramic radiography-diagnosis of

- relevant structures that might compromise oral and general health of the patient. In: Viridi MS, editor. *Emerging trends in oral health sciences and dentistry*. Rijeka (Croatia): InTech; 2015. pp. 734-62.
11. Ferreira LA, Grossmann E, Januzzi E, de Paula MVQ, Carvalho ACP. Diagnosis of temporomandibular joint disorders: indication of imaging exams. *Braz J Otorhinolaryngol*. 2016;82(3):341–52.
 12. Ahmad M, Chalkoo A. Possible role of estrogen in temporomandibular disorders in female subjects: A research study. *J Indian Acad Oral Med Radiol*. 2014;26(1):30-3.
 13. Bueno CH, Pereira DD, Pattussi MP, Grossi PK, Grossi ML. Gender differences in temporomandibular disorders in adult populational studies: A systematic review and meta-analysis. *J Oral Rehabil*. 2018;45(9):720–29.
 14. Pereira TC, Brasolotto AG, Conti PC, Berretin-Felix G. Temporomandibular disorders, voice and oral quality of life in women. *J Appl Oral Sci*. 2009;17(spe):50–6.
 15. Oliveira JA, Gonçalves TMSV, Vilanova LSR, Ambrosano GMB, Garcia RCMR. Female hormones fluctuation and chewing movement of patients with disc displacement. *Rev Odonto Ciênc*. 2012;27(1):20–5.
 16. Hegde S, Rao G, Sattur A, Nandimath K, Shetty R, Madi M. Role of digital volumetric tomography in assessing morphological variations in condyle and temporal components of patients with asymptomatic temporomandibular joint. *J Indian Acad Oral Med Radiol*. 2019;31(2):140-6.
 17. Progiante P, Pattussi M, Lawrence H, Goya S, Grossi P, Grossi M. Prevalence of temporomandibular disorders in an adult Brazilian community population using the research diagnostic criteria (Axis I and II) for temporomandibular disorders (The Maringá Study). *Int J Prosthodont*. 2015;28(6):600–9.
 18. Santana MU, López CJ, Mora MJ, Otero XL, Santana PU. Temporomandibular disorders: the habitual chewing side syndrome. *PLoS ONE*. 2013;8(4):e59980.
 19. Kuo C, Takahashi M, Maki K. Relationships among occlusal force, condylar surface area, and facial patterns. *Dent Med Res*. 2013;33(2):169–77.
 20. David CM, Elavarasi P. Functional anatomy and biomechanics of temporomandibular joint and the far-reaching effects of its disorders. *J Adv Clin Res Insights*. 2016;3(3):101–6.
 21. Ivkovic N, Racic M. Structural and functional disorders of the temporomandibular joint (Internal disorders). *IntechOpen*. 2018;1-26.
 22. Kuroda S, Tanimoto K, Izawa T, Fujihara S, Koolstra JH, Tanaka E. Biomechanical and biochemical characteristics of the mandibular condylar cartilage. *Osteoarthritis Cartil*. 2009;17(11):1408–15.
 23. Krisjane Z, Urtane I, Krumina G, Neimane L, Ragovska I. The prevalence of TMJ osteoarthritis in asymptomatic patients with dentofacial deformities: a cone-beam CT study. *Int J Oral Maxillofac Surg*. 2012;41(6):690–5.
 24. Kalladka M, Quek S, Heir G, Eliav E, Mupparapu M, Viswanath A. Temporomandibular joint osteoarthritis: diagnosis and long-term conservative management: a topic review. *J Indian Prosthodont Soc*. 2014;14(1):6-15.
 25. Bae S, Park M-S, Han J-W, Kim Y-J. Correlation between pain and degenerative bony changes on cone-beam computed tomography images of temporomandibular joints. *Maxillofac Plast Reconstr Surg*. 2017;39(1):19.
 26. Mani MF, Sivasubramanian SS. A study of temporomandibular joint osteoarthritis using computed tomographic imaging. *Biomed J*. 2016;39(3):201–6.
 27. Talaat W, Bayatti SA, Kawas SA. CBCT analysis of bony changes associated with temporomandibular disorders. *Cranio*. 2016;34(2):88–94.
 28. Nah KS. Condylar bony changes in patients with temporomandibular disorders: a CBCT study. *Imaging Sci Dent*. 2012;42(4):249–53.
 29. Shahidi S, Salehi P, Abedi P, Dehbozorgi M, Hamedani S, Berahman N. Comparison of the bony changes of TMJ in patients with and without TMD complaints using CBCT. *J Dent Shiraz Univ Med Sci*. 2018;19(2):142-9.


[JIDA] Acceptance Letter

Journal of Indonesian Dental Association <jida.indonesia@pdgi.or.id>

Wed 6/24/2020 4:07 PM

To:Joko Kusnoto <j_kusno@hotmail.com>

Cc:Armelia Sari <armeliasari@trisakti.ac.id>

 1 attachments (93 KB)

[JIDA] Copyright Agreement Form.dot;

Dear Dr. Joko Kusnoto,

It's a great pleasure for me to inform you that your manuscript titled "Corellation between Mandibular Condyle Shape and The Temporomandibular Joint Condition in Adult Females" has been accepted and will be finalized for publication in our next issue of 2020; volume 3 number 2.

Please send us the copyright agreement form signed by all authors as attached.

Thank you for your kind cooperation.

Sincerely yours,

Armelia Sari Widyarman

Editor in-Chief

Journal of Indonesian Dental Association

armeliasari@trisakti.ac.id ; armeliasari.dr@gmail.com

<http://jurnal.pdgi.or.id/index.php/jida>


[JIDA] Author Proof

Journal of Indonesian Dental Association <jida.indonesia@pdgi.or.id>

Wed 10/21/2020 2:05 PM

To:Joko Kusnoto <j_kusno@hotmail.com>

Cc:Armelia Sari <armeliasari@trisakti.ac.id>

 2 attachments (1,010 KB)

[JIDA] Proofs Corrections.dot; 5 JIDA_52_OA.pdf;

Dear Dr. Joko Kusnoto,

Your submission to Journal of Indonesian Dental Association needs a proofread in layout version.This is the last opportunity that you have to make substantial changes. Please upload the proof correction along with clarifications for all the comments, clearly indicating the areas where the changes have been made.

The proofread itself is due October 23, 2020.

We greatly appreciate your confirmation and thank you very much for submitting your article to the Journal of Indonesian Dental Association.

Sincerely yours,

Armelia Sari Widyarman

Editor in-Chief

Journal of Indonesian Dental Association

armeliasari@trisakti.ac.id ; armeliasari.dr@gmail.com

<http://jurnal.pdgi.or.id/index.php/jida>