





Article Text



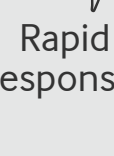
Article info



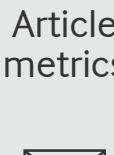
Citation Tools




Share



Rapid Responses



Article metrics



Alerts

Case Reports: Reminder of important clinical lesson



# Reconstruction of multiple fingertip crush injuries with full-thickness skin grafting

Erica Kholinne<sup>1, 2</sup>, Claudia Santosa<sup>2</sup>, Ira Juliet Anestessia<sup>1</sup> and Muchtar<sup>1</sup>

Correspondence to Dr Erica Kholinne; [erica@trisakti.ac.id](mailto:erica@trisakti.ac.id)

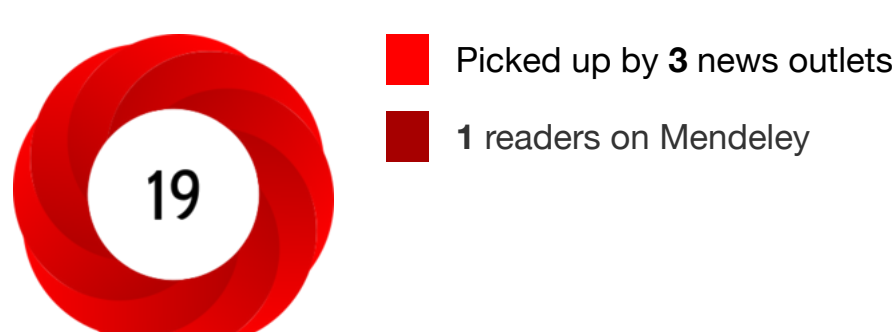## Abstract

Fingertip crush injuries are commonly encountered as a result of workplace accidents causing significant morbidity. The primary goal of reconstruction is to restore function and sensibility, as well as a faster return to work. We reported a patient with multiple fingertip injuries presented 5 days following the initial injury. Copious irrigation and excisional debridement were performed, followed by a full-thickness skin graft harvested from the volar wrist. At the 4-month follow-up, all of the reconstructed fingertips achieved good functionality without any pain or sensory impairment. The length was well preserved and static two-point discrimination was comparable with the contralateral side. Full-thickness skin grafts may provide an excellent alternative reconstruction option in the management of multiple fingertip crush injuries.



<https://doi.org/10.1136/bcr-2022-253446>

## Statistics from Altmetric.com



[See more details](#)

## Request Permissions

If you wish to reuse any or all of this article please use the link below which will take you to the Copyright Clearance Center's RightsLink service. You will be able to get a quick price and instant permission to reuse the content in many different ways.

[Request permissions](#)

[View Full Text](#)

## Footnotes

**Contributors:** Supervised by EK. The patient was under the care of EK. Report was written by CS, IJA and M.

**Funding:** The authors have not declared a specific grant for this research from any funding agency in the public, commercial or not-for-profit sectors.

Case reports provide a valuable learning resource for the scientific community and can indicate areas of interest for future research. They should not be used in isolation to guide treatment choices or public health policy.

**Competing interests:** None declared.

**Provenance and peer review:** Not commissioned; externally peer reviewed.

## Read the full text or download the PDF:

- [Buy this article \(£50\)](#)
- [Subscribe](#)
- [Log in](#)



### Salaried GP - Millbrook Surgery

Castle Cary, Somerset

Due to our continued growth a rare chance has arisen to join our team at Millbrook Surgery.

Recruiter: Millbrook Surgery

[Apply for this job](#)

### Family Physician opportunity in Alberta

Edmonton (City), Alberta (CA) | up to \$550,000 per annum

Family Practice Opportunity In Canada. Edgewater Medical clinic represents a group of family physicians and specialists practicing at City center l...

Recruiter: Mediclinics Inc.

[Apply for this job](#)

### Salaried GP (Up to 6 sessions) -

## Other content recommended for you

**A simple turnover technique to harvest skin graft from the avulsed skin**  
Ravikiran Naalla et al., Case Rep, 2017

**Delayed management of a ring finger injury by a thinned and tubed groin flap in a forward surgical unit**  
Georges Pfister et al., BMJ Military Health, 2022

**Caustic skin burn caused by sodium hydroxide**  
Murat Eroglu et al., Case Rep, 2012

**Not all is lost: journey of a deep periorbital burn**  
Swati Singh et al., Case Rep, 2017

**Severe traumatic scalp avulsion requiring an ommental free**

**Free thin sensate superficial circumflex iliac artery perforator flap based on lateral cutaneous branch of the subcostal nerve for repair of soft tissue defect in the foot and ankle**

Pan Zhaohui et al., Chinese Journal of Trauma, 2021

**External fixators combined with anterolateral thigh musculocutaneous flap for treatment of Gustilo type IIIB/C open tibiofibular fractures**

Zhang Songqiang et al., Chinese Journal of Trauma, 2021

**Work accidents and ill health cost society billions - new HSE report estimates**  
Facilities, 2000

**The business case for health and safety**

<b>CONTENT</b>	<b>JOURNAL</b>	<b>AUTHORS</b>	<b>HELP</b>
<a href="#">Latest content</a>	<a href="#">About</a>	<a href="#">Instructions for authors</a>	<a href="#">Contact us</a>
<a href="#">Archive</a>	<a href="#">Editorial board</a>	<a href="#">FAQs</a>	<a href="#">Reprints</a>
<a href="#">Top Cited articles</a>	<a href="#">Thank you to our reviewers</a>	<a href="#">Submit a paper</a>	<a href="#">Permissions</a>
<a href="#">Global Health</a>	<a href="#">Sign up for email alerts</a>	<a href="#">Editorial policies</a>	<a href="#">Advertising</a>
<a href="#">Browse by collection</a>	<a href="#">Fellowships</a>	<a href="#">Open Access at BMJ</a>	<a href="#">Feedback form</a>
<a href="#">Responses</a>		<a href="#">BMJ Author Hub</a>	

