



# A 12-Week Rehabilitation Protocol for the Management of Chronic Extensor Hallucis Longus Rupture Repaired with an Autograft of the Semitendinosus Tendon

Astuti Pitarini<sup>1</sup>, Mitchel<sup>2</sup>, Karina Sylvana Gani<sup>2</sup>, Ratna Moniqa<sup>1</sup>, Erica Kholinne<sup>1,3</sup>

<sup>1</sup>St. Carolus Hospital, Bone and Joint Centre, Jakarta, Indonesia

<sup>2</sup>Faculty of Medicine and Health Sciences, Atma Jaya Catholic University of Indonesia, Jakarta, Indonesia

<sup>3</sup>Department of Surgery, Faculty of Medicine, Universitas Trisakti, Jakarta, Indonesia

**Received** Aug 22, 2023  
**Revised** Oct 10, 2023  
**Accepted** Oct 11, 2023

#### Corresponding author

Erica Kholinne  
Department of Surgery, Faculty of  
Medicine, Universitas Trisakti, Jl. Kyai  
Tapa No.1, Jakarta 11440, Indonesia  
Tel: 62-21-565-5786  
Fax: 62-21-564-4270  
E-mail: erica@trisakti.ac.id

#### Key Words

Extensor hallucis longus tendon;  
Rupture; Hamstring tendons;  
Rehabilitation

Traumatic rupture of the extensor hallucis longus (EHL) is an uncommon finding in an outpatient setting. Surgical repair is typically necessary, particularly in chronic conditions that have persisted for six weeks or more. While several studies have reported EHL repair using autograft tendons, rehabilitation regimes vary, and standardized protocols have not yet been established. This case report presents with an inability to extend her left great toe. She underwent tendon reconstruction with an autograft semitendinosus tendon. At an 8-week follow-up, the patient reported greatly improved outcomes on the American Orthopaedic Foot and Ankle Society, Foot and Ankle Ability Measure, Foot and Ankle Disability Index questionnaire. Full recovery was achieved 12 weeks after surgery. The use of autograft semitendinosus tendon repair for chronic EHL tendon rupture, in conjunction with rehabilitation program, can be expected to yield favorable results.

## Introduction

The rupture of the extensor hallucis longus (EHL) tendon is a rare occurrence, typically resulting from direct open trauma to the dorsum of the foot or ankle [1]. However, certain risk factors such as diabetes, rheumatoid arthritis, local steroid injections, and iatrogenic accidents during ankle arthroscopy may contribute to this type of injury [1,2]. The classic triad of clinical manifestations for this condition includes a hallux flexion deformity, an inability to actively extend the hallux interphalangeal joint, and normal passive mobility. We report a case of delayed presentation of chronic EHL tendon rupture that necessitated a reconstructive procedure using a semitendinosus autograft. One of the advantages of using the semitendinosus tendon as a graft is its easy accessibility and its strong resemblance to the EHL tendon [3,4].

## Case

### 1. Preoperative evaluation

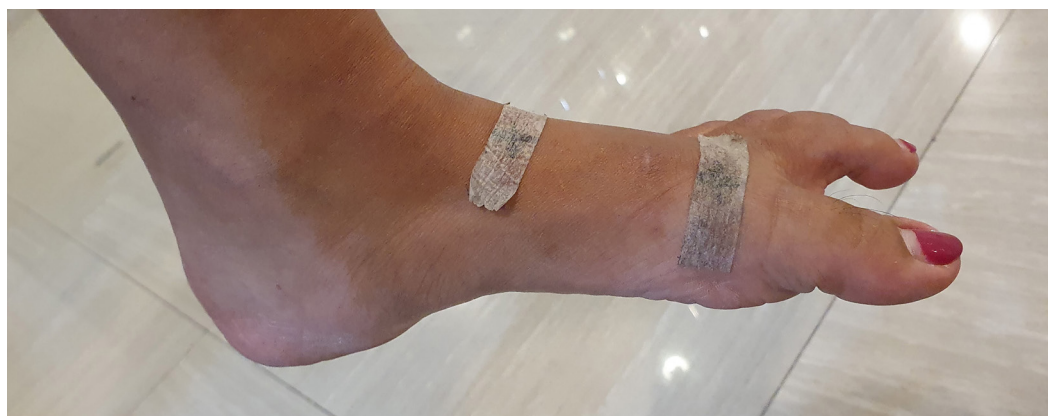A 29-year-old woman was hospitalized after she sustained an injury from a falling kitchen knife, which punctured her left hallux metatarsophalangeal (MTP) joint. Initially, she was seen in the emergency department where she was diagnosed with an open laceration. The wound was primarily sutured at this time. During her recovery, she found herself unable to extend her left great toe while walking. As a result, she visited the surgery outpatient clinic and was subsequently referred to an orthopedic doctor due to a suspected tendon injury. This diagnosis was later confirmed through a clinical examination conducted by the orthopedic doctor.

The physical examination revealed that the patient had difficulty walking barefoot due to an issue with her left leg. Her left big toe displayed a plantar flexion deformity, and she was unable to actively dorsiflex her first interphalangeal joint (Fig. 1). However, passive dorsiflexion was possible with a full range of motion. The sensory function of the entire foot appeared to be normal. The MTP joint demonstrated a normal range of both active and passive motion. An ultrasound examination revealed a complete rupture of the EHL tendon, which had retracted approximately 6 cm from the tendon's edge (Fig. 2).

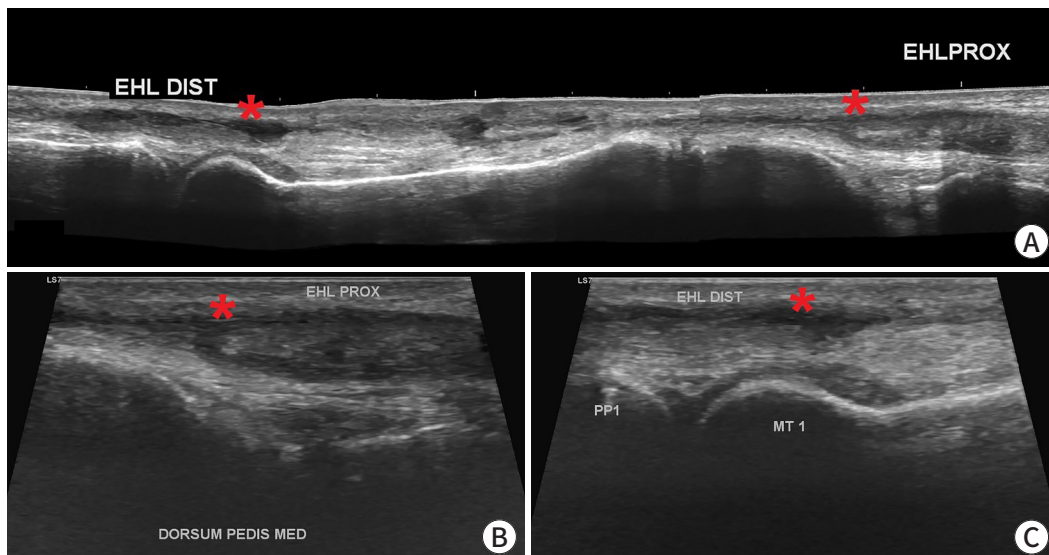
### 2. Surgical procedure

Surgery was performed with the patient in a supine position under regional anesthesia. A non-sterile thigh tourniquet was applied, set at 300 mmHg. An incision, measuring 8 cm, was made dorsally along the path of the EHL. This incision extended from the level of the MTP joint to the proximal EHL, with careful consideration to avoid the dorsocutaneous nerve. The proximal edge of the EHL tendon site was found to be adhered to the fat tissue. Dissection was carried out to liberate the proximal EHL from this adhesion. The gap between the proximal and distal stumps was measured to be 6 cm (Fig. 3).

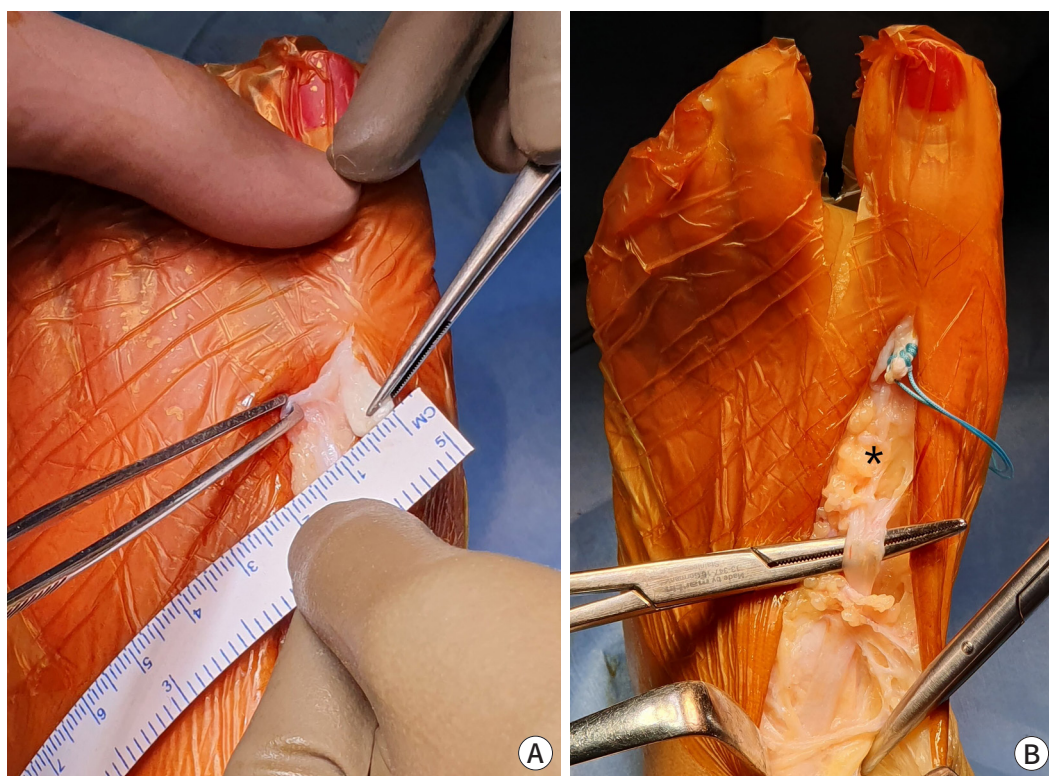
A tendon stripper was used to harvest a 250-mm length of the semitendinosus tendon from the ipsilateral side. The harvested tendon was then sutured to the ends of the EHL tendon using the Pulvertaft and Kessler technique (Fig. 4A, B). After suturing, the tendon was carefully tensioned to ensure adequate extension of the great toe (Fig. 4C). The vitality and function of the EHL were assessed using a nerve stimulation machine set at 2.0  $\mu$ V, which confirmed positive movement and functionality of the EHL tendon (Fig. 4D).



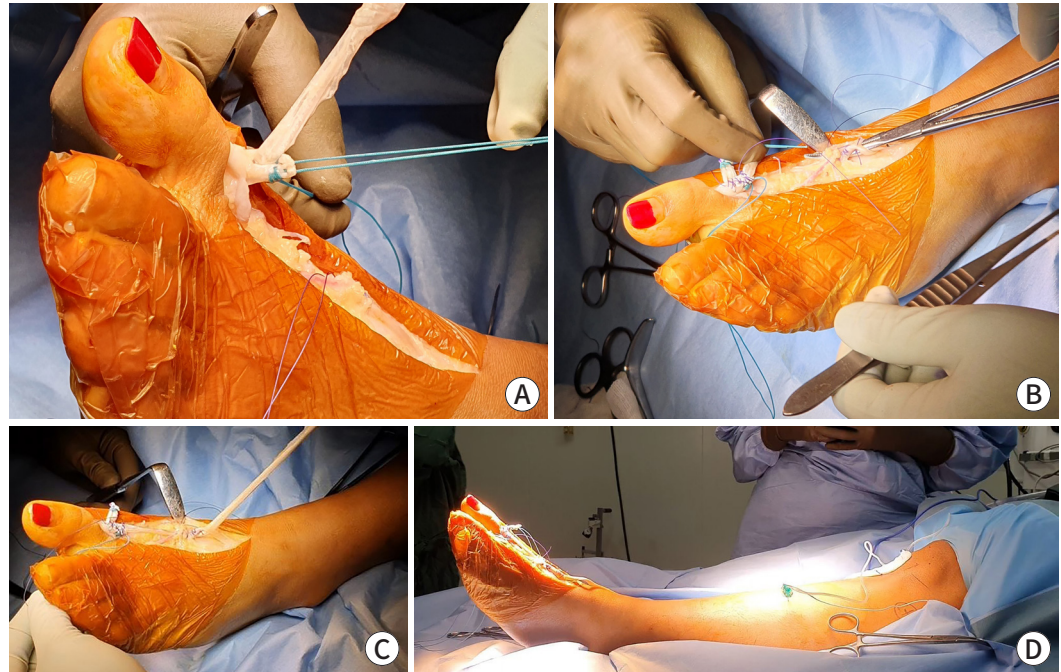
**Fig. 1.** Clinical presentation of the patient's left foot reveals hallux flexion deformity.



**Fig. 2.** Preoperative ultrasonography was performed to evaluate the integrity of the extensor hallucis longus (EHL). (A) Longitudinal ultrasound imaging of the dorsal aspect of the left ankle showed complete rupture of the EHL tendon with a gap between the stumps (asterisk). (B) The proximal stump (asterisk) of the torn EHL tendon was at the medial cuneiform level. (C) The distal stump (asterisk) of the torn EHL tendon was isolated at the metatarsal level. EHL DIST, distal EHL; EHL PROX, proximal EHL; DORSUM PEDIS MED, dorsum pedis medial; PP1, proximal phalanx 1; MT1, metatarsal 1.



**Fig. 3.** Intraoperative findings. (A) Intraoperative view shows that the distal extensor hallucis longus (EHL) tendon width was 5 mm. (B) The gap between the proximal and distal EHL tendon stump was 6 cm; it is noteworthy that the proximal stump adhered to the fat tissue (asterisk).

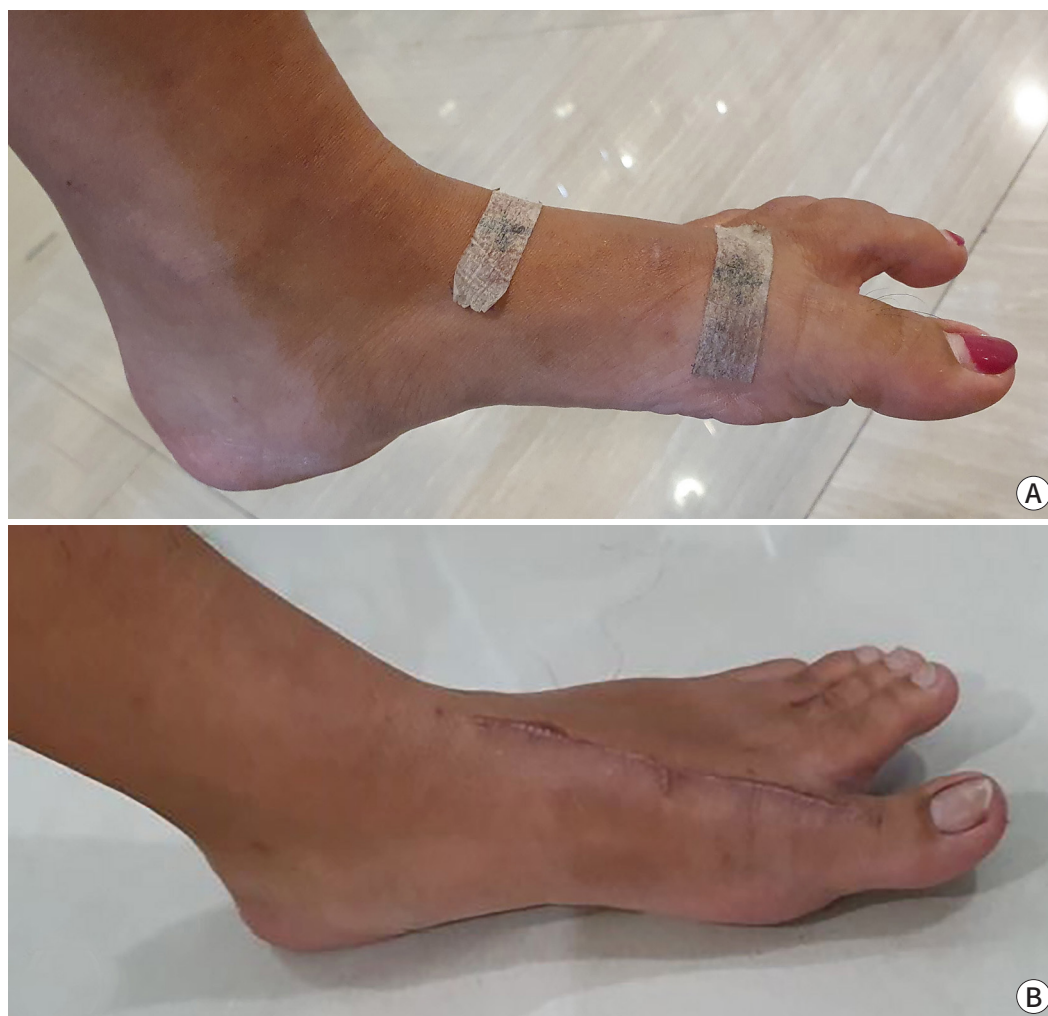

**Fig. 4.** Intraoperative findings. (A, B) The semitendinosus tendon graft was sutured to the proximal and distal extensor hallucis longus (EHL) stumps using the Pulvertaft and Kessler technique. (C) The sutured tendon was pulled to assess tendon tension and extension of the big toe. (D) EHL vitality and function were tested using a nerve stimulation machine and showed extension of the great toe.

### 3. Postoperative care

One week after surgery, the patient visited the surgical outpatient clinic for a wound assessment. Upon physical examination, her left great toe demonstrated ongoing weakness in active extension, prompting a recommendation for electrical muscle stimulation. The short leg splint was kept in place for six weeks post-surgery, after which it was substituted with a boot walker for an additional six weeks. By the second week after surgery, her left great toe showed slight improvement, with an extension of approximately 10°. The patient was then guided in passive dorsiflexion of the big toe. Four weeks post-surgery, there was a noticeable improvement in the left great toe, although some weakness remained. Active exercises for the great toe were introduced six weeks post-surgery, and the patient was given the go-ahead to participate in cycling. Additionally, transcutaneous electrical nerve stimulation was added to the program to address superficial nerve irritation on the dorsolateral aspect of the foot.

At an 8-week follow-up (Fig. 5), scores on the American Orthopaedic Foot and Ankle Society (AOFAS) hallux MTP scale ranged from 59 to 85. The Foot and Ankle Ability Measure activities of daily living subscale score varied between 43% and 85%, while the sport subscale score ranged from 25% to 79%. The Foot and Ankle Disability Index activities subscale score fluctuated between 56% and 86%, with the sport subscale score ranging from 31% to 81%. By the 10-week follow-up, improvements in pain and power were observed, and the patient was prepared to intermittently remove the boot walker. By the 12-week follow-up, the patient was given permission to completely discontinue the use of the boot walker. She exhibited near-normal active extension of the great toe without any pain. Further details of the postoperative rehabilitation protocol can be found in Table 1.



**Fig. 5.** An 8-week postoperative follow-up. (A) The left hallux position before surgery. (B) The hallux extension strength was nearly normal.

## Discussion

A cohort study revealed an estimated 2% incidence of EHL rupture in the general population [5]. In this presented case, the injury was consistent with a zone 3 injury based on the Al-Qattan study (Table 2) [6]. Various methods exist for treating EHL ruptures, including primary suturing or reconstruction surgery with a tendon graft if primary suturing is not feasible [3]. Chronic EHL tendon ruptures ( $\geq 6$  weeks) are commonly treated with reconstructive surgery involving a tendon graft or tendon transfer, as primary suturing can be challenging due to high tension, contracture, or degeneration of the ruptured tendon [7]. The etiology of EHL rupture is often associated with trauma, such as sharp objects falling onto the dorsum of the foot (e.g., a piece of glass, knife, mirror, or metal object) [1].

Commonly, autologous tendon grafts such as the semitendinosus, gracilis, plantaris, peroneus tertius, extensor digitorum longus, and extensor digitorum brevis are considered potential options for EHL repair [3,7]. The extensor digitorum longus and extensor digitorum brevis are typically used for shorter grafts, while the plantaris and peroneus tertius grafts are favored

**Table 1.** The 12-week rehabilitation protocol following extensor hallucis longus tendon reconstruction

Week	Program	Hallux range of motion (ROM) / Weight bearing (WB)
1	Wound healing and electrical muscle stimulation (EMS)	No ROM and no WB; a posterior splint was worn
2	Wound healing and EMS	No ROM and no WB; a posterior splint was worn
3–4	Passive at-home stretching of the hallux: 3 times daily, 10 minutes, with EMS.	No active ROM and partial WB; a posterior splint was worn
5–6	Passive at-home stretching of the hallux with increased power: 3 times daily, 10 minutes, with EMS.	No active ROM and partial WB; a posterior splint was worn
6	Active stretching of the hallux: 3 times daily, 10 minutes, with EMS. Static cycling: 3 times weekly, 15 minutes.	Start active ROM, remove the posterior splint, and start full WB on the boot walker everyday
8	Static cycling: 3 times weekly, 30 minutes. Gait cycle and toe crunch exercises were performed to improve stiffness and walking.	More active ROM, full WB on the boot walker for outdoor activity
10	Static cycling: 3 times weekly, 30 minutes. Gait cycle and toe crunch exercises were performed to improve stiffness and walking. Lower extremities strengthening routine.	Allow more active ROM, full WB on the boot walker at work
12	Static cycling: 4 times weekly, 30 minutes. Gait cycle and toe crunch exercises were performed to improve stiffness and walking. Lower extremities strengthening routine.	Remove boot walker and start full WB with comfortable shoes

**Table 2.** Anatomical zones of extensor hallucis longus (EHL) tendon laceration

Zone	Anatomical description
1	At EHL insertion on the distal phalanx
2	Between zones 1 and 3
3	Over metatarsophalangeal joint
4	At dorsal of foot between zones 3 and 5
5	Under the extensor retinaculum
6	Proximal to the extensor retinaculum

Data from Al-Qattan [6].

for longer grafts due to their sufficient length. However, these tend to have smaller diameters compared to the EHL tendon. The semitendinosus tendon, in contrast, offers both adequate length and a diameter similar to the EHL tendon, making it relatively easy to harvest. Moreover, it has shown superior regenerative results compared to the other options [3].

There is scarce information in the literature regarding the outcome of EHL reconstruction. Tuncer et al. reported a case study involving iatrogenic synovectomy of the EHL during ankle arthroscopy using radiofrequency thermal ablation. The study demonstrated that chronic EHL tendon rupture treated with autograft semitendinosus resulted in a positive outcome 12 weeks after tendon reconstruction, with the patient remaining symptom-free for a year [8]. Park et al. documented the case of a 15-year-old boy with chronic EHL rupture following a taekwondo match, who underwent tendon reconstruction with autograft semitendinosus. The study concluded that the semitendinosus tendon could serve as a potential graft material when primary suturing is challenging to perform [3]. Lohrer and Nauck reported various surgical

techniques for EHL tendon rupture involving tendon reconstruction or primary repair, aiming to minimize the need for skin incisions in sensitive areas. An autograft of the semitendinosus tendon appeared to yield better outcomes than a gracilis tendon autograft, tenodesis to a nearby tendon, or primary repair [9].

Bronner et al. published a report about mobilization protocols for EHL laceration rehabilitation. Regrettably, the report did not provide specific guidelines concerning the timing, duration, frequency, and intensity of hallux mobilization therapy. The general consensus for EHL rehabilitation recommends a three-week period of immobilization, followed by passive mobilization and resistance training for active mobilization [10]. Delaying active mobilization until 5 or 6 weeks postoperative or until the patient feels comfortable during passive mobilization is recommended as a way to reduce the risk of re-rupture [11]. The prolonged use of braces is also recommended to decrease the risk of re-rupture. The braces used for immobilization in cases of EHL rupture are those that limit ankle motion while keeping the foot in a natural or dorsiflexed position, thereby reducing the risk of excessive tension, strain, and friction on the tendon [12].

In instances where primary suturing is challenging due to a neglected case of EHL tendon rupture, the use of an autograft of the semitendinosus tendon has demonstrated favorable results. We selected the semitendinosus tendon for grafting because of its resemblance to the EHL tendon and its superior regenerative capabilities. A 12-week postoperative rehabilitation program is crucial to aid the healing process and guarantee satisfactory tendon mobility. This timeframe was considered adequate for patient recovery before discharge from our clinic.

---

## Acknowledgements

Not applicable.

### Conflict of Interest

No potential conflict of interest relevant to this article was reported.

### ORCID iD

Astuti Pitarini: <https://orcid.org/0000-0002-8176-6934>

Mitchel: <https://orcid.org/0009-0001-3904-0232>

Karina Sylvana Gani: <https://orcid.org/0000-0001-7306-9752>

Ratna Moniqa: <https://orcid.org/0009-0006-9738-7863>

Erica Kholinne: <https://orcid.org/0000-0002-4326-8205>

### Author Contribution

Conceptualization: Mitchel

Formal Analysis: Pitarini A

Investigation: Mitchel, Gani KS

Methodology: Moniqa R, Kholinne E

Project Administration: Moniqa R

Writing – Original Draft: Pitarini A, Mitchel, Gani KS

Writing – Review & Editing: Pitarini A, Mitchel, Gani KS, Moniqa R, Kholinne E

### Ethics Approval and Consent to Participate

Informed consent for publication of the images was obtained from the patient.

---

## References

1. Wong JC, Daniel JN, Raikin SM. Repair of acute extensor hallucis longus tendon injuries: a retrospective review. *Foot Ankle Spec* 2014;7(1):45–51.
2. Kim WJ, Jung KJ, Ahn H, Yeo ED, Lee HS, Won SH, et al. Reconstruction of a neglected, extensor hallucis longus tendon rupture using interposed scar tissue: a case report and literature review. *Int J Environ Res Public Health* 2021;18(22):12157.
3. Park HG, Lee BK, Sim JA. Autogenous graft repair using semitendinous tendon for a chronic multifocal rupture of the extensor

- hallucis longus tendon: a case report. *Foot Ankle Int* 2003;24(6):506-508.
4. Ferretti A, Conteduca F, Morelli F, Masi V. Regeneration of the semitendinosus tendon after its use in anterior cruciate ligament reconstruction: a histologic study of three cases. *Am J Sports Med* 2002;30(2):204-207.
  5. Chun DI, Lee JH, Cho J. Rupture of the extensor hallucis longus muscle secondary to repetitive overuse in a taekwondo athlete: a case report. *J Am Podiatr Med Assoc* 2017;107(5):446-449.
  6. Al-Qattan MM. Surgical treatment and results in 17 cases of open lacerations of the extensor hallucis longus tendon. *J Plast Reconstr Aesthet Surg* 2007;60(4):360-367.
  7. Kurashige T. Chronic extensor hallucis longus tendon rupture treated with double-bundle autograft of extensor hallucis capsularis: a case report. *SAGE Open Med Case Rep* 2019;7:2050313X19841962.
  8. Tuncer S, Aksu N, Isiklar U. Delayed rupture of the extensor hallucis longus and extensor digitorum communis tendons after breaching the anterior capsule with a radiofrequency probe during ankle arthroscopy: a case report. *J Foot Ankle Surg* 2010; 49(5):490.E1-490.E3.
  9. Lohrer H, Nauck T. Subcutaneous extensor hallucis longus tendon rupture: case report and literature review. *Foot Ankle Int* 2012;33(10):905-911.
  10. Bronner S, Ojofeitimi S, Rose D. Repair and rehabilitation of extensor hallucis longus and brevis tendon lacerations in a professional dancer. *J Orthop Sports Phys Ther* 2008;38(6):362-370.
  11. Joseph RM, Barhorst J. Surgical reconstruction and mobilization therapy for a retracted extensor hallucis longus laceration and tendon defect repaired by split extensor hallucis longus tendon lengthening and dermal scaffold augmentation. *J Foot Ankle Surg* 2012;51(4):509-516.
  12. Refshaug KM, Taylor JL, McCloskey DI, Gianoutsos M, Mathews P, Fitzpatrick RC. Movement detection at the human big toe. *J Physiol* 1998;513(Pt 1):307-314.