

Application of Ziehl Neelsen Staining Method for Taenia spp. Eggs Differentiation

by Machrumnizar Machrumnizar

Submission date: 11-Apr-2023 08:19AM (UTC+0700)

Submission ID: 2061064553

File name: elsen_Staining_Method_for_Taenia_spp._Eggs_Differentiation-1.pdf (291.88K)

Word count: 3203

Character count: 17111



Tehran University of Medical
Sciences Publication
<http://tums.ac.ir>

Iran J Parasitol

Open access Journal at
<http://ijpa.tums.ac.ir>



Iranian Society of Parasitology
<http://isp.tums.ac.ir>

Original Article

Application of Ziehl Neelsen Staining Method for *Taenia* spp. Eggs Differentiation

Machrumnizar Machrumnizar¹, Arleen Devita², Yuliana Yuliana¹, *Suriyani Tan¹

1. Department of Parasitology, Faculty of Medicine, Trisakti University, Jakarta, Indonesia
2. Department of Microbiology, Faculty of Medicine, Trisakti University, Jakarta, Indonesia

Received 24 Feb 2022
Accepted 11 Apr 2022

Keywords:

Eggs;
Kato-Katz;
Taenia saginata;
Taenia solium;
Ziehl Neelsen

*Correspondence

Email:
suriyani@trisakti.ac.id

Abstract

Background: Three of *Taenia* species, named *Taenia saginata*, *T. solium* and *T. asiatica* can be found in Indonesia, but only *T. solium* can lead to neurocysticercosis. The morphology of those 3 *Taenia* spp. egg is indistinguishable by standard parasitology procedure. We aimed to use Ziehl Neelsen staining for differentiation of eggs of *T. saginata* and *T. solium*.

Methods: As many as 40 containers of stool samples from the positive helminthiasis patients in Jakarta, Indonesia were collected during the year 2018. From each container, 10 slides prepared for staining with Kato-Katz technique as the preliminary examination. From those stool samples with positive taeniasis, we then once again made 10 slides/container for Ziehl Neelsen staining.

Results: The first 400 slides stained with Kato-Katz technique as preliminary test were all positive for *Taenia* spp. The second 400 slides, we got 244 slides that gave good results as we could distinguished between the eggs of *T. saginata* and *T. solium*, meanwhile the remainder 156 slides gave unconfirmed results. From those 244 slides, 154 slides showed *T. saginata* eggs with magenta colored and 90 slides showed *T. solium* eggs with blue/purple colored. The eggs of *T. solium* slightly smaller if compared to *Taenia saginata* and had round shape, meanwhile *T. saginata* eggs were oval in shape.

Conclusion: Ziehl Neelsen staining method can be used as an alternative parasitological method to differentiate the eggs of *T. saginata* and *T. solium*.



332

Copyright © 2022 Machrumnizar et al. Published by Tehran University of Medical Sciences.

This work is licensed under a Creative Commons Attribution-NonCommercial 4.0 International license (<https://creativecommons.org/licenses/by-nc/4.0/>). Non-commercial uses of the work are permitted, provided the original work is properly cited

Available at: <http://ijpa.tums.ac.ir>

Introduction

Taeniasis is the intestinal infection of humans caused by adult stages of *Taenia solium*, *T. saginata*, and *T. asiatica*. These parasites have a worldwide distribution, and the highest burden dwells in low income and lower-middle income countries, including countries in South East Asia (1-3). This zoonotic disease has been known from 1855 since some experiments done in prisoners (4).

Humans are the only definitive host for these three species, so they can turn into their mature adult stage in humans (5). Infection happens involving poor handling of meat (beef or pork), undercooked meat eating habit, or poor hygiene sanitation (6). Larval stage of these parasites is called cysticercosis that refers to the tissue infection of the intermediate host, cattle for *T. saginata* and swine for *T. solium* and *T. asiatica* (7,8). Taeniasis is relatively harmless because the adult worm stage of this cestode infects the human small intestine and causes specific symptoms, such as abdominal pain and nausea and can be treated with praziquantel (9,10). On the other hand, when human become the accidental host for *T. solium* where eggs of this species are accidentally ingested by human through contaminated soil, and the parasite could not develop into mature stage and remain in larval form (11). The larval form of *T. solium* has the ability to infect the human brain by causing neurocysticercosis, the leading cause of acquired epilepsy worldwide (12).

Human cysticercosis is endemic in most developing countries and frequently attacks the human central nervous system (CNS), causing a variety of neurological symptoms called neurocysticercosis (NCC) (13). It is reported that more than 50 million people worldwide infected with larva of *T. solium* and developed NCC, with 0.1 percent of mortality (14). It is difficult to differentiate species *T. solium* and *T. saginata* by simple parasitology examination of stool samples, such as Kato-Katz

technique since the eggs morphology are very similar and undistinguishable (15). The right identification is very important because the consequences of infection in humans by these two parasites are very different. The precise diagnosis and prompt treatment of NCC is complex (16). Therefore, an adequate early detection and treatment of taeniasis is essential for the prevention of cysticercosis infection. Furthermore, it is urgently needed reliable epidemiological information for the use in effective control of taeniasis or cysticercosis, including appropriate tools for parasite identification (17).

Currently, the two human *Taenia* spp. can be identified based on uterine branches number in intact gravid proglottids, and the presence or absence of hooks in the tapeworms scolex. Obtaining gravid proglottids or scolex that are still solid and intact after treatment is often difficult because most gravid proglottids are damaged or only immature proglottids are present in the stool (18). Currently, Kato-Katz technique serve as standard parasitological procedure is not reliable as this technique cannot differentiate the eggs of *T. solium* and *T. saginata*. Molecular technique have been used to differentiate between *T. solium* and *T. saginata*, but this techniques is time and money consuming, yet not comfortable to be used as routine diagnostic procedure. Ziehl Neelsen staining is routinely used as bacteriological staining method used to identify acid-fast organisms, including *Mycobacteria*, but can be used as staining method in differentiating *T. solium* and *T. saginata*, yet this method is not popular as Kato-Katz technique and has been neglected for a long time (19).

Therefore, we aimed to differentiate *T. solium* and *T. saginata* based on egg morphology using Ziehl Neelsen staining and its comparison to Kato-Katz method.

Methods

Stool Samples Preparations

Forty containers of stool from confirmed helminthiasis patients were obtained from Parasitology Laboratory of the National Central Hospital in Jakarta. Stool samples were then preserved in a 5% formalin-PBS solution and transported directly to Parasitology Laboratory in Trisakti University and kept in 4 °C until further usage. From 40 containers of stool, we made 10 slides for each containers for confirmation of taenia eggs existence. All positive taeniasis stool samples that had been confirmed by Kato-Katz technique were separated. Those positive stool samples were then once again being made into 10 slides per container and stained with Ziehl Neelsen.

Kato-Katz Technique

One gram of stool from each containers was taken and being admitted to the mesh to remove particles. The sieved samples were then transferred to the hole of the Kato-Katz template and the slide glass was put under each of the template. The templates were then removed and the samples covered with the cellophane tape, which has been soaked in Kato-Katz solution. Slides were examined under the microscope with the magnification of objective 10x and 40x (3, 20).

Ziehl Neelsen Staining

Stool samples was smeared in slide glass, air dried, and fixed. Samples were stained with 3% carbol fuchsin for 15 minutes, heated for 5 minutes and then cooled in room temperature. Samples were then washed with tap water, decolorized with 70% Ethanol 1% HCl and once again washed with tap water. Slides then contrasted with 3% methylene blue dye for 5 minutes, washed with tap water and left to dry in room temperature (21).

Ethical considerations

15

This study has been reviewed and approved by the Ethics committee in Medical Faculty of Trisakti University, Jakarta, Indonesia (07/KER-FK11/2017).

Results

Identification of *Taenia* spp. by parasitological examination using the Kato-Katz

The Kato-Katz Technique was examined twice by two different researchers to reduce the subjectivity factor. All those 400 slides were positive with the soil transmitted helminths and *Taenia* spp. eggs. The eggs of *Taenia* spp. stained with Kato-Katz method appear to be round-oval with a size of about 35 µ, brownish yellow color, and the visible contents are hexacanth embryo covered with two layers of walls with a structure resembling a cart-wheel (Fig. 1).

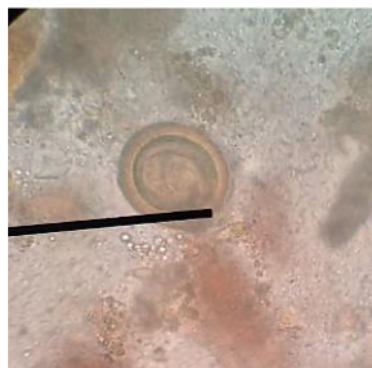


Fig. 1: *Taenia* spp. eggs in the Kato-Katz method (Original)

The examination results of this study found several worm eggs from Nematode and Cestode class that often infect humans. The intestinal nematode class eggs, which is a Soil-Transmitted Helminths, were frequently found and the largest number of species was *Trichuris trichiura*. Table 1 displayed the helminth species that identified in the stool samples.

Table 1: Frequency of *Taenia* spp. using Kato-Katz Method

Species	Quantity (n)	Percentage (%)
<i>Trichuris trichiura</i>	286	28.6
<i>Ascaris lumbricoides</i>	258	25.8
Hookworm	104	10.4
<i>Taenia</i> spp	244	24.4
<i>Hymenolepis nana</i>	62	6.2
<i>Hymenolepis diminuta</i>	46	4.6

Identification of *Taenia* spp. using Ziehl Neelsen staining

After Ziehl Neelsen staining of 400 slides, 244 positive slides were positive for *Taenia* spp.

eggs, as 63% of the slides were positive for *T. saginata*, meanwhile the rest of the slides (37%) were positive for *T. solium* (Table 2).

Table 2: Frequency of *Taenia* spp. using Ziehl Neelsen staining

Species	Quantity (N)	Percentage (%)
<i>Taenia solium</i>	154	63
<i>Taenia saginata</i>	90	37
Total	244	100

T. saginata eggs stained with Ziehl Neelsen method appear completely with magenta red color and oval in shape, as *T. solium* eggs appear purplish blue in color and rounder in

shape. The eggs size and shape of *T. saginata* were slightly larger and always round-oval, whereas *T. solium* eggs were smaller and mostly spherical in shape (Fig. 2).

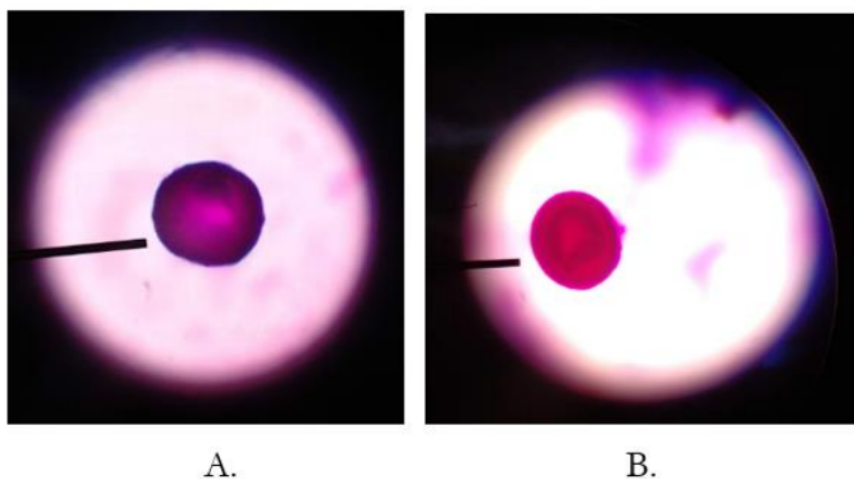


Fig. 2: Eggs of *Taenia* spp. in the Ziehl Neelsen method. (A) *Taenia solium*; (B) *Taenia saginata* (Original)

Discussion

Indonesia and most countries in Southeast Asia are endemic areas for the *Taenia* tapeworm that infects humans, therefore an accurate and important diagnostic tool is needed for the identification of taeniasis to the species level (6). The most common diagnostic approach for helminth infection in epidemiological studies is the copro-microscopic detection of worm eggs using the Kato-Katz technique. This method is recommended by the WHO due to its simplicity and relatively low cost, since most of the equipment is reusable (22). However, this technique has limitations in terms of sensitivity and nonspecific in identifying *Taenia* spp. eggs (23, 24). Multiple Kato-Katz examinations are usually performed to improve diagnostics (25).

Several stool samples showed mixed infection of nematode and cestode, and these results also a confirmation that parasite infections remains as never ending public health problems until nowadays (26). Our study results also in line with Dunn et al. that stated most prevalent soil-transmitted helminth was *T. trichiura* (22.84%), followed by *Necator americanus* (22.69%) and *A. lumbricoides* (8.80%) (13). However, in contrast to Oishi et al. (23), *A. lumbricoides* (2.4%, 13/549) was the most prevalent soil-transmitted helminth detected (28).

In this study, we were confirmed that Ziehl Neelsen staining could be used to differentiate *T. saginata* from *T. solium* eggs without doubt. These results were in line with the study of Amer et al., who used Ziehl Neelsen's stain for the first time to differentiate the egg morphology of *T. saginata* and *T. solium* (29). Jimenez et al. also showed the same results even though this study claimed that the distinction was not sensitive enough (30). Results from this study also showed that not all *Taenia* eggs found by the Ziehl Neelsen technique showed any hooks, this is probably due to the heating of Carbol-fuchsin and the length of time it had been stained so that it affected dye absorption.

From those 400 slides, more than half of the slides were eggs of *T. saginata*. The epidemiology of taeniasis in Indonesia are influenced by the culinary pattern and religious practices, as most of Indonesian eat beef compared to pork (31). *Taenia solium* only can be found in the several places in Indonesia, such as Bali Island, Papua Island, and north part of Sumatera Island, where most of the inhabitants include pork in their daily eating habit (32).

Conclusion

The method with Ziehl Neelsen staining can be used for the identification of *Taenia* spp. due to its simplicity and relatively inexpensive. However, in-depth studies are needed to determine the sensitivity and specificity of Ziehl Neelsen staining compared to other techniques so that a definite diagnosis of taeniasis can be established.

Acknowledgements

We would like to express our gratitude to Nugroho Abikusno, MD, PhD for the proof reading.

This study funding was supported by a grant from Research Council, Medical Faculty of Trisakti University (No. 053/A.5/LPT/USAKTI/I/2018).

Conflict of interest

The authors declare no conflict of interest related to this study.

References

1. Sandy S, Lidwina S, Antonius S, et al. Seroepidemiology of taeniasis in the Land of Papua. KEMAS: Jurnal Kesehatan Masyarakat. 2019;15(1):22-8.
2. Symeonidou I, Arsenopoulos K, Tzilves D, Soba B, Gabriël S, Papadopoulos E. Human taeniasis/cysticercosis: a potentially emerging

- parasitic disease in Europe. *Ann Gastroenterol*. 2018;31(4):406-12.
3. Sato MO, Sato M, Yanagida T, et al. *Taenia solium*, *Taenia saginata*, *Taenia asiatica*, their hybrids and other helminthic infections occurring in a neglected tropical diseases' highly endemic area in Lao PDR. *PLoS Negl Trop Dis*. 2018;12(2):e0006260.
 4. García HH, Gonzalez AE, Evans CA, Gilman RH, Peru CWGi. *Taenia solium* cysticercosis. *The Lancet*. 2003;362(9383):547-56.
 5. Pawlowski ZS, Murrell K. Taeniasis and cysticercosis. *Foodborne Disease Handbook Second Edition, Revised and Expanded Volume 2: Viruses, Parasites, Pathogens, and HACCP*: CRC Press; 2018. p. 217-28.
 6. Ito A, Li T, Wandra T, et al. Taeniasis and cysticercosis in Asia: A review with emphasis on molecular approaches and local lifestyles. *Acta Trop*. 2019;198:105075.
 7. Lesh EJ, Brady MF. Tapeworm. *StatPearls* [Internet]: StatPearls Publishing; 2020.
 8. Song SM, Yun HS, VanBik D, et al. Ten Cases of *Taenia saginata* Infection Confirmed by Analysis of the Internal Transcribed Spacer 1 rDNA Region in the Republic of Korea. *Korean J Parasitol*. 2019;57(4):417.
 9. Okello AL, Thomas LF. Human taeniasis: current insights into prevention and management strategies in endemic countries. *Risk Manag Healthc Policy*. 2017;10:107.
 10. García HH, Gonzalez AE, Gilman RH. *Taenia solium* cysticercosis and its impact in neurological disease. *Clin Microbiol Rev*. 2020;33(3):e00085-19.
 11. Samorek-Pieróg M, Karamon J, Cencek T. Identification and control of sources of *Taenia solium* infection—the attempts to eradicate the parasite. *J Vet Res*. 2018;62(1):27.
 12. Reddy DS, Volkmer II R. Neurocysticercosis as an infectious acquired epilepsy worldwide. *Seizure*. 2017;52:176-81.
 13. El-Kady AM, Allemalem KS, Almatroudi A, Abler B, Elsayed M. Psychiatric Disorders of Neurocysticercosis: Narrative Review. *Neuropsychiatr Dis Treat*. 2021;17:1599-1610.
 14. Wu H-W, Ito A, Ai L, Zhou X-N, Acosta LP, Lee Willingham Iii A. Cysticercosis/taeniasis endemicity in Southeast Asia: Current status and control measures. *Acta Trop*. 2017;165:121-32.
 15. Palma S, Chile N, Carmen-Orozco RP, et al. In vitro model of postoncosphere development, and in vivo infection abilities of *Taenia solium* and *Taenia saginata*. *PLoS Negl Trop Dis*. 2019;13(3):e0007261.
 16. Garcia HH, O'Neal SE, Noh J, Handali S, Kraft CS. Laboratory Diagnosis of Neurocysticercosis (*Taenia solium*). *J Clin Microbiol*. 2018;56(9):e00424-18.
 17. Mwape KE, Gabriël S. The parasitological, immunological, and molecular diagnosis of human taeniasis with special emphasis on *Taenia solium* taeniasis. *Curr Trop Med Rep*. 2014;1(4):173-80.
 18. Organization WH. *Taenia solium* taeniasis/cysticercosis diagnostic tools: report of a stakeholder meeting, Geneva, 17-18 December 2015. 2016.
 19. Capron A, Rose F. [On the composition of helminth eggs. II. Alcohol-acid-resistance in cestodes. Difference of Ziehl stainability of embryophores of *Taenia saginata* and *Taenia solium*]. *Bull Soc Pathol Exot Filiales*. 1962;55:765-7.
 20. Charoensuk L, Subrungruang I, Mungthin M, Pinlaor S, Suwannahitatorn P. Comparison of stool examination techniques to detect *Opisthorchis viverrini* in low intensity infection. *Acta Trop*. 2019;191:13-6.
 21. Atlas R, Snyder J. Reagents, stains, and media: bacteriology. *Manual of Clinical Microbiology*, Eleventh Edition: American Society of Microbiology; 2015. p. 316-49.
 22. Turner HC, Bettis AA, Dunn JC, et al. Economic Considerations for Moving beyond the Kato-Katz Technique for Diagnosing Intestinal Parasites As We Move Towards Elimination. *Trends Parasitol*. 2017;33(6):435-43.
 23. Ngwese MM, Manouana GP, Moure PAN, Ramharter M, Esen M, Adégnika AA. Diagnostic techniques of soil-transmitted helminths: Impact on control measures. *Trop Med Infect Dis*. 2020;5(2).
 24. Bosch F, Palmeirim MS, Ali SM, Ame SM, Hattendorf J, Keiser J. Diagnosis of soil-transmitted helminths using the Kato-Katz technique: What is the influence of stirring, storage time and storage temperature on stool sample egg counts? *PLoS Negl Trop Dis*. 2021;15(1):e0009032.

25. Gómez-Morales MÁ, Pezzotti P, Ludovisi A, et al. Collaborative Studies for the Detection of *Taenia* spp. Infections in Humans within CYSTINET, the European Network on Taeniosis/Cysticercosis. *Microorganisms*. 2021;9(6):1173.
26. Lee J, Ryu J-S. Current Status of Parasite Infections in Indonesia: A Literature Review. *Korean J Parasitol*. 2019;57(4):329-39.
27. Dunn JC, Papiakovou M, Han KT, et al. The increased sensitivity of qPCR in comparison to Kato-Katz is required for the accurate assessment of the prevalence of soil-transmitted helminth infection in settings that have received multiple rounds of mass drug administration. *Parasites & Vectors*. 2020;13(1):1-11.
28. Oishi CY, do Rocio Klisiowicz D, Seguí R, et al. Reduced prevalence of soil-transmitted helminths and high frequency of protozoan infections in the surrounding urban area of Curitiba, Paraná, Brazil. *Parasite Epidemiol Control*. 2019;7:e00115.
29. Amer O, Alanazi WS, Alshammari HS, Alghaithi AM, Alenezi AM. Human taeniosis among housemaids in Hail, Saudi Arabia. *IJMDC*. 2019; 3(6): 549-552.
30. Jimenez JA, Rodriguez S, Moyano LM, Castillo Y, García HH. Differentiating *Taenia* eggs found in human stools: does Ziehl-Neelsen staining help? *Trop Med Int Health*. 2010;15(9):1077-81.
31. Eichenberger RM, Thomas LF, Gabriél S, et al. Epidemiology of *Taenia saginata* taeniosis/cysticercosis: a systematic review of the distribution in East, Southeast and South Asia. *Parasites & Vectors*. 2020;13:1-11.
32. Yanagida T, Swastika K, Dharmawan NS, et al. Origin of the pork tapeworm *Taenia solium* in Bali and Papua, Indonesia. *Parasitol Int*. 2021;83:102285.

Application of Ziehl Neelsen Staining Method for Taenia spp. Eggs Differentiation

ORIGINALITY REPORT

15%

SIMILARITY INDEX

9%

INTERNET SOURCES

13%

PUBLICATIONS

1%

STUDENT PAPERS

PRIMARY SOURCES

- 1** journals.plos.org Internet Source 2%
- 2** Laranjo González, Minerva, Universitat Autònoma de Barcelona. Departament de Sanitat i d'Anatomia Animals. "Epidemiology of taeniosis and cysticercosis in Europe /", 2018 Internet Source 2%
- 3** Allan, JC, Craig, PS, Dongchuan, Q, Ito, Akira, Mamuti, W, Nakao, M, Nakaya, K, Sako, Y, Sato, MO, Yamasaki, H, イトウ, アキラ and 伊藤, 亮. "DNA differential diagnosis of taeniasis and cysticercosis by multiplex PCR", amcor, 2012. Publication 2%
- 4** jcm.asm.org Internet Source 1%
- 5** Benjamin Speich, Said M Ali, Shaali M Ame, Marco Albonico, Jürg Utzinger, Jennifer Keiser. "Quality control in the diagnosis of Trichuris 1%

trichiura and Ascaris lumbricoides using the Kato-Katz technique: experience from three randomised controlled trials", Parasites & Vectors, 2015

Publication

6

Submitted to Our Lady of Fatima University

Student Paper

1 %

7

Jeri, C.. "Species identification after treatment for human taeniasis", The Lancet, 20040320

Publication

1 %

8

"Helminth Infections and their Impact on Global Public Health", Springer Science and Business Media LLC, 2022

Publication

1 %

9

Juan A. Jimenez. "Differentiating Taenia eggs found in human stools: does Ziehl-Neelsen staining help? : Differentiating Taenia eggs found in human stools", Tropical Medicine & International Health, 06/23/2010

Publication

1 %

10

pubmed.ncbi.nlm.nih.gov

Internet Source

1 %

11

www.ncbi.nlm.nih.gov

Internet Source

1 %

12

M. S Kramer. "The double jeopardy of clustered measurement and cluster randomisation", BMJ, 08/21/2009

1 %

13

Camila Yumi Oishi, Débora do Rocio Klisiowicz, Raimundo Seguí, Pamela C. Köster et al.

"Reduced prevalence of soil-transmitted helminths and high frequency of protozoan infections in the surrounding urban area of Curitiba, Paraná, Brazil", *Parasite Epidemiology and Control*, 2019

Publication

<1 %

14

Raf Somers, Pierre Dorny, Dirk Geysen, Lan Anh Nguyen, Dang Cam Thach, Jozef Vercruysse, Viet Khong Nguyen. "Human tapeworms in north Vietnam", *Transactions of the Royal Society of Tropical Medicine and Hygiene*, 2007

Publication

<1 %

15

Yiyi Wang, Hongzhi Guan, Yuan Liu, Liandi Lu, Qian Li, Yu-Zhao, Xiaohan Zhen. "A Patient of Neurocysticercosis Misdiagnosed as Tuberculous Meningitis for 26 Years: a Case Report", *Research Square*, 2021

Publication

<1 %

16

pneumonia.biomedcentral.com

Internet Source

<1 %

17

www.ejmanager.com

Internet Source

<1 %

18

H. Mayta, A. Talley, R. H. Gilman, J. Jimenez, M. Verastegui, M. Ruiz, H. H. Garcia, A. E. Gonzalez. " Differentiating and Infections by Simple Hematoxylin-Eosin Staining and PCR-Restriction Enzyme Analysis ", Journal of Clinical Microbiology, 2000

Publication

<1 %

Exclude quotes Off

Exclude matches Off

Exclude bibliography On

Application of Ziehl Neelsen Staining Method for Taenia spp. Eggs Differentiation

GRADEMARK REPORT

FINAL GRADE

/0

GENERAL COMMENTS

Instructor

PAGE 1

PAGE 2

PAGE 3

PAGE 4

PAGE 5

PAGE 6

PAGE 7
