

Effectiveness of the Multilayered Caries Model and Visuo-Tactile Virtual Reality Simulator for Minimally Invasive Caries Removal: A Randomized Controlled Trial

by Ade Prijanti

Submission date: 11-Apr-2023 09:30AM (UTC+0700)

Submission ID: 2061133557

File name: JOP.pdf (754.69K)

Word count: 5787

Character count: 32785

Effectiveness of the Multilayered Caries Model and Visuo-Tactile Virtual Reality Simulator for Minimally Invasive Caries Removal: A Randomized Controlled Trial



AP Dwisaptarini • S Suebnukarn • P Rhienmora • P Haddawy • S Koontongkaew

Clinical Relevance

Differentiation and selective removal of carious dentin are important in minimally invasive caries treatment. The virtual reality simulator and multilayered model of a carious tooth reconstructed from micro-CT images representing the infected and affected carious layer with different colors and hardnesses provide visuo-tactile sensation for training in minimally invasive caries removal.



Ade Prijanti Dwisaptarini, DDS, MSc, Faculty of Dentistry, Trisakti University, West Jakarta, Jakarta, 11440 Indonesia

*Siriwan Suebnukarn, DDS, PhD, Faculty of Dentistry, Thammasat University, Klongluang Pathumthani, 12121 Thailand

Phattanapon Rhienmora, PhD, School of Information Technology and Innovation, Bangkok University, Klongluang Pathumthani, 12120 Thailand

Peter Haddawy, PhD, School of Information and Communication Technology, Mahidol University, Salaya, Nakhonpathom, 73170 Thailand

Sittichai Koontongkaew, DDS, PhD, Faculty of Dentistry, Thammasat University, Klongluang Pathumthani, 12121 Thailand

*Corresponding author: Thammasat University, Klongluang, Pathumthani, 12121 Thailand; e-mail: siriwan.suebnukarn@gmail.com

DOI: 10.2341/17-083-C

ABSTRACT

This work presents the multilayered caries model with a visuo-tactile virtual reality simulator and a randomized controlled trial protocol to determine the effectiveness of the simulator in training for minimally invasive caries removal. A three-dimensional, multilayered caries model was reconstructed from 10 micro-computed tomography (CT) images of deeply carious extracted human teeth before and after caries removal. The full grey scale 0-255 yielded a median grey scale value of 0-9, 10-18, 19-25, 26-52, and 53-80 regarding dental pulp, infected carious dentin, affected carious dentin, normal dentin, and normal enamel, respectively. The simulator was connected to two haptic devices for a handpiece and mouth mirror. The visuo-tactile feedback during the operation varied depending on the grey scale. Sixth-year dental students underwent a pre-training assessment of caries removal on ex-

tracted teeth. The students were then randomly assigned to train on either the simulator (n=16) or conventional extracted teeth (n=16) for 3 days, after which the assessment was repeated. The posttraining performance of caries removal improved compared with pretraining in both groups (Wilcoxon, $p < 0.05$). The equivalence test for proportional differences (two 1-sided t -tests) with a 0.2 margin confirmed that the participants in both groups had identical posttraining performance scores (95% CI=0.92, 1; $p=0.00$). In conclusion, training on the micro-CT multilayered caries model with the visuo-tactile virtual reality simulator and conventional extracted tooth had equivalent effects on improving performance of minimally invasive caries removal.

INTRODUCTION

Dental caries is the localized destruction of susceptible dental hard tissues by acidic by-products of bacterial fermentation of dietary carbohydrates.¹ According to GV Black in 1908,² the science of cariology and the technicalities of operative dentistry should be integrated in teaching and research of caries treatment. Dentistry in the 20th century shifted toward a minimal intervention approach, leading to changes on how and when to treat caries. The concept includes the use of all available information and techniques ranging from accurate diagnosis of caries, caries risk assessment, and prevention to technical procedures in repairing restorations.³ The disease should be treated first; the surgical approach should be undertaken only as a last resort and then with the removal of as little natural tooth structure as possible. The endpoint of caries excavation in cavity preparation is to remove infected carious dentin as selectively as possible, while preserving affected carious dentin.⁴ Avoiding over-excitation will preserve remaining tooth structure and offer longevity of restorations.⁵ Unlike management of superficial or moderate caries lesions, managing very deep lesions requires more delicate skills. Conserving tooth structure and preserving pulp vitality contribute to a longer and better prognosis by avoiding pulp exposure as well as providing optimum bonding strength for adhesive restorations. In the symptomless case of a deep carious lesion, removing all infected dentin in an area that will probably expose the pulp should be avoided. Sealing the lesion will significantly decrease the number of bacteria by removing their nutritional sources.⁶⁻⁸

Treatment of dental caries, like other disciplines of dentistry, can be associated with unwanted or unforeseen procedural errors. The first step toward increasing patient safety in dental treatment is for all clinicians to acquire knowledge and skill in the early stage of training. Current practice in caries removal starts with gaining access through the enamel to the softened, infected carious dentin. The dentinoenamel junction (DEJ) is cut further until hard—and in some dental schools—stain-free dentin is reached. The end point of caries removal close to the pulp varies according to the country, dental school, and dentist.⁹ Dental students are usually taught to assess dentin texture only by the touch of the dental probe. The dentin's darkening color, sensitivity, and wetness are useful but difficult to recognize.¹⁰ Currently, skill acquisition in caries treatment follows an apprenticeship approach, which consists of close, expert supervision in pre-clinical settings and transfer of these skills to the clinic. This method of training may subject patients to discomfort, risk of complications, and prolonged procedure times, creating a clinical governance dilemma. At the same time, there may be limited access to apprenticeship training in more complex scenarios, with corresponding difficulty in training the student in a time-effective manner.

With the significant and consistent development of medical imaging and virtual reality (VR) research, minimal intervention training in dentistry should move toward more interactive and realistic environments. Using microcomputed tomography (micro-CT) permits construction of three-dimensional (3D) images of tooth and bone structural parameters from computerized axial tomography in the order of micrometers.¹¹ VR and image-processing programs incorporate 3D images obtained from CT scanners and transform them into patient-specific anatomic models that provide human-computer interaction with the manipulation of realistic environments.¹² Tactile sensation is important in dental skill acquisition, which can be achieved by incorporating haptic devices that allow users to interact with simulated oral tissues and dental instruments designed for each specific procedure in a virtual environment.¹³ The users perform operations such as sensing, scraping, and cutting soft and hard tissues with realistic force feedback to the operator's hands. Several VR programs have been developed for dental application.¹⁴⁻¹⁷ Recently, a multilayer model that mimics real tooth structures with different hardnesses was developed in a study for caries-removal training. The study aimed at caries-removal training

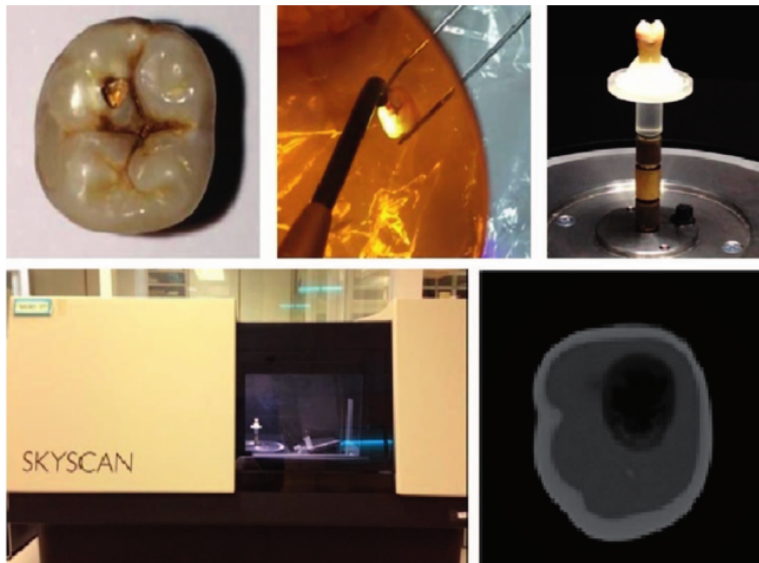


Figure 1. Acquisition of micro-CT images. (A): Extracted permanent molars with deep carious lesion. (B): Minimally invasive caries removal guided by FACE. (C, D): Micro-CT scanning. (E): DICOM file slide No. 1630 showing infected carious dentin, affected carious dentin, normal dentin, and enamel.

at repetitive training times.¹⁸ However, these studies worked on shallow carious lesions with no difference between layers. The VR simulators allow students and experts to practice dental procedures anywhere and anytime with no incremental cost. The students trained by the VR system showed performance equal to or significantly greater than those trained by conventional methods.¹⁴⁻¹⁷ Evidence as to the negative aspects of VR include initial setup costs, faculty training, and the lack of a variety of content and current educational simulation programs.¹⁹ A study comparing the effectiveness of conventional training and VR simulation in operative dentistry training indicated that VR-based skills acquisition was unsuitable as the sole method of feedback and evaluation for novice dentists.²⁰

Differentiation between infected and affected carious dentin is important in minimally invasive caries treatment. The goal is to remove infected carious dentin as selectively as possible through maximum preservation of affected carious dentin. To our knowledge, there is no VR- simulated carious tooth model that resembles a deep carious lesion likely to expose the pulp with infected and affected tissue in which caries removal needs to be done very carefully. This work presents a new, 3D, multilayered carious tooth model that reveals infected and affected carious dentin for the visuo-haptic VR simulator. Visual and haptic VR feedback, while cutting through each carious layer, varies depending

on the micro-CT density. A randomized controlled trial protocol presented in this study aims to determine the stimulation's effectiveness when used as an alternative to conventionally extracted teeth for minimally invasive caries-removal training. We tested the hypothesis that there is no difference in performance between the conventional training group and the simulation training group.

METHODS AND MATERIALS

Multilayered Caries Modeling and Visuo-Haptic Virtual Reality Simulator

3D micro-CTs (SkyScan 1172; Bruker, Brussels, Belgium) of 10 extracted permanent molars with deep carious lesions were acquired before and after minimal caries removal guided by fluorescence-aided caries excavation (FACE; Sirona, Hanau-Wolfgang, Germany) (Figure 1); the original patient could not be identified. **Micro-CT creates a 3D map of x-ray attenuation coefficient of materials within an object, corresponding to the x-ray opacity of an object.** As a result, it is likely to separate various segments of a material from each other by density thresholding. Immersion of x-rays by hard- and soft-tissue layers of a tooth such as dental pulp and enamel increases with decreasing x-ray photon energy, and that relative difference in absorption also decreases with less x-ray energy. A grey scale value that micro-CT produces is a single number that represents the brightness of the pixel. The most common pixel

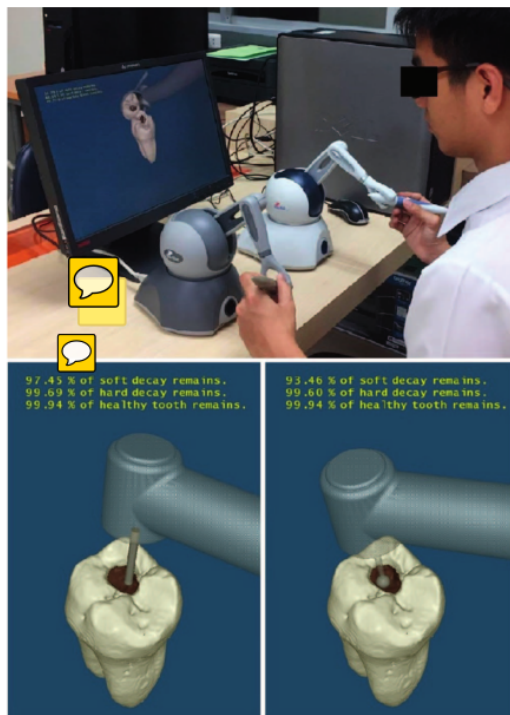


Figure 2. The simulator had a high-speed bur for cutting enamel and slow-speed bur for removing carious dentin.

format is the byte image, in which this number is stored as an 8-bit integer, giving a range of possible values from 0 to 255. Typically, zero is assumed to be black, and 255 is taken to be white.²¹

In this study, we used a semi-automated, slice-by-slice hand contouring approach, the current segmentation gold standard using 10 datasets of extracted permanent molars with deep carious lesions.²² Snake algorithms based on large image gradients were used to recognize the contours of edges of interest.²³ The full gray scale 0-255 yielded a median gray-scale value of 0-9, 10-18, 19-25, 26-52, and 53-80 regarding dental pulp, infected (soft) carious dentin, affected (hard) carious dentin, normal dentin, and enamel, respectively.

3D reconstruction of each tooth was performed using 2500 two-dimensional images processed by the volume-rendering method. Segmentation of the multilayered, carious model selectively represented enamel, infected dentin, affected dentin, healthy dentin, and dental pulp. The model was generated by

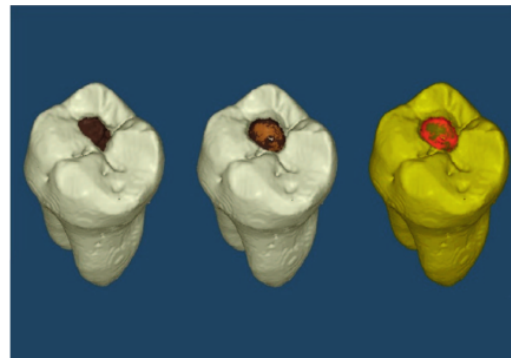


Figure 3. 3D models of extracted human teeth were reconstructed from micro-CT images. The infected carious dentin is represented as a darker, dull brown color, and the affected carious dentin is seen as a light brown color. The FACE mode that represents infected carious dentin is a red-fraction color layer.

the subtraction process of the micro-CT images before and after the removal of caries.

VR operates on a 2.8-GHz Pentium 4 PC, with 256 MB RAM and a 13-inch computer monitor connected to two haptic devices. Two Omni haptic devices (SensAble, Inc, Woburn, MA, USA) for the handpiece and mouth mirror were used, which allowed 6° of freedom for positional sensing and generated 3° of freedom for force feedback.²⁴ The force feedback, while cutting through each carious layer, varied depending on the micro-CT density value. The number of volumetric sample points of the cutting tool model immersed into tooth voxels was detected. The immersed sample points indicating the depth penetrated were removed corresponding to the shape of the bur and the amount of force applied to the tooth surface. The simulator had a high-speed bur for cutting enamel and slow-speed bur for removing carious dentin. Visual feedback consisted of tooth deformation, color, and amount of tooth removed during the operation. The percentages of each carious layer remaining while cutting were displayed in real time (Figure 2). The infected carious dentin was represented as a darker dull brown color, and the affected carious dentin was seen as a light brown color imitating a natural carious tooth (Figure 3). The simulator also had FACE mode, representing infected carious dentin as a red-fraction color layer initiated by the porphyrin produced by the bacteria when lit by the system. A brownish color is seen when affected dentin is reached, similar to the presence of sclerotic dentin produced by chronic caries. The FACE mode ensured that all infected

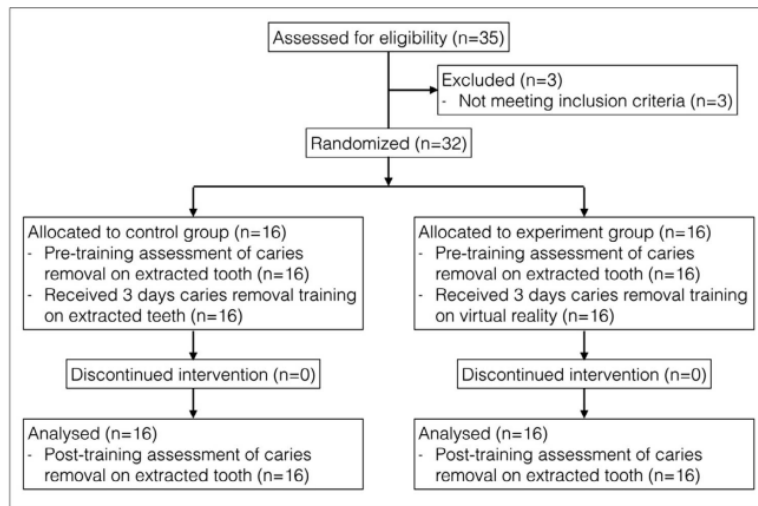


Figure 4. Flow chart of participants in the randomized controlled trial.

dentin was eliminated during the caries-removal procedure.

Randomized Controlled Trial of Efficacy for Minimally Invasive Caries-Removal Training

A prospective randomized controlled and blinded trial was conducted to test the hypothesis that training with the experimental group's multilayered caries model and visuo-tactile VR simulator will produce performance scores in caries-removal training similar to those obtained from conventional training with carious extracted teeth.

Sample Size

A continuous response variable from independent control and experimental participants with one control per experimental participant was studied. In a previous study,²⁵ the response within each participant group was normally distributed, with a standard deviation of 0.25—the true difference in the experimental and control means. As a result, 16 participants in each conventional training group and VR group were employed to reject the null hypothesis that the population means of the experimental and control groups are equal, with a probability of 0.8. The type I error probability associated with the test of this null hypothesis was 0.05. Sixth-year dental students were recruited. Exclusion criteria were as follows: 1) had experience with the simulator or 2) received a score below 70% in knowledge assessment of minimally invasive caries removal. All participants gave their written informed consent,

which was approved by the institutional ethics review board.

Study Design

Participants were randomly assigned to either the experimental group (caries-removal training with micro-CT multilayered caries model and visuo-tactile VR simulator) or the control group (conventional training with carious extracted teeth). A statistician not involved with the study undertook the randomization using sealed opaque envelopes (Figure 4). The study had a pretraining/posttraining control group design. On pretraining day (day 1), each participant was asked to perform minimally invasive caries removal on one extracted tooth. On training days (days 2, 3, and 4), 16 participants in the control group practiced caries removal on two extracted teeth, and 16 participants in the experimental group practiced caries removal on 2 micro-CT multilayered carious teeth using the visuo-tactile VR simulator. In the control group, the carious and undermined enamel was prepared with a cylindrical bur (Meisinger, Neuss, Germany) using a high-speed handpiece with water coolant until direct vision into the entire cavity was achieved. Caries removal on the peripheral walls and pulpal floor was performed using a tungsten carbide round bur with a low-speed handpiece. The goal was to eliminate the infected dentin and preserve the affected dentin, as confirmed by the FACE system. The training process was similar in the experimental group, in which caries removal was carried out in the simulator. On

Table 1. Pretraining and Posttraining Performance Scores Between Caries Removal Training With Micro-CT Multilayered Caries Model and Visuo-Tactile VR Simulator (Experimental Group) and Training With Extracted Carious Teeth (Control Group) (Mean \pm SD)

	Virtual Reality (Experimental) Group (n=16)		Extraction (Control) Group (n=16)	
	Pretraining	Posttraining	Pretraining	Posttraining
Enamel	4.64 \pm 2.54	6.64 \pm 1.57	5.00 \pm 2.93	6.23 \pm 1.57
DEJ	5.27 \pm 1.27	6.36 \pm 1.36	5.15 \pm 2.42	6.81 \pm 1.89
Superficial dentin	3.45 \pm 2.34	7.42 \pm 1.06	3.91 \pm 1.70	6.01 \pm 1.10
Deep dentin/pulpal floor	0.36 \pm 0.47	1.76 \pm 0.32	0.35 \pm 0.52	1.25 \pm 0.49
Total	13.23 \pm 2.50	20.41 \pm 2.56	13.36 \pm 2.08	19.09 \pm 2.513

posttraining (day 5), each participant was asked to perform minimally invasive caries removal on one extracted tooth similar to pretraining.

The main outcome measure in both groups was performance scores assessed by an expert blinded to trainee and training status. The secondary outcome measures were tooth mass loss and task completion time. To determine the performance score, three-point scales were applied to four walls (buccal, lingual, mesial, distal), judged in four areas (enamel, DEJ, superficial dentin, deep dentin/pulpal floor), with 0 defined as "infected dentin left/pulp chamber perforation," 1 as "overprepared or overexcavated enamel/reaching sound dentin," 2 as "no undermined enamel/no carious enamel." The total maximum performance score was 26. Each tooth's mass was measured and recorded in grams before and after the caries removal procedure on a digital analytical balance accurate to 0.0001 g. The percentage of tooth mass removed for each tooth was calculated. The total time taken to complete the task was measured to an accuracy of 0.01 minute.

Statistical Analyses

The Wilcoxon test was used for nonparametric data and matched pairs to examine differences between pretraining and posttraining caries-removal performance scores in the same group. The Mann-Whitney test was used for unmatched data to detect any differences between the experimental and control groups. The dependent *t*-test and independent *t*-test were used to compare the tooth-removal and task-completion time within and between the experimental and control groups. Statistical significance was defined as a *p* value less than 0.05. All analyses were undertaken using SPSS version 21.0 (SPSS, Inc, Chicago, IL, USA). Results between the experimental and control groups were compared using an equivalence test for proportional differences (2 one-sided *t*-tests, [TOST]) with a 0.2 margin. The TOST method effectively tests the hypothesis that two

estimates are equivalent within a statistically computed equivalence range. The lower the *p* value, the more similar the estimates can be concluded to be, and if the *p* value is less than the critical cutoff (0.05), then the two estimates can be assumed to be statistically equivalent. Statistical tests with *p* values of less than 0.05 were considered significant.

RESULTS

Thirty-five sixth-year dental students were recruited. Three students were not admitted to the study due to their experience with VR simulation. None of the participants in the control or experimental groups dropped out before completing the posttraining assessment. Table 1 shows that the pretraining mean total performance scores of the experimental group (13.23 \pm 2.50) and control group (13.36 \pm 2.08) were almost identical. The Mann-Whitney test confirmed that there were no significant differences. The mean posttraining performance scores were significantly higher than the pretraining scores in both experimental (13.23 \pm 2.50 to 20.41 \pm 2.56) and control groups (13.36 \pm 2.08 to 19.09 \pm 2.51) (Wilcoxon, *p* < 0.05), indicating that performance significantly improved after training in both groups. The average posttraining performance score for the experimental group (20.41 \pm 2.56) was not significantly different from that obtained for the control group (19.09 \pm 2.51), indicating that performance improved similarly in minimally invasive caries-removal training with the micro-CT multilayered caries model and visuo-tactile VR simulator (experimental group) and training with carious extracted teeth (control group).

The equivalence test for proportional differences confirmed that participants in both groups had identical posttraining performance scores (TOST, 95% CI=0.92, 1; *p*=0.00). However, comparing the mean performance scores in four areas (enamel, DEJ, superficial dentin, deep dentin/pulpal floor), the average posttraining performance score of

Table 2. Tooth Mass Removed and Task Completion Time Between Caries Removal Training With Micro-CT Multilayered Caries Model and Visuo-Tactile VR Simulator (Experimental Group) and Training With Extracted Carious Teeth (Control Group) (Mean±SD)

	Virtual Reality (Experimental) Group (n=16)		Extraction (Control) Group (n=16)	
	Pretraining	Posttraining	Pretraining	Posttraining
Tooth mass removed (g)	4.98±2.61	5.68±2.48	5.87±3.41	6.73±2.38
Task completion time (s)	14.90±7.14	10.82±4.17	14.18±7.29	10.87±4.47



superficial dentin for the experimental group (7.42±1.06) was significantly greater than that obtained for the control group (6.01±1.10). Similarly, the average posttraining performance score of deep dentin/pulpal floor for the experimental group (1.76±0.32) was significantly greater than that obtained for the control group (1.25±0.49). There were no differences in tooth mass removed and task completion time after training in both groups (Table 2).

DISCUSSION

Differentiation and selective removal of infected and affected carious dentin is important in training minimally invasive caries treatment. Traditional caries removal in restorative treatment aims to eliminate all softened parts of a cavity, which is assumed to be mandatory to terminate the caries process. Some dental schools still teach removal of all lesions until reaching stain-free and “hard,” healthy tissue in the entire area.²⁶ However, caries progression does not always turn into worst-case scenarios such as pulpitis or pulp necrosis, despite leaving some areas of infected dentin. Many bacteria still exist in a cavity from which all soft dentin has been eliminated, regardless of the excavation system used.²⁷ Significantly lower organism activity would be achieved when active cariogenic mass and part of the demineralized dentin is removed; hence, excavation on a deep pulpal floor need not be aggressive.²⁸

Several techniques have been developed for removing carious layers selectively, such as conventional slow-speed tungsten carbide bur, caries detector application, chemical excavation, laser, and fluorescence-aided caries excavation (FACE), which is a direct method to clinically differentiate between infected and affected carious dentin. Because several oral microorganisms produce orange-red fluorophores as by-products of their metabolism (porphyrins), infected carious tissue will fluoresce, especially in the red fraction of the visible spectrum due to the presence of proto- and mesoporphyrins.²⁹ One study has shown that the number of bacteria remaining

after FACE excavation is statistically lower than after traditional or caries-detected excavation.³⁰

In the current study, we developed a multilayered caries model for minimally invasive visuo-haptic simulation using micro-CT. Our model represented real dental materials such as enamel, sound dentin, infected dentin, affected dentin, and dental pulp with different mechanical hardnesses. Furthermore, the model delivered different colors for separating infected dentin from affected dentin as guided by the FACE system for selectively removing the carious layers: red for infected dentin and brown for affected dentin. The simulator considered caries-removal training in a minimal intervention manner. FACE prevented widening the cavity size significantly by removing infected dentin effectively compared with other systems.³¹ We also presented high-speed or low-speed cutting with diamond or tungsten carbide burs, providing enamel cutting for cavity access or delicate caries excavation in the dentin layer.

Interactive visualization and tactile sensation from VR technology have opened new paradigms in clinical practice.¹² VR is a human-computer interface that facilitates highly interactive visualization and control of computer-generated, 3D-specific tissue models and their related components with sufficient detail and speed to simulate a sensorial experience similar to reality. The haptic systems provide force feedback through the tactile receptors in the skin and the proprioceptive receptors in muscles, tendons, and joints of the operator's hands.¹³ In a caries-removal procedure, tactile sensation in the fingers is essential because touching the surface can be as useful as seeing it. Force feedback in VR simulators reveals the advantage in calculus and caries detection.^{16,32} A multilayered virtual tooth model was generated to provide different tactile sensations in each layer of tooth structure that simulated the real experience in a haptic VR training system; thus, the participant felt a cutting perception similar to that of a real tooth by differential force feedback.

The results of a randomized controlled trial in this study showed the improvement in caries removal

outcomes for sixth-year dental students before and after participating in a designed training protocol. As in previous studies on clinical skill training,^{24,25} the participants showed that performance improvement in scores of minimally invasive caries removal was not different after training sessions with the VR simulator and the extracted teeth in a phantom head. The explanation for these results is that the VR simulator is designed specifically to mimic the same hand motions and visualization as those used during dental procedures. Our model uses the virtual 3D model of carious teeth reconstructed from micro-CT images similar to those of Yoshida and others,¹⁸ yet provides more detail in the infected and affected carious layers with different colors and hardnesses, which are helpful for visuo-tactile sensation. The students experienced caries removal in the same way as using a real tooth.

Interesting results were obtained regarding the caries removal in dentin. Students trained with the VR simulator had a better caries-removal performance score on the superficial and deep dentin layers, possibly due to the current VR simulator that contributes to the training of minimally invasive removal of carious dentin. The students were able to receive different color and force feedback when cutting through enamel, infected dentin, affected dentin, and pulp. They also received augmented feedback on the percentage of sound tooth structure and carious dentin removed from each layer during the operation. Moreover, changing from a high- to a slow-speed bur for cutting enamel and carious dentin was allowed in the current VR simulation. Some educators are concerned that students who become skillful with simulators might not be able to transfer these skills to the clinic,³³ but our students' posttraining performance confirmed that the minimally invasive caries-removal skills acquired on a VR simulator actually improved on real teeth.

Although VR simulation may require an initial investment in terms of software, costs must be balanced against those of traditional training. Nevertheless, VR training is becoming an attractive option as it requires little running cost; once bought, these devices are always available for use and allow for repeatable skills training. The limitation of this work is that students interact with a 3D model of a single tooth that is reconstructed from micro-CT images. It would be useful to incorporate more virtual environments of the whole clinical setting by using a head-mounted display to get true 3D and, especially, hand-tool alignment. More work should

be done to incorporate outcome scoring and video feedback to show where errors occur in the procedure.

CONCLUSIONS

The initial results from developing a multilayered caries model and visuo-tactile VR simulator for minimally invasive caries-removal training are very encouraging. Training on a VR simulator and conventional extracted teeth had equivalent effects in improving minimally invasive caries-removal performance. This simulator, with further refinement, has excellent potential to benefit the minimally invasive approach.

Acknowledgements

This study was supported by the National Research Council of Thailand and the Thailand Research Fund (RDG6050029) and partially supported through a fellowship from the Hanse-Wissenschaftskolleg Institute for Advanced Study, Delmenhorst, Germany to Haddawy and Suebnukarn.

Regulatory Statement

This study was conducted in accordance with all the provisions of the local human subjects oversight committee guidelines and policies of Thammasat University. The approval code for this study is 103/2559.

Conflict of Interest

The authors of this manuscript certify that they have no proprietary, financial, or other personal interest of any nature or kind in any product, service, or company that is presented in this article.

(Accepted 24 August 2017)

REFERENCES

1. Fejerskov O, & Kidd EAM (2003) *Dental Caries: The Disease and Its Clinical Management* Blackwell Munksgaard, Denmark.
2. Black GV (1908) *Operative Dentistry: The Technical Procedures in Filling Teeth* Medico-Dental Publishing Co, Chicago.
3. Tyas MJ, Anusavice KJ, Frencken JE, & Mount GJ (2000) Minimal intervention dentistry—A review. FDI Commission Project 1-97 *International Dental Journal* **50**(1) 1-12.
4. de Almeida Neves A, Coutinho E, Cardoso MV, Lambrechts P, & Van Meerbeek B (2011) Current concepts and techniques for caries excavation and adhesion to residual dentin *Journal of Adhesive Dentistry* **13**(1) 7-22.
5. Banerjee A, Watson TF, & Kidd EA (2000) Dentine caries: Take it or leave it? *Dental Update* **27**(6) 272-276.
6. Alleman DS, & Magne P (2012) A systematic approach to deep caries removal end points: The peripheral seal concept in adhesive dentistry *Quintessence International* **43**(3) 197-208.

7. Maltz M, Oliveira EF, Fontanella V, & Carminatti G (2007) Deep caries lesions after incomplete dentine caries removal: 40-month follow-up study *Caries Research* **41(6)** 493-496.
8. Schwendicke F, Dörfer CE, & Paris S (2013) Incomplete caries removal: A systematic review and meta-analysis *Journal of Dental Research* **92(4)** 306-314.
9. Kidd EA (2010) Clinical threshold for carious tissue removal *Dental Clinics of North America* **54(3)** 541-549.
10. Neves Ade A, Coutinho E, De Munck J, & Van Meerbeek B (2011) Caries-removal effectiveness and minimal-invasiveness potential of caries-excitation techniques: A micro-CT investigation *Journal of Dentistry* **39(2)** 154-162.
11. Ritman, EL (2004) Micro-computed tomography-current status and developments *Annual Review of Biomedical Engineering* **6(8)**185-208.
12. Bradley P (2006) The history of simulation in medical education and possible future directions *Medical Education* **40(3)** 254-262.
13. Westebring-van der Putten EP, Goossens RH, Jakimowicz JJ, & Dankelman J (2008) Haptics in minimally invasive surgery—A review *Minimally Invasive Therapy and Allied Technologies* **17(1)** 3-16.
14. Kusumoto N, Sohmura T, Yamada S, Wakabayashi K, Nakamura T, & Yatani H (2006) Application of virtual reality force feedback haptic device for oral implant surgery *Clinical Oral Implants Research* **17(6)** 708-713.
15. Arevalo CR, Bayne SC, Beeley JA, Brayshaw CJ, Cox MJ, Donaldson NH, Elson BS, Grayden SK, Hatzipanagos S, Johnson LA, Reynolds PA, & Schönwetter DJ (2013) Framework for e-learning assessment in dental education: A global model for the future *Journal of Dental Education* **77(5)** 564-575.
16. Steinberg AD, Bashook PG, Drummond J, Ashrafi S, & Zefran M (2007) Assessment of faculty perception of content validity of PerioSim, a haptic-3D virtual reality dental training simulator *Journal of Dental Education* **71(12)** 1574-1582.
17. Suebnukarn S, Phatthanasathiankul N, Sombatweroje S, Rhiemora P, & Haddawy P (2009) Process and outcome measures of expert/novice performance on a haptic virtual reality system *Journal of Dentistry* **37(9)** 658-665.
18. Yoshida Y, Yamaguchi S, Kawamoto Y, Noborio H, Murakami S, & Sohmura T (2011) Development of a multi-layered virtual tooth model for the haptic dental training system *Dental Materials Journal* **30(1)** 1-6.
19. Perry S, Bridges SM, & Burrow MF (2015) A review of the use of simulation in dental education *Simulation in Healthcare* **10(1)** 31-37.
20. Quinn F, Keogh P, McDonald A, & Hussey D (2003) A study comparing the effectiveness of conventional training and virtual reality simulation in the skills acquisition of junior dental students *European Journal of Dental Education* **7(4)** 164-169.
21. Bruker microCT (2017) Dual-energy microCT analysis; Retrieved online June 1, 2017, from: <http://bruker-microct.com/next/DualEnergy.pdf>
22. Buie HR, Campbell GM, Klinck RJ, MacNeil JA, & Boyd SK (2007) Automatic segmentation of cortical and trabecular compartments based on a dual threshold technique for in vivo micro-CT bone analysis *Bone* **41(4)** 505-515.
23. Wu X, Spencer SA, Shen S, Fiveash JB, Duan J, & Brezovich IA (2009) Development of an accelerated GVF semi-automatic contouring algorithm for radiotherapy treatment planning *Computers in Biology and Medicine* **39(7)** 650-656.
24. Suebnukarn S, Rhiemora P, & Haddawy P (2012) The use of cone-beam computed tomography and virtual reality simulation for pre-surgical practice in endodontic microsurgery *International Endodontic Journal* **45(7)** 627-632.
25. Suebnukarn S, Hataidechadusadee R, Suwannasri N, Suprasert N, Rhiemora P, & Haddawy P (2011) Access cavity preparation training using haptic virtual reality and microcomputed tomography tooth models *International Endodontic Journal* **44(11)** 983-989.
26. Kidd EA (2004) How "clean" must a cavity be before restoration? *Caries Research* **38(3)** 305-313.
27. Lager A, Thornqvist E, & Ericson D (2003) Cultivable bacteria in dentine after caries excavation using rose-bur or carisolv *Caries Research* **37(3)** 206-211.
28. Bjørndal L, Larsen T, & Thylstrup A (1997) A clinical and microbiological study of deep carious lesions during stepwise excavation using long treatment intervals *Caries Research* **31(6)** 411-417.
29. Lussi A, Hibst R, & Paulus R (2004) DIAGNOdent: An optical method for caries detection *Journal of Dental Research* **83(Spec No C)** C80-C83.
30. Lennon AM, Attin T, & Buchalla W (2007) Quantity of remaining bacteria and cavity size after excavation with FACE, caries detector dye and conventional excavation in vitro *Operative Dentistry* **32(3)** 236-241.
31. Zhang X, Tu R, Yin W, Zhou X, Li X, & Hu D (2013) Micro-computerized tomography assessment of fluorescence aided caries excavation (FACE) technology: Comparison with three other caries removal techniques *Australian Dental Journal* **58(4)** 461-467.
32. Thomas G, Johnson L, Dow S, & Stanford C (2011) The design and testing of a force feedback dental simulator *Computer Methods and Programs in Biomedicine* **64(1)** 53-64.
33. Kneebone RL, Nestel D, Vincent C, & Darzi A (2007) Complexity, risk and simulation in learning procedural skills *Medical Education* **41(8)** 808-814.

Queries for odnt-43-03-29

This manuscript/text has been typeset from the submitted material. Please check this proof carefully to make sure there have been no font conversion errors or inadvertent formatting errors. Allen Press.

Effectiveness of the Multilayered Caries Model and Visuo-Tactile Virtual Reality Simulator for Minimally Invasive Caries Removal: A Randomized Controlled Trial

ORIGINALITY REPORT

16%

SIMILARITY INDEX

10%

INTERNET SOURCES

14%

PUBLICATIONS

8%

STUDENT PAPERS

MATCH ALL SOURCES (ONLY SELECTED SOURCE PRINTED)

2%

★ www.thieme-connect.com

Internet Source

Exclude quotes On

Exclude matches < 15 words

Exclude bibliography On