

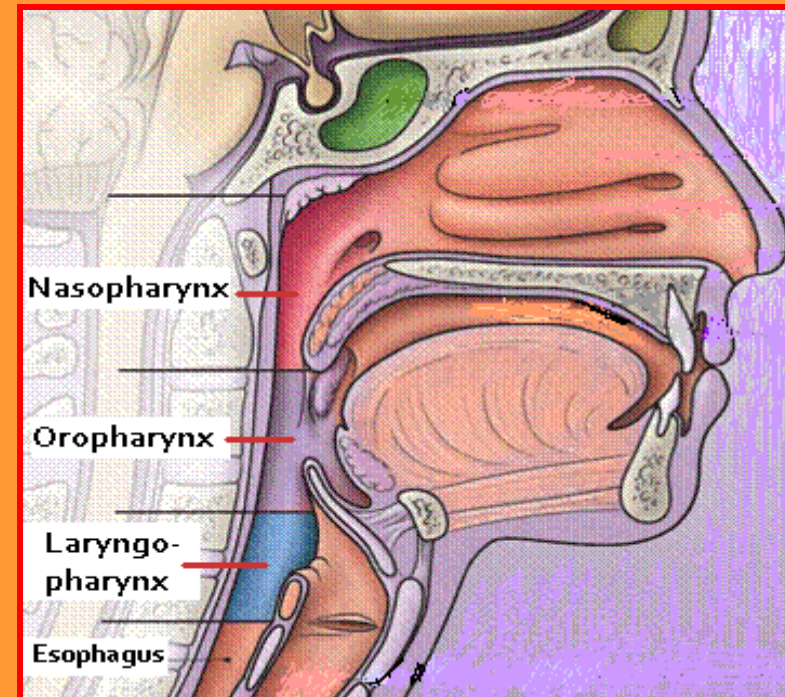


Pemeriksaan Leher & Tenggorok

FAUZAN ABDILLAH

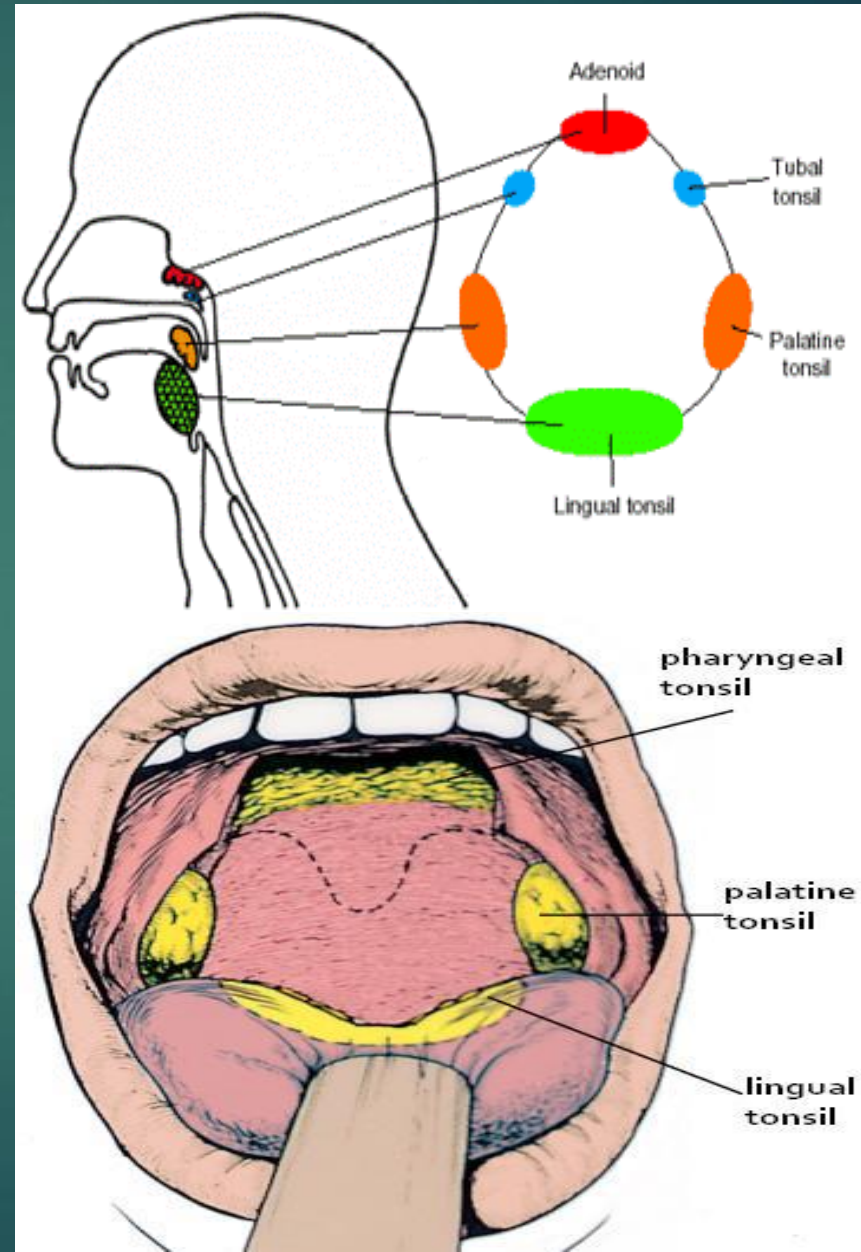
Struktur anatomi

- ▶ Faring → kantong fibromuskular spt corong : lebar di atas & bagian bawah menyempit
- ▶ Secara anatomi terdiri :
 - ▶ **Nasofaring**
 - ▶ **Orofaring**
 - ▶ **Hipofaring**



▶ **Anatomi tonsil**

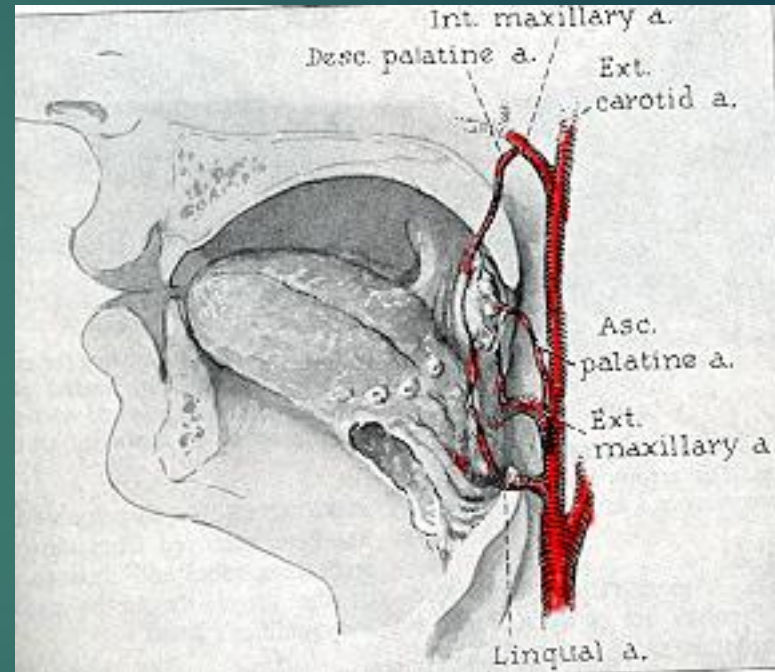
- ▶ terletak di nasofaring & orofaring
- ▶ terdiri → 3 pasang
 - ▶ Tonsil palatina
 - ▶ Tonsil faringal
 - ▶ Tonsil lingual
 - ▶ *Tonsil Gerlach*
- ▶ cincin waldeyer



Perdarahan

Tonsil palatina

- A. Palatina ascenden & descenden → cab a. carotis eks
- A. Maksilaris eksterna &
- A. Lingualis



Pemeriksaan

- ▶ Cuci tangan
- ▶ Pemakaian APD → Masker, goggles, sarung tangan, face shield, hazmat
- ▶ Pemakaian lampu kepala → atur fokus cahaya
- ▶ Posisi duduk → pasien lebih tinggi, lutut rapat & bersilangan dengan pemeriksa
- ▶ Spatula lidah

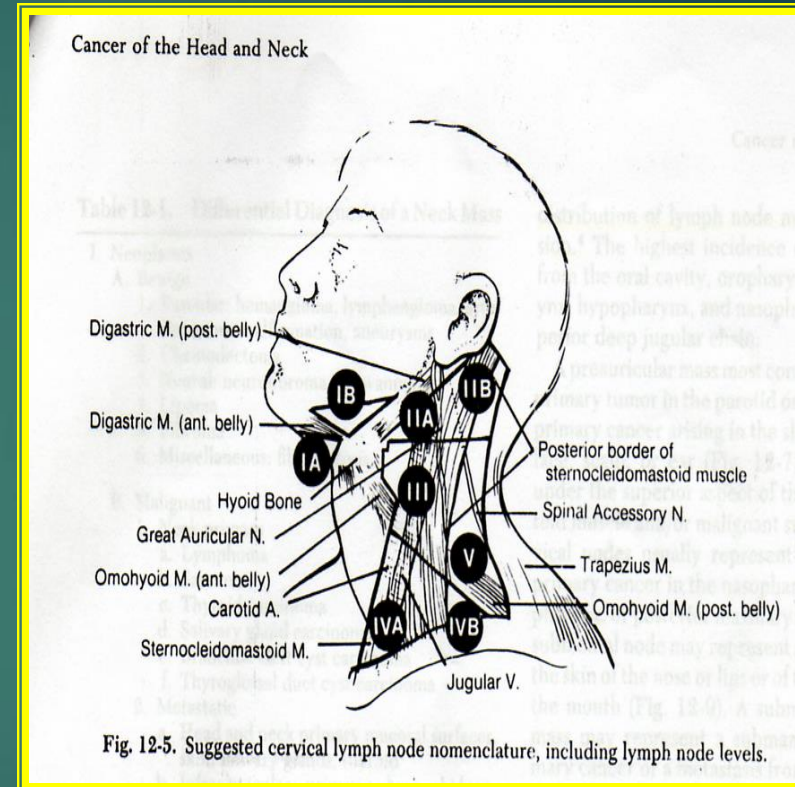


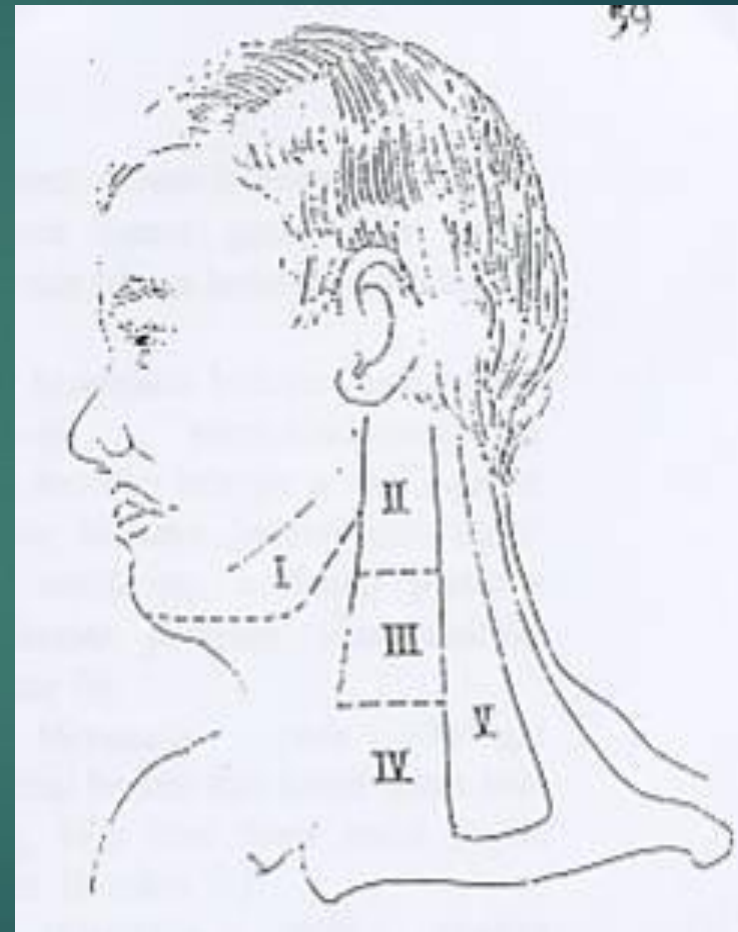
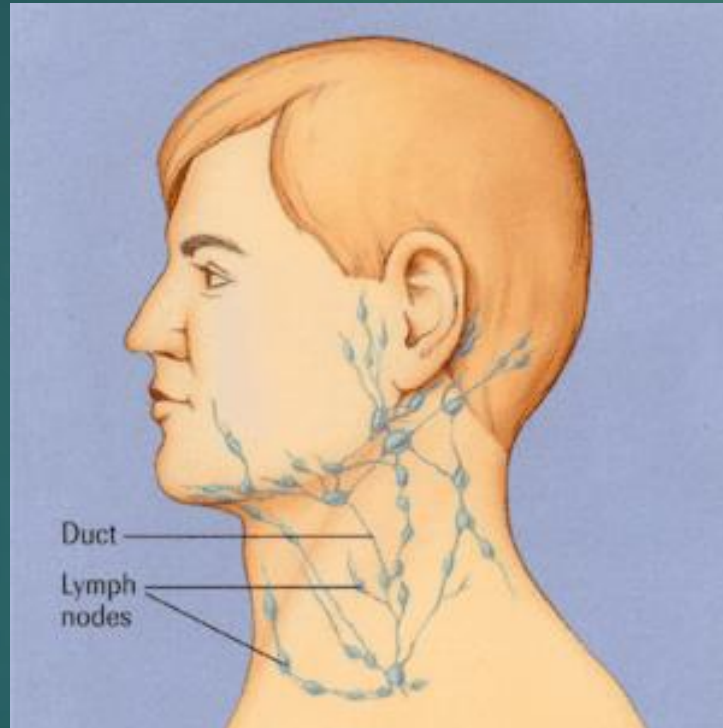
Penilaian

- Adakah trismus
- Pergerakan lidah & permukaan → parese, ulkus, *geographic tongue*
- Oral hygiene, gigi, mukosa pipi
- Palatum durum & molle → torus palatinus
- Arkus faring → simetris/ terdorong, hiperemis
- Tonsil → ukuran, kriptas, detritus
- Mukosa posterior faring → licin/granuler, hiperemis, menonjol
- Massa/ benda asing

Kelenjar leher

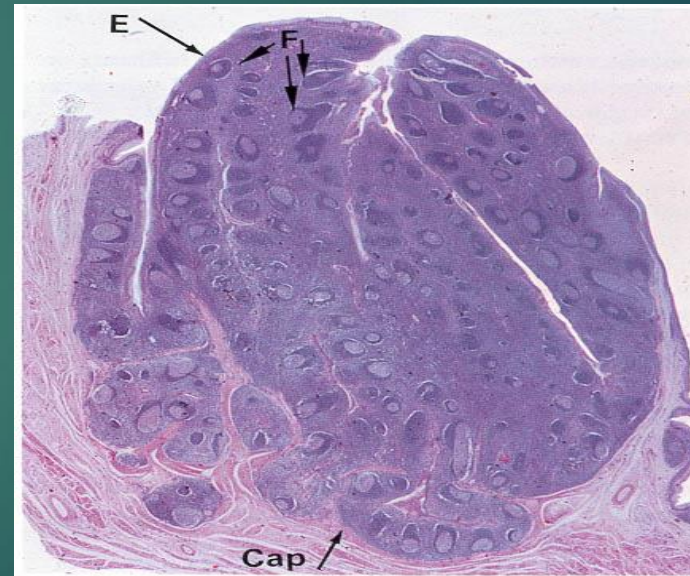
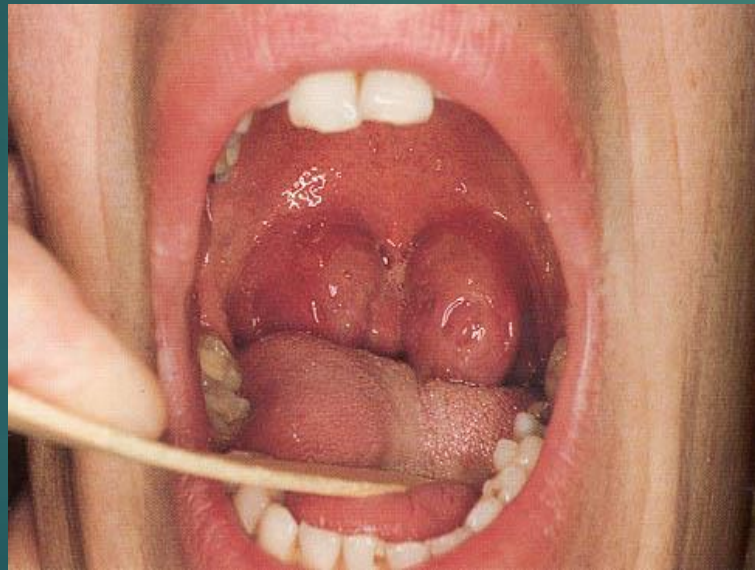
- ▶ Periksa di belakang pasien
- ▶ Terdapat VI level
- ▶ Jika ada pembesaran :
 - ▶ Ukuran
 - ▶ Konsistensi
 - ▶ Permukaan
 - ▶ Nyeri/ tidak
 - ▶ Perlekatan



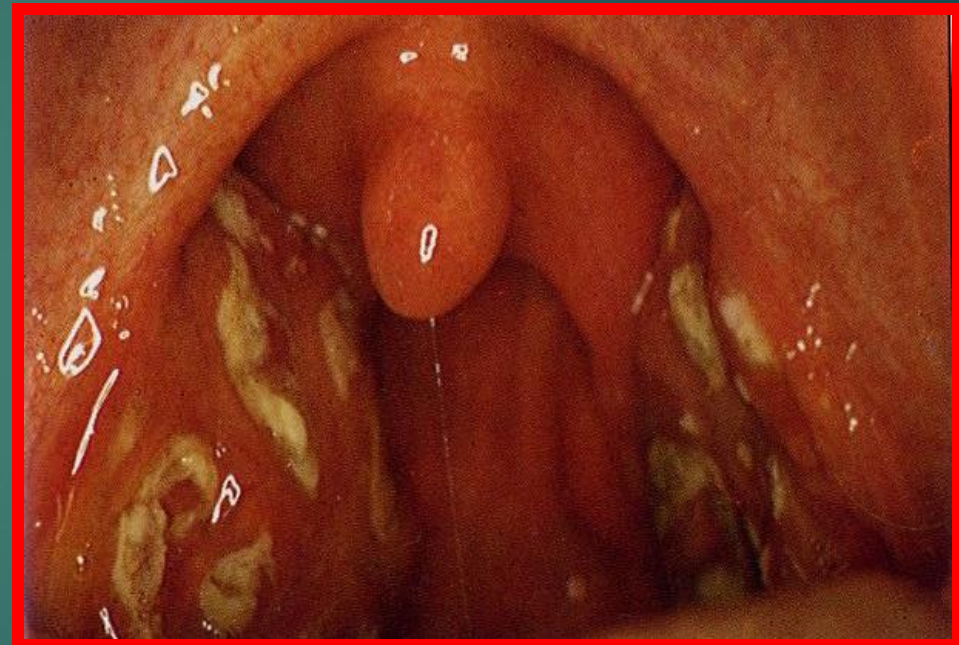
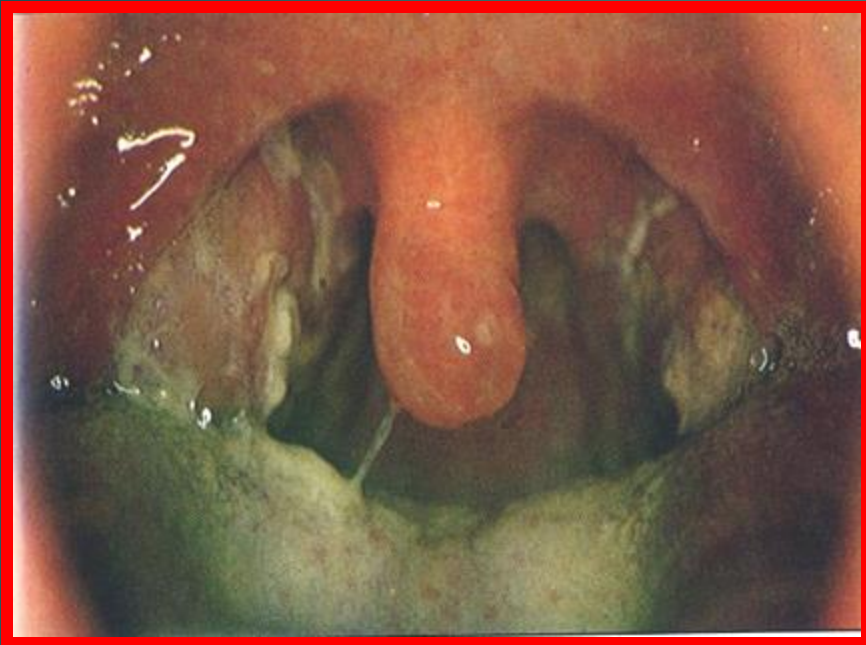


Kondisi yang dijumpai

- ▶ Hipertrofi tonsil



Tonsilitis akut & kronis



Terima kasih