


- 
- Evaluation of blood metal levels of hockey teams after playing on synthetic turf fields
 - Effects of low-dose filtered kretek cigarette smoke on bronchial smooth muscle in male Sprague-Dawley rats
 - Indwelling ureteral stenting negatively impacts sexual function transiently after endourological procedure among adult male and female patients: a prospective cohort study
 - Comparative analysis of KnockOut serum replacement and fetal bovine serum for in vitro culture of human dermal fibroblasts
 - Loneliness and depression levels as risk factors of pain in geriatric prostate cancer patients
 - Profile of multidrug-resistant bacteria causing urinary tract infections and outpatients in Jakarta in inpatients and Tangerang
 - Correlation of angle kappa with biometry and higher-order aberrations of cataract patients at Prof. Ngoerah Hospital Ophthalmology Clinicl
 - Secretome hypoxia-mesenchymal stem cells decrease tumor necrosis factor- α and interleukin-18 in kidney of type 2 diabetes mellitus model rats
 - Role of sex steroid hormone on hand grip strength and cognitive function in the elderly
 - Protective role of melatonin in ultraviolet radiation-induced oxidative stress in human skin photoaging
 - Childhood blindness from surge of advanced stage retinopathy of prematurity in premature infants during the COVID-19 pandemic: a case series
 - Release of retromalleolar flexor retinaculum and combined flexor digitorum longus and flexor hallucis longus Z-plasty in checkrein deformity: a case report



Is 'quorum quenching' a promising tool to combat antibiotic-resistant bacteria?

Naga Raju Maddela

249-250 abstract viewed: 641 PDF: 390 DOI: <https://doi.org/10.18051/UnivMed.2023.v42.249-250>

PDF

Time to treat the climate and nature crisis as one indivisible global health emergency

Kamran Abbasi, Parveen Ali, Virginia Barbour, Thomas Benfield, Kirsten Bibbins Domingo, Stephen Hancocks, Richard Horton, Laurie Laybourn Langton, Robert Mash, Peush Sahni, Wadeia Mohammad Sharief, Paul Yonga, Chris Zielinski

251-254 abstract viewed: 596 PDF: 306 DOI: <https://doi.org/10.18051/UnivMed.2023.v42.251-254>

PDF

Original Articles

Evaluation of blood metal levels of hockey teams after playing on synthetic turf fields

Esin GULLU, Abdulsamet EFDAL, Abdullah GULLU, Ihsan CETIN

255-262 abstract viewed: 835 PDF: 364 DOI: <https://doi.org/10.18051/UnivMed.2023.v42.255-262>

PDF

Effects of low-dose filtered kretek cigarette smoke on bronchial smooth muscle in male Sprague-Dawley rats

David Tjahyadi, Edy Parwanto, Sisca Sisca, Endrico Xavierees, Hosea Jaya Edy, Reza Aditya Digambiro, Ashaolu Victoria Oladimeji, Joey Joshua Vidova Tjahyadi, Laurentia Gabrielle

263-275 abstract viewed: 793 PDF: 383 DOI: <https://doi.org/10.18051/UnivMed.2023.v42.263-275>

PDF

Indwelling ureteral stenting negatively impacts sexual function transiently after endourological procedure among adult male and female patients: a prospective cohort study

Ferdy Bangun Kangsaputra, Nur Budiyo, Sakti Ronggowardhana Brodjonegoro

276-282 abstract viewed: 602 PDF: 306 DOI: <https://doi.org/10.18051/UnivMed.2023.v42.276-282>

PDF

Comparative analysis of KnockOut serum replacement and fetal bovine serum for in vitro culture of human dermal fibroblasts

Nur Ilham Risma Hidayati, Indra Kusuma, Eko Poerwanto

283-293 abstract viewed: 772 PDF: 336 DOI: <https://doi.org/10.18051/UnivMed.2023.v42.283-293>

PDF

Loneliness and depression levels as risk factors of pain in geriatric prostate cancer patients

Remziye CICI, Gulay YILMAZEL, Nur Pinar AYZ

294-302 abstract viewed: 665 PDF: 326 DOI: <https://doi.org/10.18051/UnivMed.2023.v42.294-302>

PDF

Profile of multidrug-resistant bacteria causing urinary tract infections in inpatients and outpatients in Jakarta and Tangerang

Yeva Rosana, Lina Herliyana, Grady Krisandi, Erike Anggraini Suwarsono

303-313 abstract viewed: 619 PDF: 337 DOI: <https://doi.org/10.18051/UnivMed.2023.v42.303-313>

PDF

Correlation of angle kappa with biometry and higher-order aberrations of cataract patients at Prof. Ngoerah Hospital Ophthalmology Clinic

Siska Siska, I Gusti Ayu Ratna Suryaningrum, Saphira Evani

314-319 abstract viewed: 562 PDF: 296 DOI: <https://doi.org/10.18051/UnivMed.2023.v42.314-319>

PDF

Secretome hypoxia-mesenchymal stem cells decrease tumor necrosis factor- α and interleukin-18 in kidney of type 2 diabetes mellitus model rats

Risky Chandra Satria Irawan, Agung Putra, Trisnadi Setyo, Shabrina Syifa Chaisani, Nurul Hidayah

320-328 abstract viewed: 654 PDF: 281 DOI: <https://doi.org/10.18051/UnivMed.2023.v42.320-328>

PDF

Review Article

Role of sex steroid hormone on hand grip strength and cognitive function in the elderly

Edy Parwanto, David Tjahyadi, Husnun Amalia, Nany Hairunisa, Hosea Jaya Edy, Ashaolu Victoria Oladimeji, Nouredine Djebli

329-345 abstract viewed: 673 PDF: 270 DOI: <https://doi.org/10.18051/UnivMed.2023.v42.329-345>

PDF

Protective role of melatonin in ultraviolet radiation-induced oxidative stress in human skin photoaging

Maria Veronica Putri Suyanto, I Gusti Ayu Widianti

346-359 abstract viewed: 1381 PDF: 368 DOI: <https://doi.org/10.18051/UnivMed.2023.v42.346-359>

PDF

Case Report

Childhood blindness from surge of advanced stage retinopathy of prematurity in premature infants during the COVID-19 pandemic: a case series

Dian Estu Yulia, Diajeng Ayesha Soeharto

360-367 abstract viewed: 523 PDF: 272 DOI: <https://doi.org/10.18051/UnivMed.2023.v42.360-367>

PDF

Release of retromalleolar flexor retinaculum and combined flexor digitorum longus and flexor hallucis longus Z-plasty in checkrein deformity: a case report

Komang Agung Irianto, Enrico Leonarto, Henry Ricardo Handoyo

368-373 abstract viewed: 536 PDF: 296 DOI: <https://doi.org/10.18051/UnivMed.2023.v42.368-373>

PDF

Editorial Board

Editor in Chief

- **Adi Hidayat**, [✉] (Scopus Id=7006069132) Department of Community Medicine, Trisakti University, Jakarta, Indonesia

Deputy Editor in Chief

- **Pusparini**, [✉] (Scopus Id=55929902800) Department of Clinical Pathology, Faculty of Medicine Trisakti University, Jakarta, Indonesia

Associate Editors

- **Nugroho Abikusno**, [✉] (Scopus Id=21633335800) Department of Nutritional Science, Faculty of Medicine, Trisakti University, Jakarta, Indonesia
- **Yenny**, [✉] (Scopus Id=37076227300) Department of Pharmacology and Therapeutics, Faculty of Medicine, Trisakti University, Indonesia

Editorial Board

- **Farhad Safarpour Dehkordi**, [✉] (Scopus ID= 55115690600) Department of Food Hygiene and Quality Control, College of Veterinary Medicine, University of Tehran, Tehran, Iran
- **Saddek Bouharati**, [✉] (Scopus Id=24066543000) Laboratory of Intelligent Systems, Setif University, Algeria
- **Daryoush Babazadeh**, [✉] (Scopus ID= 43360996700) Department of Clinical Sciences Aria Veterinary Hospital, Mashhad, Iran
- **Marzuki Isahak**, [✉] (Scopus Id=6504727198) Occupational Health Physician, Faculty of Medicine, University of Malaya, Malaysia
- **Gulay Yilmazel**, [✉] (Scopus Id= 55759265000) (Department of Public Health, Faculty of Medicine, Hitit University, Corum, Turkey, Turkey
- **Xin Sun**, [✉] (Scopus Id=7405620610) Department of Endocrinology and Metabolism, The First Affiliated Hospital of Soochow University, Suzhou, China
- **Phakkarawat Sittiprapaporn**, [✉] (Scopus Id=57192418814) Department of Anti-Aging and Regenerative Science School of Anti-Aging and Regenerative Medicine, Mae Fah Luang University, Bangkok, Thailand
- **Rachel Soemedi**, [✉] (Scopus Id=35424598100) Center for Biomedical Informatics, Brown University, Division of Biology and Medicine, United States, United States
- **Dhananjay Yadav**, [✉] (Scopus Id= 55779022200) Department of Medical Biotechnology Yeungnam University, Department of Medical Biotechnology, Yeungnam University, South Korea, Korea
- **Edhyana Sahiratmadja**, [✉] (Scopus Id=6506913121) Department of Biomedical Sciences, Faculty of Medicine, Padjadjaran University, Bandung, Indonesia
- **Erlangga Yusuf**, [✉] (Scopus Id= 35773013400) Department of Medical Microbiology and Infectious Disease, Erasmus University Medical Center, Rotterdam, The Netherlands, Belgium
- **Isnatin Miladiyah**, [✉] (Scopus Id=57200500004) Islamic University of Indonesia Yogyakarta, Indonesia
- **Toni Wandra**, [✉] (Scopus Id= 6603103477) Directorate of Postgraduate, Sari Mutiara Indonesia University, Medan, Indonesia
- **Muchtaruddin Mansyur**, [✉] (Scopus Id=37085506800) Department of Community Medicine, Universitas Indonesia, Jakarta, Indonesia

- **Roslida Abdul Hamid**,  (Scopus Id= 25028322900) Department of Biomedical Science, Universiti Putra Malaysia, Faculty of Medicine and Health Sciences, Pharmacology and Toxicology, Malaysia
- **Nuriye Büyükkayacı Duman**,  (Scopus Id=55835058800) Department of Obstetrics and Gynecology Nursing, Faculty of Health Sciences, Hitit University, Çorum, Turkey
- **Nany Hairunisa**,  (Scopus Id=56708804600) Universitas Trisakti, Indonesia
- **Patwa Amani**,  (Scopus Id= 57208445092) Universitas Trisakti, Indonesia
- **Prastiya Indra Gunawan**,  (Scopus Id=57073585000) Department of Pediatrics, College of Medicine, Airlangga University, Surabaya, Indonesia
- **Kathryn Effendi**,  (Scopus Id= 24343449600) Department of Pathology, School of Medicine, Keio University, Japan
- **Pravina Santhira Shagar**,  (Scopus Id= 57201268779) Public Health Menzies Education, Charles Darwin University, Australia
- **Noureddine Djebli**,  (Scopus Id= 55583318900) Université Abdelhamid Ibn Badis Mostaganem, Algeria
- **Leandro Dragueta Delfino**,  (Scopus Id= 57193927183) PostGraduate Program in Movement Sciences, Sao Paulo State University/UNESP, Brazil
- **Erica Kholinne**,  (Scopus Id= 57112598600) Universitas Trisakti, Indonesia
- **Juhi Aggarwal**,  (Scopus Id= 54784030500) Department of Biochemistry, Santosh Medical College & Hospital, Ghaziabad, Uttar Pradesh

ORIGINAL ARTICLE

pISSN: 1907-3062 / eISSN: 2407-2230

Effects of low-dose filtered kretek cigarette smoke on bronchial smooth muscle in male Sprague-Dawley rats

David Tjahyadi^{1*}, Edy Parwanto², Sisca², Endrico Xavierees³,
Hosea Jaya Edy⁴, Reza Aditya Digambiro⁵, Ashaolu Victoria Oladimeji⁶,
Joey Joshua Vidova Tjahyadi⁷, and Laurentia Gabrielle⁷

ABSTRACT

BACKGROUND

Kretek cigarettes contain less nicotine and tar than conventional cigarettes. Exposure to cigarette smoke occurs mainly in the respiratory tract, resulting in histometric changes. The aim of this study was to evaluate the effect of filtered kretek cigarette smoke on bronchial histometric measurements in male Sprague-Dawley rats.

METHODS

An experimental laboratory study was conducted involving 18 male Sprague-Dawley rats, aged 2-3 months, ranging from 150 to 250 grams in body weight. They were randomized into group 1 (controls) and experimental groups 2 and 3. Group 2 was exposed to filtered cigarette smoke at a dose of 1 stick/day and group 3 to 2 sticks/day. Treatment time for all groups was 30 days. Observation of bronchial histometric measurements of the lumen include, length, width, area, and perimeter. In addition, the bronchial mucosal and smooth muscle layers were also measured. The one way-ANOVA test was used to analyze the data.

RESULTS

The mean area and mean perimeter of the bronchial lumen of the rats were significantly greater in group 1 than in groups 2 and 3 ($p=0.000$). The mean bronchial smooth muscle area of the rats in group 1 was smaller than the mean in group 2, which was in turn smaller than the mean in group 3 ($p=0.000$). Apparently the rats in the treatment groups had undergone bronchoconstriction.

CONCLUSION

Exposure to filtered kretek cigarette smoke at a dose of 1 stick/day as well as 2 sticks/day for 30 days caused bronchial mucosal hyperplasia and bronchoconstriction in male rats.

Keywords: Filtered kretek cigarette, bronchial histometric measurements, bronchial hyperplasia, bronchoconstriction, rats

¹Department of Histology,

Faculty of Medicine,
Universitas Trisakti, Indonesia

²Department of Biology,
Faculty of Medicine,
Universitas Trisakti, Indonesia

³Department of Biochemistry,
Faculty of Medicine,
Universitas Trisakti, Indonesia

⁴Study Program of Pharmacy,
Faculty of Math and Natural Sciences,
Universitas Sam Ratulangi, Indonesia

⁵Department of Anatomical Pathology,
Faculty of Medicine,
Universitas Trisakti, Indonesia

⁶Department of Chemistry,
Loyola Institute of Frontier Energy,
Loyola College, Chennai, India

⁷Medical Science Study Program,
Faculty of Medicine,
Universitas Trisakti, Indonesia

*Correspondence:

David Tjahyadi
Department of Histology,
Faculty of Medicine,
Universitas Trisakti
Jl. Kyai Tapa, Kampus B, No.260
Grogol 11440, Jakarta-Indonesia
Email: davesaboch@trisakti.ac.id
ORCID ID: 0000-0003-1154-193X

Date of first submission, January 27, 2023

Date of final revised submission,
September 7, 2023

Date of acceptance, September 18, 2023

This open access article is distributed
under a Creative Commons Attribution-
Non Commercial-Share Alike 4.0
International License

Cite this article as: Tjahyadi D, Parwanto E, Sisca, Xavierees E, Edy HJ, Digambiro RA, Oladimeji AV, Tjahyadi JJV, Gabrielle L. Effects of low-dose filtered kretek cigarette smoke on bronchial smooth muscle in male Sprague-Dawley rats. *Univ Med* 2023;42:263-75. doi: 10.18051/UnivMed.2023.v42:263-275



DOI: <http://dx.doi.org/10.18051/UnivMed.2023.v42:263-275>

Copyright@Author(s) - <https://univmed.org/ejurnal/index.php/medicina/article/view/1426>

INTRODUCTION

Kretek cigarettes are known for their characteristic content of a mixture of tobacco, flower buds of the clove tree, and flavors.^(1,2) In addition to kretek cigarettes, a substantial proportion of the Indonesian population smokes conventional cigarettes, and is therefore classified as consistently consuming tobacco, so that Indonesia is included as a third world country.⁽³⁾ Recent research suggests that kretek cigarettes contain chemicals, including eugenol, menthol, and flavor chemicals. Eugenol is exclusively found in kretek cigarettes and not in other types of cigarettes.⁽²⁾ In addition to containing these compounds, kretek cigarettes have also been demonstrated to produce high emissions of particulate matter.⁽⁴⁾ A systematic review showed that the existing studies suggest that the habitual use of kretek cigarettes can increase the risk of a range of health problems, including oral, cardiovascular, and respiratory diseases.⁽⁵⁾

Based on identical amounts of total particulate matter (TPM) in cigarette smoke, kretek cigarettes are less toxic than other cigarettes, such as American-blended cigarettes.⁽¹⁾ In addition, the results of *in vitro* testing demonstrated that kretek cigarette smoke is less toxic to cells, and less mutagenic. Moreover, the results of *in vivo* testing demonstrated that kretek cigarette smoke is less toxic to the respiratory tract.⁽¹⁾

There are more than 4000 types of chemical substances contained in cigarettes that have been identified.⁽⁶⁾ Cigarette smoke contains about 8% solid particles and 92% gases.⁽⁷⁾ In addition, nicotine in cigarettes is important to pay attention to because it is addictive.⁽⁸⁾ In addition to these additives, there is also a radioactive component, namely ²¹⁰Po, which is a carcinogen.⁽⁹⁾ These substances in cigarette smoke are inhaled from the mouth into the alveoli so that they are deposited along the respiratory tract.⁽¹⁰⁾ As a result, cigarette smoke causes abnormalities, and can cause diseases of the respiratory system.⁽¹¹⁾ In addition, cigarette smoke also contains free radicals that

are one of the causes of permanent lung tissue damage called chronic obstructive pulmonary disease (COPD),⁽¹²⁾ leading to irreversible destruction of the terminal bronchioles.⁽¹³⁾ It has been proven that the main cause of COPD is cigarette smoke.⁽¹⁴⁾ In the application of COPD diagnosis in humans, qualitative and quantitative assessments are required.⁽¹⁵⁾

The results of previous studies indicate that cigarette smoke causes a decrease in airway diameter.⁽¹⁶⁾ Other results show that smoking actively affects the human bronchial epithelium.⁽¹⁷⁾ In addition to cigarette smoke, 2,3-pentanedione vapor causes injury to the epithelium lining the respiratory tract of rats.⁽¹⁸⁾ Cigarette smoke also causes a stress effect on the respiratory system, leading to bronchopulmonary dysplasia.⁽¹⁹⁾ It has also been demonstrated that degenerative bronchiolar changes can occur in rat lung injury.⁽²⁰⁾ Previous studies have demonstrated the effect of cigarette smoke on airway smooth muscle cell proliferation and function.⁽²¹⁾ The thickness of the smooth muscle layer in the bronchioles can be influenced by several factors, including exposure to chemicals.⁽²²⁾ Other study has shown that the smooth muscle of the bronchioles affects the morphology and function of the rat airways.⁽²³⁾ Changes in the thickness of the bronchiolar smooth muscle layer are important to know in relation to exposure to cigarette smoke. This relates to the effect of smooth muscle thickness on the bronchiolar area and perimeter.⁽²³⁾

In addition to what has been described previously, cigarette smoke induces dysregulation that affects function in respiratory epithelial cells. Toxic substances in cigarette smoke are inhaled and pass into the epithelial cells of the respiratory tract,⁽²⁴⁾ for example ciliated cells and goblet cells.^(25, 26) Previous studies demonstrated that ciliated epithelial cells are positively correlated with bronchial lumen area, and negatively correlated with airflow through the bronchi.⁽²⁶⁾ Therefore, it is important to measure the area and perimeter of the bronchial lumen. This is related to respiratory epithelial cells affecting the lumen of the bronchus.

Besides causing dysregulation and affecting respiratory epithelial cells, toxic compounds in cigarette smoke also cause fibrosis of lung tissue. It has been demonstrated that toxic compounds increase pulmonary collagen accumulation, leading to pulmonary fibrosis.⁽²⁷⁾ In this connection, pulmonary fibrosis occurs due to the formation of scar tissue that interferes with lung function.⁽²⁸⁾ It has been demonstrated that inhalation of toxic compounds causes inflammation,^(29,30) progressive lung injury,⁽²⁹⁾ and fibrosis in the rat.^(18,29,31) As with COPD, morphometric measurements have been made in lung cystic fibrosis.⁽³²⁾

It has been demonstrated that unfiltered cigarettes were smoked at a lower rate during the trial than filtered cigarettes ($p < 0.05$). In addition, it was also demonstrated that there was no difference in nicotine content or dependence (intention to quit smoking) between unfiltered and filtered cigarette smokers ($p > 0.05$).⁽³³⁾ The difference between our study and the previous studies was that in this study we used filtered kretek cigarettes.

The choice of a low dose of conventional cigarettes as well as herbal cigarettes has been made previously, namely using a dose of 2 sticks/day against *Mus musculus* to obtain a picture of pulmonary histology. The group exposed to conventional cigarette smoke suffered from edematous lesions with a score of 0.7, inflammatory cell infiltration with a score of 3, and destruction of the alveolar septum with a score of 3.⁽³⁴⁾

The term histometrics is used for identification and authentication based on unique biological characteristics at the tissue level.⁽³⁵⁾ Research focusing on histometrics has been carried out, and the data are expressed quantitatively.⁽³⁶⁾ In our study, in contrast with previous studies, we evaluated the effect of filtered kretek cigarettes at doses of 1 stick/day or 2 sticks/day for 30 days on rat bronchial histometric measurements. Therefore, the aim of this study was to evaluate the effect of filtered kretek cigarette smoke on bronchial histometric measurements in male Sprague-Dawley rats.

METHODS

Research design

An experimental laboratory study was carried out at *Laboratorium Penelitian dan Pengujian Terpadu* [(LPPT) (Integrated Research and Testing Laboratory)] Unit 4, Universitas Gadjah Mada. Histological observations of bronchial histometrics were carried out at the Biology Laboratory, Faculty of Medicine, Universitas Trisakti, Jakarta, Indonesia. This research was conducted from September 2022 to June 2023.

Animals

The minimum and maximum sample sizes for one-way ANOVA using the between-subject error (DF) is calculated as: $DF = N - k = kn - k = k(n - 1)$, where N = total number of subjects, k = number of groups, and n = number of subjects per group.⁽³⁷⁾ The minimum $n = 10/k + 1$ and maximum $n = 20/k + 1$, so the minimum $n = 10/3 + 1 = 4.3 =$ rounded up to 5 animals/group and maximum $n = 20/3 + 1 = 7.7 =$ rounded down to 7 animals/group. In the proposed study, between 5 and 7 animals per group are required. This study involved 6 male rats of the *Rattus norvegicus* Sprague-Dawley strain per group, that were 2-3 months old and weighed 150-250 grams. The Sprague-Dawley rats were obtained from the Integrated Research and Testing Laboratory Unit 4, Universitas Gadjah Mada, and were housed in individual cages. The experimental room had a temperature of $26 \pm 2^\circ\text{C}$, humidity $55 \pm 5\%$, and artificial fluorescent lights (12:12 hours light and dark cycle). The rats were free of specific pathogens and were kept isolated from other laboratory animals. They were housed in air-filtered cages and provided with standard laboratory feed and fresh water ad libitum.

Smoke inhalation exposure

At the beginning of the study, the rats were acclimatized for 1 week. During acclimatization, the rats were given food and drink, but no treatment. After acclimatization, random grouping was carried out. The rats were randomly

subdivided into 3 groups; group 1 was the control group, where the rats breathed normal air without being exposed to filtered kretek cigarette smoke; group 2 was the group of rats exposed to filtered kretek cigarette smoke at a dose of 1 stick/day for 30 days and group 3 was the group of rats exposed to filtered kretek cigarette smoke at a dose of 2 sticks/day for 30 days. Exposure to filtered kretek cigarette smoke was carried out in a smoking chamber measuring 45 x 35 x 20 cm (31500 cm³). The oxygen valve in the smoking chamber is opened first, then the filtered kretek cigarettes are installed at the end of the pipe connected to the pump. After the pump is turned on, the filtered kretek cigarettes are burned so that the smoke enters the smoking chamber to be inhaled by the rats. The animals were placed in the exposure port of the machine so that only the snouts protruded into the chamber. The first group was sham-exposed (controls) in a separate chamber of the machine and went through the same exposure sequence but without the cigarette in the holder. The second group was exposed to the smoke of 1 cigarette. The third group was exposed to the smoke of 2 cigarettes of the same type. Smoking was carried out with groups 2 and 3 for 10 minutes in the morning. After 30 days of treatment (the length of time being based on preliminary studies), immediately after the last exposure session, the animals were anesthetized with ketamine 100 mg/kg body weight, and xylazine 10 mg/kg body weight intra-peritoneally. Afterwards, the animals were euthanized, then the lungs were taken and collected in 10% neutral buffered formalin (NBF) solution, to make histological preparations.

Hematoxylin eosin staining

Right lobe lung tissue was fixed in 10% NBF. Next, the tissues were dehydrated by being transferred consecutively into alcohol at concentrations of 70%, 80%, 90%, and 96%, respectively. Dehydration time is 2 hours for each alcohol concentration. The next step is clearing using xylol, then embedding and blocking. Lung tissue in the paraffin block was cut using a microtome, with a thickness of 5 µm. The tissue

was stained with hematoxylin for 5 minutes, then washed with running tap water for 5 minutes. Next, the tissue was dipped in 1% acidic alcohol (1% HCl in 70% alcohol) for a few seconds. Bluing is done by rinsing under running tap water, dipping in ammonia water until the area turns blue, followed by washing with tap water. The preparation is then counterstained with 1% eosin for 10 minutes, then washed with tap water for 5 minutes. After counterstaining, the section is dehydrated with alcohol, the preparation is cleaned with xylol. The last step is mounting and labeling.

Masson's Trichrome staining

Sections of lung tissue of 5 µm thickness from paraffin blocks were deparaffinized, washed with water, then treated with Lugol's iodine for 15 minutes, to remove possible traces of mercury pigment, and washed with water. Subsequently 5% sodium thiosulphate solution is added and left for 3 minutes, then washed with water for at least 10 minutes. The preparation is then stained with hematoxylin for 3 minutes, dipped quickly into 1% acid alcohol 3 times, and washed with water. Next the section is immersed in acid fuchsin for 5 minutes, washed with distilled water, immersed in phosphomolybdic acid solution for 5 minutes, and left to dry. The next step is to immerse the section in methyl blue solution for 5 minutes, wash with distilled water, immerse in 1% acetic acid for 2 minutes, then dehydrate in serial solutions of graded alcohols and clear with xylol. The last step is mounting and labeling.

Scanning electron microscope

Lung tissue samples were taken from the right lobe. After fixation, the sample was positioned, then coated and analyzed under a scanning electron microscope (SEM). The SEM used for observation was of the JEOL 6510 LA series made in Japan.

Bronchial histometric measurements

Images of the preparations were documented with Optilab Advance Plus and Image Raster 3 by PT MICONOS, Special

Region of Yogyakarta, Indonesia. The programs are available at <https://miconos.ac.id/new/support/download>. The bronchial histometric measurements of the lumen include length, width, area, and perimeter. In addition, the area and perimeter of the bronchial mucosal and bronchial smooth muscle layers were also measured. The bronchial histometric measurements of the rat lung was performed by three observers.

Statistical analysis

The measured data is expressed as the mean \pm standard deviation. Data analysis between groups used the one way-analysis of variance test. Significant differences between the groups were further tested by Tukey post hoc analysis (honestly significant difference, HSD). All statistical analysis tests were performed at the significance level of $p < 0.05$.

Ethical clearance

The Ethical Clearance Commission for preclinical research of the Integrated Research and Testing Laboratory, Universitas Gadjah Mada has approved this study under No. 00012/04/LPPT/VI/2022.

RESULTS

After treatment, the mean lung weights of the Sprague-Dawley rats in groups 1 to 3 were 1.92 ± 0.15 g, 1.9 ± 0.11 g, and 2.03 ± 0.17 g, respectively. There was no significant difference

in lung weight of the rats between groups 1, 2 and 3 ($p=0.281$).

Bronchial wall appearance of a Sprague-Dawley rat, presented in Figure 1.

The bronchial walls in group 1 showed a normal histological structure (Fig. 1. A), whereas in group 2 they showed an abnormal histological structure, namely hyperplasia of the bronchial mucosal layer (Figure 1. B). Group 3 of the Sprague-Dawley rats showed bronchoconstriction (Fig. 1. C).

Observations of the lungs of the Sprague-Dawley rats using a light microscope and SEM are presented in Figure 2.

Qualitative appearance of bronchial walls showing differences in bronchial lumen, bronchial mucosal layer, and bronchial smooth muscle cells clearly visible on H&E staining (Fig. 2 A, B, C). Likewise, it was shown qualitatively that differences in bronchial collagen accumulation were clearly seen by Masson's trichrome staining which demonstrated that the rats in groups 2 and 3 experienced more collagen accumulation than those in group 1 (Fig. 2 D, E, and F). The results of observations using SEM showed that qualitatively there were differences in lung appearance of the Sprague-Dawley rats between groups 1, 2, and 3 (Fig. 2 G, H, and I).

Bronchial histometric comparison of Sprague-Dawley rats is presented in Figure 3.

Effect of filtered kretek cigarette smoke on the bronchial lumen in Sprague-Dawley rats is presented in Table 1.

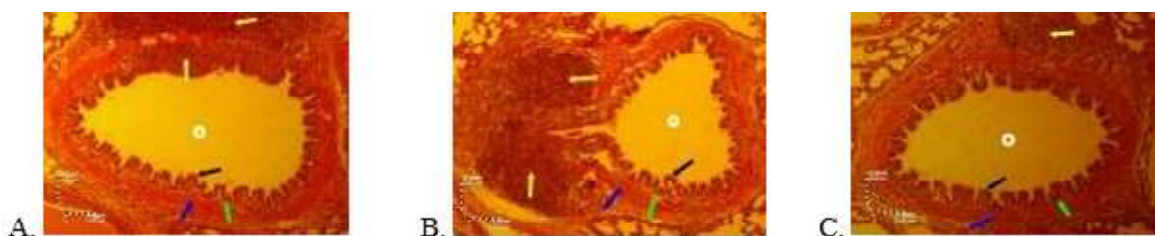


Figure 1. Bronchial wall appearance of a Sprague-Dawley rat with H&E stain, magnification of 100 x. A=Group 1 (controls), rats breathe normal air without exposure to filtered kretek cigarette smoke. B=Group 2, the group of rats exposed to filtered kretek cigarette smoke at a dose of 1 stick/day for 30 days of treatment. C=Group 3, group of rats exposed to filtered kretek cigarette smoke at a dose of 2 sticks/day for 30 days of treatment.

H&E=hematoxylin & eosin; black arrow=respiratory epithelium; lime-colored arrow=lamina propria; blue arrow=smooth muscle layer; yellow arrow=bronchus-associated lymphoid tissue; white circle=bronchial lumen

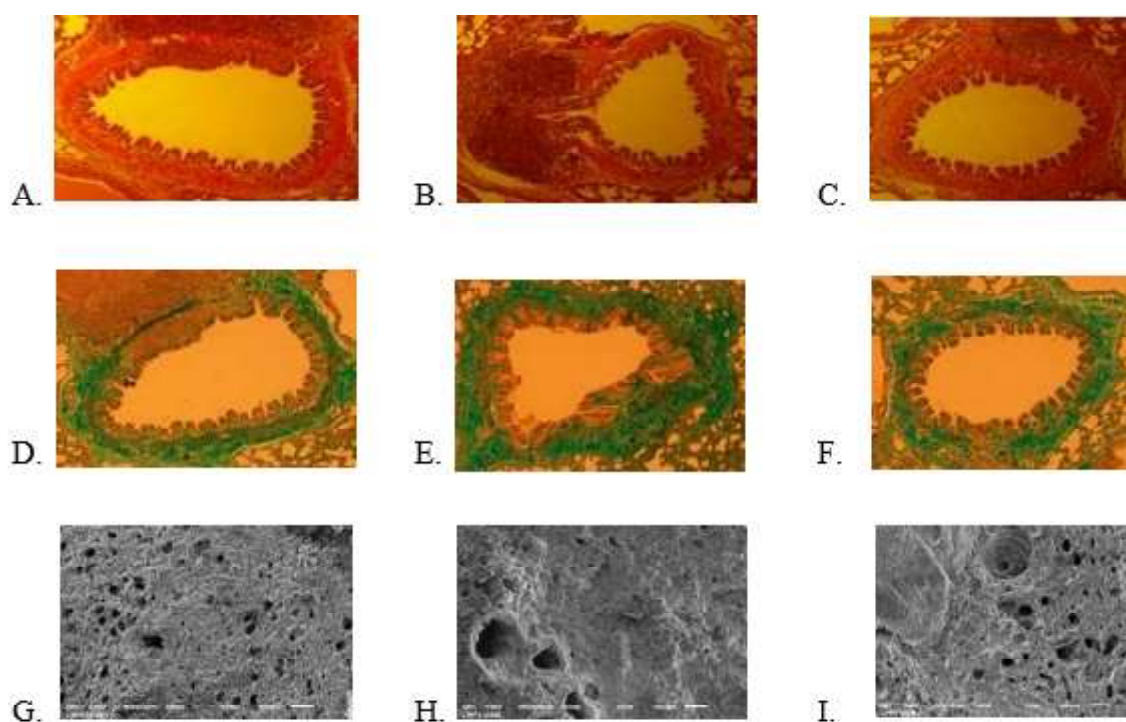


Figure 2. Lung appearance of Sprague-Dawley rats. Lungs of Sprague-Dawley rats stained with hematoxylin & eosin observed using a light microscope at 100x magnification in group 1 (A), group 2 (B), and group 3 (C). Lungs of Sprague-Dawley rats stained with Masson's trichrome observed using a light microscope at 100x magnification in group 1 (D), group 2 (E), and group 3 (F). Lungs of Sprague-Dawley rats observed using the scanning electron microscope at 100x magnification in group 1 (G), group 2 (H), and group 3 (I). Group 1 (control), the rats breathe normal air without exposure to filtered kretek cigarette smoke. Group 2, the group of rats exposed to filtered kretek cigarette smoke at a dose of 1 stick/day for 30 days of treatment. Group 3, group of rats exposed to filtered kretek cigarette smoke at a dose of 2 sticks/day for 30 days of treatment.

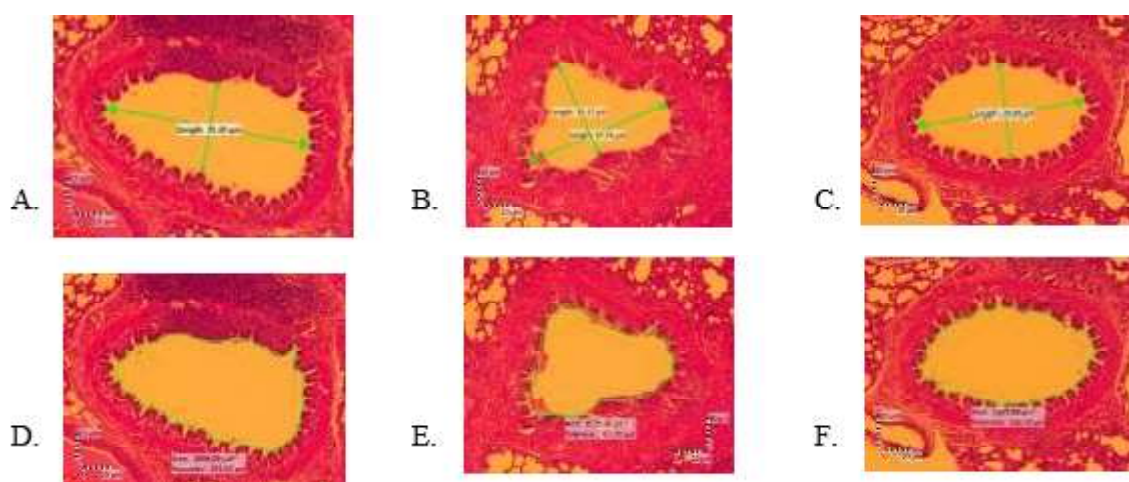


Figure 3. Bronchial histometric comparison of the Sprague-Dawley rats. The length and width of the bronchial lumen stained with hematoxylin & eosin, 100x magnification, in group 1 (A), group 2 (B), and group 3 (C). The area and circumference of the bronchial lumen stained with hematoxylin & eosin, magnification 100x, in group 1 (D), group 2 (E), and group 3 (F). Group 1 (control), rats breathe normal air without exposure to filtered kretek cigarette smoke. Group 2, the group of rats exposed to filtered kretek cigarette smoke at a dose of 1 stick/day for 30 days of treatment. Group 3, group of rats exposed to filtered kretek cigarette smoke at a dose of 2 sticks/day for 30 days of treatment.

Table 1. Effect of filtered kretek cigarette smoke on the bronchial lumen in male Sprague-Dawley rats

Bronchial lumen	Treatment groups			p value
	Group 1 (n=6)	Group 2 (n=6)	Group 3 (n=6)	
Length (µm)	83.94 ± 4.94	65.61 ± 7.72	54.94 ± 6.43	0.000
Width (µm)	52.06 ± 2.83	35.96 ± 5.98	35.42 ± 7.54	0.000
Perimeter (µm)	189.79 ± 4.04	161.66 ± 1.48	156.19 ± 5.21	0.000
Area (µm) ²	2048.43 ± 63.73	1514.79 ± 57.98	1541.07 ± 78.18	0.000

Note: Group 1 (control), rats breathe normal air without exposure to filtered kretek cigarette smoke. Group 2, the group of rats exposed to filtered kretek cigarette smoke at a dose of 1 stick/day for 30 days of treatment. Group 3, group of rats exposed to filtered kretek cigarette smoke at a dose of 2 sticks/day for 30 days of treatment

The length, width, area, and perimeter of the bronchial lumen of the Sprague-Dawley rats differed significantly between the groups (p=0.000) (Table 1). The results of the Tukey post hoc analysis of the bronchial lumen is shown in Table 2. The length of the bronchial lumen of the Sprague-Dawley rats in group 1 was greater than that in groups 2 and 3 (p=0.000), and was greater in group 2 than in group 3 (p=0.012). The width of the bronchial lumen of the Sprague-Dawley rats differed between groups (p=0.000). It was greater in group 1 than in groups 2 and 3 (p=0.000), but was not significantly different between groups 2 and 3 (p=0.874). The area of the bronchial lumen of the Sprague-Dawley rats differed between groups (p=0.000). The area was greater in group 1 than in groups 2 and 3 (p=0.000), but was not significantly different in groups 2 and 3 (p=0.508). The perimeter of the bronchial lumen of the Sprague-Dawley rats differed between groups (p=0.000) and was greater in group 1 compared to groups 2 and 3 (p=0.000); similarly it was greater in group 2 than in group 3 (p=0.028) (Table 2). Based on Fig. 3 and Table 1, it is apparent that the bronchial lumen of the rats has undergone bronchoconstriction.

The effect of filtered kretek cigarette smoke on the bronchial mucosal layer and bronchial smooth muscle layer in Sprague-Dawley rats is presented in Table 3.

The bronchial mucosa in group 1 is normal, while in group 2 and 3 it has undergone hyperplasia. Bronchial mucosal area, “mucosal perimeter, smooth muscle area, and “smooth muscle perimeter differ between groups (p=0.000)

(Table 3). Tukey post hoc analysis of bronchial mucosa and bronchial smooth muscle is shown in Table 4. The area of the bronchial mucosa in group 1 was greater than that of group 2 and group 3 (p=0.000) and also greater in group 2 than in group 3 (p=0.001). The “mucosal perimeter in groups 1 and 3 was lower than that of group 2 (p=0.000), but it was not different between group 2 and group 3 (p=0.763). The bronchial smooth muscle area in group 1 was smaller than in group 2; similarly it was smaller in group 3 than in group 2 (p=0.000). The “bronchial smooth muscle perimeter of the Sprague-Dawley rats in group 1 was shorter than that in group 2

Table 2. Post Hoc Tukey test of bronchial lumen in male Sprague-Dawley rats

Bronchial lumen		p value
Length (µm)	Group 1 vs Group 2	0.000
	vs Group 3	0.000
	Group 2 vs Group 3	0.012
Width (µm)	Group 1 vs Group 2	0.000
	vs Group 3	0.000
	Group 2 vs Group 3	0.874
Perimeter (µm)	Group 1 vs Group 2	0.000
	vs Group 3	0.000
	Group 2 vs Group 3	0.028
Area (µm)	Group 1 vs Group 2	0.000
	vs Group 3	0.000
	Group 2 vs Group 3	0.508

Notes: Group 1 (control), rats breathe normal air without exposure to filtered kretek cigarette smoke. Group 2, the group of rats exposed to filtered kretek cigarette smoke at a dose of 1 stick/day for 30 days of treatment. Group 3, group of rats exposed to filtered kretek cigarette smoke at a dose of 2 sticks/day for 30 days of treatment

Table 3. Effect of filtered kretek cigarette smoke on the bronchial mucosal layer and bronchial smooth muscle layer in Sprague-Dawley rats

Bronchial lumen	Treatment groups			p value
	Group 1 (n=6)	Group 2 (n=6)	Group 3 (n=6)	
Δ mucosal perimeter (μm)	45.12 ± 1.74	72.78 ± 4.87	44.22 ± 3.18	0.000
mucosal area (μm ²)	1527.04 ± 77.30	1303.08 ± 68.02	1164.28 ± 30.20	0.000
Δ smooth muscle perimeter (μm)	26.30 ± 3.69	21.32 ± 5.72	35.49 ± 7.82	0.000
smooth muscle area (μm ²)	1092.52 ± 64.16	1473.33 ± 50.07	850.63 ± 78.88	0.000

Notes: Group 1 (control), rats breathe normal air without exposure to filtered kretek cigarette smoke. Group 2, the group of rats exposed to filtered kretek cigarette smoke at a dose of 1 stick/day for 30 days of treatment. Group 3, group of rats exposed to filtered kretek cigarette smoke at a dose of 2 sticks/day for 30 days of treatment. Mucosal area (μm²) = outer mucosal layer area (μm²) × inner mucosal layer area (μm²). “mucosal perimeter (μm)=outer mucosal perimeter (μm)×inner mucosal perimeter (μm)

(p=0.018); similarly it was shorter in group 1 than in group 3 (p=0.001), but in group 2 it was not significantly different from group 3 (p=0.170) (Table 4).

DISCUSSION

Exposure to filtered kretek cigarette smoke at a dose of 1 stick/day as well as 2 sticks/day for 30 days in this study did not affect the weight of the rat lungs. The results of this study are the same as the results of previous studies which demonstrated that the weight of the rat lungs did not differ between day 1 and day 90 of the kretek cigarette smoke inhalation period or between day 1 of treatment and day 42 of the post-inhalation period.⁽³⁸⁾

The rats in the treatment group demonstrated that they undergo bronchoconstriction. It is shown that the control rats had a greater bronchial lumen perimeter than the rats in groups 2 and 3; likewise, in group 2 the perimeter was greater than in group 3.

Based on the result of this study, it can be stated that cigarette smoke affects smooth muscle cell thickness, and causes dysplasia of the respiratory epithelial cells in the rat lungs. This fact is in accordance with the results of research which demonstrates that cigarette smoke influences smooth muscle cell thickness and induces dysregulation that affects function in the respiratory epithelial cells resulting in dysplasia.^(19,39)

Filtered kretek cigarette smoke at 1 stick/day and 2 sticks/day for 30 days of treatment affected the rat bronchial walls (Fig. 1; Fig. 2. A, B, C). This influence is clearly seen in the measurements of the bronchial mucosa, smooth muscle layer, and bronchial lumen. A deviation from the metabolic steady state leads to a condition of oxidative stress. The source of oxidative species can be endogenous or exogenous. A major exogenous source of these species is tobacco smoke. Oxidative damage can be induced in cells by chemical species contained

Table 4. Post hoc Tukey test of bronchial mucosa and bronchial smooth muscle layer in Sprague-Dawley rats

Bronchial lumen		p value
Δ mucosal perimeter (μm)	Group 1 vs Group 2	0.000
	vs Group 3	0.000
	Group 2 vs Group 3	0.000
mucosal area (μm ²)	Group 1 vs Group 2	0.000
	vs Group 3	0.763
	Group 2 vs Group 3	0.000
Δ smooth muscle perimeter (μm)	Group 1 vs Group 2	0.018
	vs Group 3	0.001
	Group 2 vs Group 3	0.170
smooth muscle area (μm ²)	Group 1 vs Group 2	0.000
	vs Group 3	0.000
	Group 2 vs Group 3	0.000

Notes: Group 1 (control), rats breathe normal air without exposure to filtered kretek cigarette smoke. Group 2, the group of rats exposed to filtered kretek cigarette smoke 1 stick/day for 30 days of treatment. Group 3, group of rats exposed to filtered kretek cigarette smoke 2 sticks/day for 30 days of treatment

in smoke through the generation of pro-inflammatory compounds and the modulation of intracellular pro-inflammatory pathways, resulting in a pathological condition.⁽⁴⁰⁾ More clearly it has been demonstrated that cigarette smoke induces lung inflammation by various mechanisms.^(41,42)

As a result of exposure to filtered kretek cigarette smoke, specifically the bronchial mucosa undergoes hyperplasia. A previous study demonstrated that exposure to cigarette smoke at a dose of 2 sticks/day for 14 days caused changes in epithelial structure in rat airways.⁽³³⁾ Our results are consistent with the results of studies showing that cigarette smoke increases lung epithelial cell activation and hyperplasia.⁽⁴³⁾ The bronchial epithelial structure of the rat affects the bronchial histometric measurements. We suggest that the occurrence of bronchoconstriction is primarily driven by smooth muscle cells. Bronchoconstriction is associated with bronchial hyperactivity, which in turn causes bronchial hyperplasia. Therefore as a result of exposure to filtered kretek cigarette smoke, the bronchial mucosa undergoes hyperplasia. This statement is in line with studies showing that growth of the smooth muscle layer of the airways is mediated by hypertrophy, and subsequent hyperplasia.⁽⁴⁴⁾ The results of other studies have also shown that cigarette smoke is associated with inflammation and hyperplasia of bronchial mucosal cells.⁽⁴⁵⁾

Our study demonstrated that exposure of the bronchial wall of rats to low doses of filtered kretek cigarette smoke at a dose of 1 stick/day as well as 2 sticks/day for 30 days, showed a noticeable accumulation of collagen in the bronchial wall, which is clearly visible in the smooth muscle layer (Fig. 2. D, E, and F). Related to the data in this study, it has been demonstrated that exposure to cigarette smoke twice daily, with one day off per week, for 90 days affects the proliferation and synthetic function of airway smooth muscle cells.⁽²¹⁾ This fact shows abnormal collagen deposition in the bronchial wall due to exposure to low-dose filtered kretek cigarette smoke. The appearance of bronchial collagen in

the rats of our study was evident through Masson's trichrome staining which was the stain of choice for visualizing bronchial collagen accumulation, as was done for visualizing collagen accumulation in murine lungs.^(44,45) The results of the present study show the dangers of low-dose filtered kretek cigarette smoke because it can result in collagen deposition in the bronchial walls. Although our study used low doses of filtered kretek cigarettes, the toxic substances that they contained were shown to cause the accumulation of bronchial collagen. The results of this study are in line with studies showing the accumulation of bronchial collagen in rats due to other toxic substances, namely sulphur mustard²⁹ and silica nanoparticles.⁽³¹⁾ Based on the results of this study, research is needed to prove on the molecular level that low-dose filtered kretek cigarette smoke, at doses of 1 stick/day or 2 sticks/day for 30 days has affected the genes that control collagen accumulation resulting in bronchial fibrosis in the rats. This is consistent with the results of research showing that exposure to cigarette smoke controls the gene expression of heat shock protein,⁽⁴⁵⁻⁴⁷⁾ collagen type I,⁽³¹⁾ collagen type III,^(31,48) DNA methylation and histone modifications.⁽⁴⁹⁾ In addition to cigarette smoke, fibrosis in the lung tissue of Sprague-Dawley rats can also be caused by exposure to bleomycin and lipopolysaccharide. In more detail it was shown that the peak of fibrosis due to exposure to bleomycin and lipopolysaccharide in these rats occurred on the 14th day.⁽⁵⁰⁾

The results of our study further reinforce the fact that exposure of rat lungs to low-dose filtered kretek cigarette smoke of 1 stick/day as well as 2 cigarette/day for 30 days causes bronchoconstriction. These results are similar to the treatment with high doses of toxic agents (ammonia) that cause bronchoconstriction in rats.⁽⁵¹⁾ In addition to bronchoconstriction, in rat lungs it has been demonstrated that short-term smoking increases the risk of insulin resistance in rats,⁽⁵²⁾ the subsequent increase in insulin acutely causing smooth muscle contraction.⁽⁵³⁾ The results of our study differ from studies on

the effects of high intensity interval training on adult rats, which increased the thickness of the bronchial epithelium and bronchial muscles.⁽⁵⁴⁾

The limitations of this study include the absence of measurement of the concentration of the substances in filter kretek cigarette smoke. However, the bronchoconstriction in this study was evidence of a clear reduction in area and perimeter of the bronchial lumen, and in areas of the bronchial mucosal layer and smooth muscle. This fact can be used as a warning to novice smokers and persons with low-dose smoking. Research is needed in humans on low-dose kretek smokers and novice kretek smokers. We know that novice kretek smokers usually take a low-dose as the start of their addiction to kretek cigarettes. Subsequent research should also be focused on histometric abnormalities in parts of the airways other than the bronchi, for example the trachea, bronchioles, respiratory bronchioles, and pulmonary alveoli.

CONCLUSION

Based on the research data, it can be concluded that exposure of male Sprague-Dawley rats to low-dose filtered kretek cigarette smoke of 1 stick/day as well as 2 sticks/day for 30 days does not affect the lung weight. In the Sprague-Dawley rats of the treatment group there apparently is hyperplasia of the bronchial mucosa, as well as bronchoconstriction, which is characterized by a reduction in the area and perimeter of the bronchial lumen and in the areas of the bronchial mucosa and smooth muscle layer. In the future, further research based on the results of this study should be focused on the effect of low-dose filtered kretek cigarette smoke on lung cell epigenetics.

CONFLICT OF INTERESTS

The authors declare that they have no competing interests.

FUNDING SOURCE

This publication is based on work supported by the Faculty of Medicine, Universitas Trisakti (no. 0458/PUF/FK/2022-2023.).

ACKNOWLEDGMENTS

We would like to thank the Heads and Staff of the Integrated Research and Testing Laboratory, Universitas Gadjah Mada, for the opportunity given to us so that this research could be carried out.

AUTHOR CONTRIBUTIONS

DV, EP, and HA: conceived and designed the experiments. DV, EP, HJE, RAD, and AVO: data collection, data analysis, and interpretation of the results. HJE, RAD, JJVT, and LG: image review and processing. DV, EP, HA, RAD, and AVO: writing of the manuscript. All authors have read and approved the final manuscript.

DATA AVAILABILITY STATEMENT

The data used to support the findings of this study is available from the corresponding author upon request.



REFERENCES

1. Roemer E, Dempsey R, Schorp MK. Toxicological assessment of kretek cigarettes Part 1: Background, assessment approach, and summary of findings. *Regul Toxicol Pharmacol* 2014;70 Suppl 1:S2-14. doi: 10.1016/j.yrtph.2014.11.015.
2. Cohen JE, Amalia B, Luo W, McWirther KJ, Masanga BC, Pankow JF Eugenol, menthol and other flavour chemicals in kreteks and 'white' cigarettes purchased in Indonesia. *Tob Control* 2023;0:1-4. doi:10.1136/tc-2022-057827.
3. World Health Organization. WHO report on the global tobacco epidemic 2021: addressing new and emerging products. Geneva: World Health Organization; 2021.

4. Braun M, Marsidi LL, Klingelhöfer D, et al. Kretek cigarettes and particulate matter emissions—an aerosol spectrometric study on typical Indonesian brands flavored with cloves. *Nicotine Tob Res* 2022;24:778–84. <https://doi.org/10.1093/ntr/ntab209>.
5. Nuryunarsih D, Lewis S, Langley T. Health risks of kretek cigarettes: a systematic review. *Nicotine Tob Res* 2021;23:1274–82. doi: 10.1093/ntr/ntab016.
6. Lin J, Taggart M, Borthwick L, et al. Acute cigarette smoke or extract exposure rapidly activates TRPA1-mediated calcium influx in primary human airway smooth muscle cells. *Sci Rep* 2021;11:9643. doi: 10.1038/s41598-021-89051-4.
7. Amorós-Pérez A, Cano-Casanova L, Román-Martínez MC, Lillo-Ródenas MA. Comparison of particulate matter emission and soluble matter collected from combustion cigarettes and heated tobacco products using a setup designed to simulate puffing regimes. *Chem Eng J Adv* 2021;8: 100144. <https://doi.org/10.1016/j.cej.2021.100144>.
8. Kuiper N, Coats EM, Crawford TN, et al. Trends in manufacturer-reported nicotine yields in cigarettes sold in the United States, 2013–2016. *Prev Chronic Dis* 2020;17:200205. DOI: <http://dx.doi.org/10.5888/pcd17.200205>.
9. Berthet A, Butty A, Rossier J, Sadowski IJ, Froidevaux P. ²¹⁰Po and ²¹⁰Pb content in the smoke of heated tobacco products versus conventional cigarette smoking. *Sci Rep* 2022;12:10314. doi: 10.1038/s41598-022-14200-2.
10. Paul AR, Khan F, Jain A, Saha SC. Deposition of smoke particles in human airways with realistic waveform. *Atmosphere* 2021;12:912. <https://doi.org/10.3390/atmos12070912>.
11. Lee YG, Lee PH, Choi SM, An MH, Jang AS. Effects of air pollutants on airway diseases. *Int J Environ Res Public Health* 2021;18:9905. doi: 10.3390/ijerph18189905.
12. Carvalho JL, Miranda M, Fialho AK, et al. Oral feeding with probiotic *Lactobacillus rhamnosus* attenuates cigarette smoke-induced COPD in C57Bl/6 mice: relevance to inflammatory markers in human bronchial epithelial cells. *PLoS One* 2020;15:e0225560. doi: 10.1371/journal.pone.0225560.
13. Fieldès M, Ahmed E, Bourguignon C, et al. Modélisation de l'épithélium bronchique dans la bronchopneumopathie chronique obstructive par les cellules souches pluripotentes induites humaines [Modelling the bronchial epithelium in chronic obstructive pulmonary disease using human induced pluripotential stem cells]. *Rev Mal Respir* 2020;37:197–200. French. doi: 10.1016/j.mr.2020.02.003.
14. Tulen CBM, Duistermaat E, Cremers JWJM, et al. Smoking-associated exposure of human primary bronchial epithelial cells to aldehydes: impact on molecular mechanisms controlling mitochondrial content and function. *Cells* 2022;11:3481. doi: 10.3390/cells11213481.32.
15. Chauhan NS, Sood D, Takkar P, Dhadwal DS, Kapila R. Quantitative assessment of airway and parenchymal components of chronic obstructive pulmonary disease using thin-section helical computed tomography. *Pol J Radiol* 2019;84:e54–e60. doi: 10.5114/pjr.2019.82737.
16. Park K, Jung Y, Son T, et al. Optimal diameter reduction ratio of acinar airways in human lungs. *PLoS One* 2019;14:e0204191. doi: 10.1371/journal.pone.0204191.
17. Huang Z, Sun S, Lee M, et al. Single-cell analysis of somatic mutations in human bronchial epithelial cells in relation to aging and smoking. *Nat Genet* 2022;54:492–8. doi: 10.1038/s41588-022-01035-w.
18. Morgan DI, Jokinen MP, Price HC, Gwinn WM, Palmer SM, Flakeet GP. Bronchial and bronchiolar fibrosis in rats exposed to 2,3-pentanedione vapors: implications for bronchiolitis obliterans in humans. *Toxicol Pathol* 2012;40:448–65. DOI: 10.1177/0192623311431946.
19. González-Luis GE, Westering-Kroon EV, Villamor-Martínez E, et al. Tobacco smoking during pregnancy is associated with increased risk of moderate/severe bronchopulmonary dysplasia: a systematic review and meta-analysis. *Front Pediatr* 2020;8:160. doi: 10.3389/fped.2020.00160.
20. Aboul-Fotouh GI, Zickri MB, Metwally HG, Ibrahim IR, Kamar SS, Sakr W. Therapeutic effect of adipose derived stem cells versus atorvastatin on amiodarone induced lung injury in male rat. *Int J Stem Cells* 2015;8:170–80. doi: 10.15283/ijsc.2015.8.2.170.
21. Lin X, Yang C, Huang L, et al. Upregulation of TRPM7 augments cell proliferation and interleukin-8 release in airway smooth muscle cells of rats exposed to cigarette smoke. *Mol Med Rep* 2016;13:4995–5004. doi: 10.3892/mmr.2016.5161
22. Wang Q, Cui Y, Wu X, Wang J. Evodiamine protects against airway remodelling and inflammation in asthmatic rats by modulating the HMGB1/NF- κ B/TLR-4 signalling pathway. *Pharm Biol* 2021;59:192–9. doi: 10.1080/13880209.2020.1871374.
23. Ferreira SRD, Pessoa RF, Figueiredo IAD, et al. Functional and morphologic dysfunctions in the airways of rats submitted to an experimental model of obesity-exacerbated asthma. *Sci Rep* 2022;12:9540. doi: 10.1038/s41598-022-13551-0.
24. Hiemstra PS, Grootaers G, van der Does AM, Krul CAM, Kooter IM. Human lung epithelial cell

- cultures for analysis of inhaled toxicants: Lessons learned and future directions. *Toxicol In Vitro* 2018;47:137–46. doi: 10.1016/j.tiv.2017.11.005.
25. Hiemstra PS, McCray PB, Bals R. The innate immune function of airway epithelial cells in inflammatory lung disease. *Eur Respir J* 2015;45:1150–62. doi: 10.1183/09031936.00141514.
 26. He W, Zhang W, Cheng C, et al. Expression characteristics of polymeric immunoglobulin receptor in Bactrian camel (*Camelus bactrianus*) lungs. *PLoS One* 2022;17:e0264815. doi: 10.1371/journal.pone.0264815.
 27. Liu N, Guan Y, Zhou C, Wang Y, Ma Z, Yao S. Pulmonary and systemic toxicity in a rat model of pulmonary alveolar proteinosis induced by indium-tin oxide nanoparticles. *Int J Nanomedicine* 2022;17:713–31. doi: 10.2147/IJN.S338955.
 28. Desdiani D, Rengganis I, Djauzi S, et al. Fibropreventive and antifibrotic effects of *Uncaria gambir* on rats with pulmonary fibrosis. *Evid Based Complement Alternat Med* 2022;2022:6721958. doi: 10.1155/2022/6721958.
 29. Malaviya R, Abramova EV, Rancourt RC, et al. Progressive lung injury, inflammation, and fibrosis in rats following inhalation of sulfur mustard. *Toxicol Sci* 2020;178:358–74. doi: 10.1093/toxsci/kfaa150.
 30. Attafi IM, Bakheet SA, Ahmad SF, et al. Lead nitrate induces inflammation and apoptosis in rat lungs through the activation of NF- κ B and AhR signaling pathways. *Environ Sci Pollut Res Int* 2022;29:64959–70. doi: 10.1007/s11356-022-19980-8. Erratum in: *Environ Sci Pollut Res Int*. 2022 May 21.
 31. Guan Y, Liu N, Yu Y, et al. Pathological comparison of rat pulmonary models induced by silica nanoparticles and indium-tin oxide nanoparticles. *Int J Nanomedicine* 2022;17:4277–92. <https://doi.org/10.2147/IJN.S380259>.
 32. Boon M, Verleden SE, Bosch B, et al. Morphometric analysis of explant lungs in cystic fibrosis. *Am J Respir Crit Care Med* 2016;193:516–26. DOI: 10.1164/rccm.201507-1281OC.
 33. Pulvers K, Tracy L, Novotny TE, et al. Switching people who smoke to unfiltered cigarettes: perceptions, addiction and behavioural effects in a cross-over randomised controlled trial. *Tob Control* 2023;32:520–3. doi: 10.1136/tobaccocontrol-2021-056815.
 34. Hidayah N, Rahayu O, Solfaine R, Utomo YS. Perbandingan paparan asap rokok konvensional dan rokok herbal pada mencit (*Mus musculus*) terhadap perbandingan gambaran histologi paru. *J Vitek Bid Ked Hewan* 2020;10:25–32. DOI <https://doi.org/10.30742/jv.v10i0.55>.
 35. Tjahyadi D, Parwanto E. Applications of biometrics, histometrics and cytometrics in deep learning. *Bali Med J* 2022;11:520–2. DOI: 10.15562/bmj.v11i1.3265
 36. Drian A, Yee A, Kim N, et al. Histometric measurement of CD117 and PGP9.5 immunopositive staining in excised vestibular specimens from patients with neuroproliferative vestibulodynia. *J Sex Med* 2023;20Suppl 1:qdad060.127. <https://doi.org/10.1093/jsxmed/qdad060.127>.
 37. Arifin WN, Zahiruddin WM. Sample size calculation in animal studies using resource equation approach. *Malays J Med Sci*. 2017;24:101–5. <https://doi.org/10.21315/mjms2017.24.5.11>.
 38. Schramke H, Roemer E, Dempsey R, et al. Toxicological assessment of kretek cigarettes. Part 7: The impact of ingredients added to kretek cigarettes on inhalation toxicity. *Reg Toxicol Pharmacol* 2014;70 Suppl 1:S81–9. doi: 10.1016/j.yrtph.2014.09.014.
 39. Chou HC, Li YT, Chen CM. Human mesenchymal stem cells attenuate experimental bronchopulmonary dysplasia induced by perinatal inflammation and hyperoxia. *Am J Transl Res* 2016;8:342–53.
 40. Emma R, Caruso M, Campagna D, Pulvirenti R, Li Volti G. The impact of tobacco cigarettes, vaping products and tobacco heating products on oxidative stress. *Antioxidants* 2022;11:1829. doi: 10.3390/antiox11091829.
 41. Wu T, Xu K, Liu C, Li Y, Li M. Interleukin-37 ameliorates cigarette smoke-induced lung inflammation in mice. *Biomed Pharmacother* 2022;155:113684. <https://doi.org/10.1016/j.biopha.2022.113684>.
 42. Zhang W, Zhang Y, Zhu Q. Cigarette smoke extract-mediated FABP4 upregulation suppresses viability and induces apoptosis, inflammation and oxidative stress of bronchial epithelial cells by activating p38 MAPK/MK2 signaling pathway. *J Inflamm (Lond)* 2022;19:1–11. doi: 10.1186/s12950-022-00304-z.
 43. Murray LA, Dunmore R, Camelo, et al. Acute cigarette smoke exposure activates apoptotic and inflammatory programs but a second stimulus is required to induce epithelial to mesenchymal transition in COPD epithelium. *Respir Res* 2017;18:82.. <https://doi.org/10.1186/s12931-017-0565-2>.
 44. Wang KCW, Donovan GM, Saglani S, et al. Growth of the airway smooth muscle layer from late gestation to childhood is mediated initially by hypertrophy and subsequently hyperplasia.

- Respirology 2022;27:493-500. DOI: 10.1111/resp.14240.
45. Manevski M, Devadoss D, Long C, et al. Increased expression of LASI lncRNA regulates the cigarette smoke and COPD associated airway inflammation and mucous cell hyperplasia. *Front Immunol* 2022;13:803362. doi: 10.3389/fimmu.2022.803362.
 46. Han JM, Kim MH, Choi LY, Kim G, Yang WM. Exploring the potential effects and mechanisms of *Asarum sieboldii* radix essential oil for treatment of asthma. *Pharmaceutics* 2022;14:558. <https://doi.org/10.3390/pharmaceutics14030558>.
 47. Zhang X, Zhang X, Huang W, Ge X. The role of heat shock proteins in the regulation of fibrotic diseases. *Biomed Pharmacother* 2021;135:111067. <https://doi.org/10.1016/j.biopha.2020.111067>.
 48. Hesse C, Beneke V, Konzok S, et al. Nintedanib modulates type III collagen turnover in viable precision-cut lung slices from bleomycin-treated rats and patients with pulmonary fibrosis. *Respir Res* 2022;23:201. <https://doi.org/10.1186/s12931-022-02116-4>.
 49. Li X, Feng C, Peng S. Epigenetics alternation in lung fibrosis and lung cancer. *Front Cell Dev Biol* 2022;10:1060201. doi: 10.3389/fcell.2022.1060201.
 50. Kurniawan SV, Louisa M, Zaini J, et al. Acute exacerbation of idiopathic pulmonary fibrosis model in the rats using bleomycin and lipopolysaccharides. *J Adv Vet Anim Res* 2023;10:196–204. <http://doi.org/10.5455/javar.2023.j669>.
 51. Ågren L, Elfsmark L, Akfur C, Jonasson S. High concentrations of ammonia induced cytotoxicity and bronchoconstriction in a precision-cut lung slices rat model. *Toxicol Lett*. 2021;349:51-60. doi: 10.1016/j.toxlet.2021.06.001.
 52. Cho SH, Jeong SH, Shin J, Park S, Jang SI. Short-term smoking increases the risk of insulin resistance. *Sci Rep* 2022;12:3550. <https://doi.org/10.1038/s41598-022-07626-1>.
 53. Proskocil BJ, Calco GN, Nie Z. Insulin acutely increases agonist-induced airway smooth muscle contraction in humans and rats. *Am J Physiol Lung Cell Mol Physiol* 2021;320: L545–56. doi:10.1152/ajplung.00232.2020.
 54. Arabzadeh E, Mirdar S, Moradiani H. *Nigella sativa* supplementation attenuates exercise-induced bronchoconstriction in the maturing rat: a histometric and histologic study. *Comp Clin Pathol* 2016;25:1–5. DOI 10.1007/s00580-015-2128-6.