

Absence of Paragonimus DNA and Eggs in Tuberculosis Patients in Indonesia: Implications for Surveillance and Public Health Awareness

by Turnitin.libraryfk

Submission date: 15-Jun-2026 12:23PM (UTC+0700)

Submission ID: 2696798879

File name: Manuscript_IRJMS_08660_WS.pdf (511.64K)

Word count: 5836

Character count: 34922

Absence of *Paragonimus* DNA and Eggs in Tuberculosis Patients in Indonesia: Implications for Surveillance and Public Health Awareness

Machrumnizar^{1*}, Suriyani Tan¹, Yuliana¹, Rina Kurniasri Kusumaratna²

¹Department of Parasitology, Faculty of Medicine, Universitas Trisakti, Indonesia, ²Department of Public Health, Faculty of Medicine, Universitas Trisakti, Indonesia. *Corresponding Author's Email: machrumnizar_md@trisakti.ac.id

Abstract

Paragonimus spp. are zoonotic trematodes endemic in several Asian countries, often mimicking pulmonary tuberculosis (TB) due to overlapping clinical manifestations. Although Indonesia's geographical proximity to endemic countries and shared culinary practices may increase exposure risk, human paragonimiasis has not been reported since a 1963 case in a Sumatran tiger. This study represents the first molecular screening for human paragonimiasis in Indonesia, aiming to investigate *Paragonimus* DNA and eggs in sputum samples of pulmonary TB patients. This study addresses infectious disease epidemiology and prevention through molecular surveillance. A cross-sectional study was conducted involving 60 sputum samples from TB patients in South Jakarta. Microscopy examination using Ziehl-Neelsen staining and the NaOH concentration method confirmed *Mycobacterium tuberculosis* in all samples, with no *Paragonimus* eggs observed. DNA extracted was performed using a commercial kit and DNA quality was assessed via agarose gel electrophoresis. Positive and negative controls were included to verify assay performance. None of the clinical DNA extracts showed visible *Paragonimus*-specific bands (~221 bp), and therefore PCR amplification was not performed. Although *Paragonimus* was not detected, this does not definitely exclude its presence. Using the zero-case prevalence concept with a 95% confidence level, the findings suggest a prevalence of less than one percent in the study population. Our findings underscore the importance of maintaining diagnostic vigilance for neglected parasitic infections in Indonesia, provide evidence to guide prevention strategies, enhance epidemiological monitoring for zoonotic diseases in TB-endemic areas, supporting the urgency of updating national parasitological surveillance policies and strengthening One Health-based disease monitoring.

Keywords: Molecular, Neglected Tropical Disease, One Health Paragonimiasis, Tuberculosis.

Introduction

Foodborne zoonotic parasites remain a significant public health challenge in many developing countries, particularly in Southeast Asia (1). Changing consumption patterns, increased human mobility, and intensified interactions between humans, animals, and the environment contribute to the emergence and persistence of various often-neglected parasitic diseases. One group of parasites included in this category is the pulmonary trematode of the genus *Paragonimus*, which has received less attention globally than other infectious diseases with similar respiratory manifestations (2). *Paragonimus* infections can cause chronic morbidity, reduce quality of life, and burden the health system due to misdiagnosis and mismanagement (3).

Paragonimus spp., also known as lung flukes, are foodborne trematodes transmitted to humans through the ingestion of raw or undercooked

freshwater crustaceans. These parasites cause paragonimiasis, a zoonotic infection (2, 3). The manifestations include chronic cough, hemoptysis, and radiographic abnormalities, which often resemble pulmonary tuberculosis (TB). These similarities lead to frequent diagnostic misclassification in endemic regions where both infections co-occur. Human cases of paragonimiasis have been widely reported in several countries across East and Southeast Asia, including China, the Philippines, Thailand, South Korea, and Vietnam (4, 5).

Several epidemiological and clinical studies in these countries have shown that paragonimiasis is frequently found in populations with traditional dietary habits based on raw or undercooked freshwater crabs or shrimp (6). Paragonimiasis confirmed TB patients in Indonesia, an approach has been found in various reports to be an impor-

This is an Open Access article distributed under the terms of the Creative Commons Attribution CC BY license (<http://creativecommons.org/licenses/by/4.0/>), which permits unrestricted reuse, distribution, and reproduction in any medium, provided the original work is properly cited.

(Received 15th October 2025; Accepted 10th January 2026; Published 28th January 2026)

tant cause of chronic cough and hemoptysis in patients initially suspected of pulmonary tuberculosis (7-9). This confirms that the clinical and radiological similarities between paragonimiasis and TB are not merely theoretical phenomena, but rather a real clinical problem with broad diagnostic and therapeutic implications.

Despite sharing cultural, environmental, and ecological conditions and geographical proximity with these endemic countries, Indonesia has not reported a human case of paragonimiasis in modern literature. The last known case was in 1963, involving a Sumatran tiger (*Panthera tigris sumatrae*) (10, 11). Since then, there has been no further surveillance or clinical detection of the parasite in humans. This prolonged absence of documentation raises two possibilities: either *Paragonimus* is indeed absent, or it simply underdiagnosed due to limited clinical awareness and diagnostic capacity.

This situation raises important questions from an epidemiological and public health perspective. Indonesia boasts high biodiversity, extensive freshwater ecosystems, and dietary habits that, in some communities, involve raw or undercooked food. Furthermore, population mobility within and between regions and countries in Southeast Asia is increasing, opening up opportunities for the introduction and spread of parasites across borders (12, 13). The absence of reported human cases for over six decades may reflect successful natural elimination, but it also likely indicates systemic underdiagnosis due to low clinical awareness and limited specific diagnostic facilities. To date, there is a clear lack of contemporary molecular evidence assessing the presence of *Paragonimus* spp. in human populations in Indonesia, particularly among patients with pulmonary tuberculosis, a group in which clinical overlap may obscure parasitic infections. In endemic settings, the well-documented similarity in clinical presentation between paragonimiasis and TB has made TB-related clinical pathways a practical entry point for identifying previously unrecognized cases of paragonimiasis. Indeed, in several countries, paragonimiasis has been detected among patients initially evaluated for suspected TB, highlighting the usefulness of TB programs as a bridge for human case detection (4, 14).

Importantly, the rationale for focusing on pulmonary TB patients in this study is not to demonstrate or quantify misdiagnosis of paragonimiasis as tuberculosis at the individual level. Rather, TB is used as a pragmatic epidemiological entry point for human surveillance. Furthermore, Indonesia continues to report a substantial number of suspected TB cases that remain bacteriologically unconfirmed, undiagnosed, or unreported within routine surveillance systems. In this context, it is reasonable to hypothesize that a small proportion of these unresolved or presumptive TB cases may represent alternative respiratory diseases with similar clinical presentations, including parasitic infections such as paragonimiasis. Within this broader epidemiological context of unresolved TB suspicion, focusing on bacteriologically confirmed TB patients provides a defined and analytically robust population for exploratory molecular screening.

This study therefore adopts an exploratory approach, using bacteriologically confirmed TB patients as an accessible and clinically relevant population to assess the possible presence of *Paragonimus* spp. in humans, rather than to reclassify or challenge existing TB diagnoses. Addressing this gap, the present study represents the first molecular screening for human paragonimiasis conducted among bacteriologically confirmed pulmonary TB patients in Indonesia. By applying both conventional microscopic examination and molecular detection methods to sputum samples from a high TB-burden urban population in Jakarta, the study generates baseline molecular and epidemiological data that may inform future surveillance strategies, refine diagnostic priorities, and support evidence-based decision-making within national TB control and zoonotic disease monitoring programs.

The primary objective of this study was to assess the potential presence of *Paragonimus* spp. in bacteriologically confirmed pulmonary tuberculosis patients in Indonesia using both conventional microscopic and a molecular approach. The study specifically focused on confirmed TB cases to assess the possibility of *Paragonimus* co-infection within a high TB-burden population, rather than exploring potential misdiagnosis. The novelty of this study lies in the first application of molecular screening for paragonimiasis in a population of

that has not been previously reported. By integrating a zoonotic disease perspective into the context of the national TB program, this study addresses a significant knowledge gap and highlights the need for a more comprehensive diagnostic approach to chronic respiratory diseases in high TB-burden settings.

Methodology

Study Design and Setting

This cross-sectional descriptive study was conducted between February 2023 and July 2024 at four sub-district public health centers in South Jakarta: Pasar Minggu, Tebet, Cilandak, and Pesanggrahan. These sites were selected based on previous reports indicating high TB case notification as reported in the National Tuberculosis Information System (SITB).

Study Population and Sample Size

Participants were selected using simple random sampling from a total of 3,195 smear-positive pulmonary TB patients registered at the four community health centers. The minimum required sample size (calculated using *Statistics and Sample*® software; 95% confidence level; 10% margin of error) was 256. However, only 60 participants provided sputum specimens of sufficient volume for DNA extraction and molecular analysis, as illustrated in Figure 1, which summarizes the overall methodological workflow including participant selection, laboratory screening, and prevalence estimation. Figure 1 summarizes the sequential steps from random sampling of pulmonary TB patients to laboratory screening and prevalence estimation for *Paragonimus* infection.

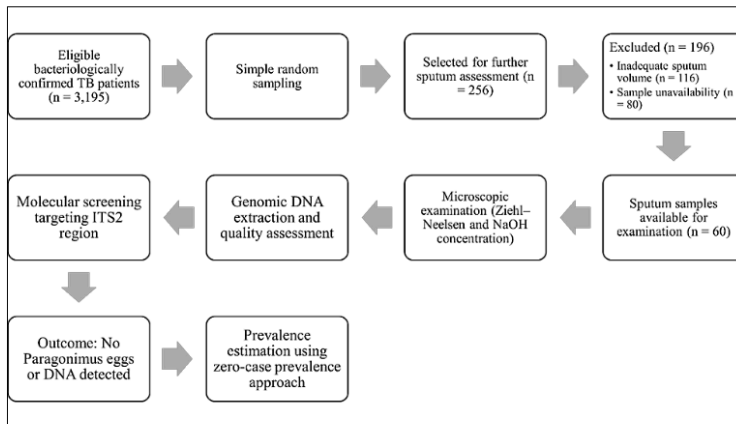


Figure 1: Flowchart of Participant Selection and Analytical Procedures

Inclusion criteria: Age 5–65 years, bacteriologically confirmed pulmonary TB (Ziehl-Neelsen positive), and no anti-TB or antiparasitic treatment in the past six months. **Exclusion criteria** included extrapulmonary TB, human immunodeficiency virus (HIV) coinfection, or inability to produce adequate sputum.

Sample Collection and Laboratory Processing

Participants submitted two early-morning sputum samples in sterile and wide-mouth containers. Samples were labeled and transported under cold

chain to the biomolecular laboratory at Universitas Trisakti.

Microscopic Examination

All sputum specimens were first screened using Ziehl-Neelsen staining to reconfirm TB diagnosis. The NaOH concentration technique was applied to concentrate the samples for helminth eggs detection. Smears were examined under light microscopy at 100× and 400× magnification by two independent parasitologists blinded to PCR results. Any suspected *Paragonimus* egg was documented and re-evaluated under high magnification (1000×) with oil immersion.

DNA Extraction and Gel Electrophoresis

Genomic DNA was extracted from all 60 sputum samples using the QIAamp DNA Mini Kit (Qiagen, Hilden, Germany) following the manufacturer's protocol, with minor modifications to optimize yield from mucous-rich specimens. Briefly, 1.5 ml of sputum was examined with 1.5 ml of a mucolytic solution containing 2% sodium hydroxide, 1.45% trisodium citrate, and 0.5% N-acetyl L-cysteine. The mixture was vortexed and incubated at room temperature for 15 minutes, then diluted to a total volume of 50 ml with 1× phosphate-buffered saline (PBS) and centrifuged at 3000 rpm for 20 minutes. The supernatant was discarded, and the pellet was re-suspended in 200 µl PBS, followed by heat treatment at 99 °C for 20 minutes.

DNA concentration and purity were measured using NanoDrop spectrophotometry (Thermo Scientific, USA). Extracted DNA was stored at -20°C until analysis. DNA quality was first assessed by agarose gel electrophoresis (1.5% agarose in 1× TBE buffer, stained with ethidium bromide) and visualized under UV illumination to confirm total DNA integrity. A 100 bp DNA ladder was used as a molecular size marker. The positive control used in this assay was derived from *Paragonimus westermani* adult tissue maintained in the reference collection of the Molecular Parasitology Laboratory, Universitas Trisakti. A no-template negative control was included in all reactions to monitor potential contamination. The expected ~221 bp amplicon corresponds to the internal transcribed spacer 2 (ITS2) region of *Paragonimus* spp., which has been previously validated (4, 7). This fragment size represents the specific PCR product, not the total extracted DNA visualized prior to amplification. Therefore, at this stage, gel electrophoresis was used only to verify the presence and integrity of total genomic DNA, not to identify *Paragonimus*-specific fragments. Validated ITS2 primers [Forward: 5'-GGTACCGGTGGATCACTCGGCTCGTG-3' Reverse: 5'-GGGATCCTGGTTAGTTTCTTTCTCCGC-3'] were available; however, PCR amplification was planned as a subsequent analytical step following

DNA quality verification. As no *Paragonimus*-specific DNA signals were observed during the preliminary molecular screening stage, further amplification was not pursued.

Analytical Framework

The study followed a predefined stepwise analytical framework to identify potential *Paragonimus* infection among pulmonary TB patients. Following participant selection and sputum collection, all samples underwent microscopic examination and genomic DNA extraction. Molecular screening targeting the ITS2 region was planned as the final analytical step and was contingent upon meeting DNA integrity and quality criteria. In the absence of detectable *Paragonimus* signals by microscopy or molecular screening, prevalence estimation was performed using a zero-case prevalence approach to ensure appropriate epidemiological interpretation.

Data Analysis

The data collected were coded and entered into Microsoft Excel, then analyzed using SPSS software version 25.0 (IBM Corp., Armonk, NY, USA). Descriptive statistics were used to summarize patients' demographics and diagnostic outcomes. Results were expressed as frequencies and percentages. Paragonimiasis prevalence was calculated only if positive cases were identified.

Results

Distribution of Tuberculosis-Positive Cases

During the study period, a total of 3,195 bacteriologically confirmed pulmonary tuberculosis (TB) cases were recorded across four sub-district community health centers in South Jakarta: Pasar Minggu, Tebet, Cilandak, and Pesanggrahan, as summarized in Table 1. The highest proportion of cases occurred in Pasar Minggu (37.8%), followed by Cilandak (31.0%), Tebet (19.2%), and Pesanggrahan. This distribution provides the epidemiological basis for selecting these sites as representative areas for *Paragonimus* screening among confirmed TB patients.

Table 1: Demographic Distribution of Tuberculosis-Positive Patients by Sub-District Health Centers in South Jakarta (N = 3,195)

Characteristics	Community Health Center				Total n (%)
	Pasar Minggu n (%)	Tebet n (%)	Gilandak n (%)	Pesanggrahan n (%)	
Total TB cases	1209 (37.84)	612 (19.15)	991 (31.02)	383 (11.99)	3195 (100.0)
Sex					
Male	918 (75.93)	364 (59.48)	624 (62.97)	211 (55.09)	2117 (66.26)
Female	291 (24.07)	248 (40.52)	367 (37.03)	172 (44.91)	1078 (33.74)
Age group (years)					
0-4	73 (6.04)	36 (5.88)	118 (11.91)	23 (6.01)	250 (7.82)
5-14	122 (10.09)	134 (21.89)	149 (15.04)	17 (4.44)	422 (13.21)
15-30	217 (17.95)	152 (24.84)	205 (20.69)	128 (33.42)	702 (21.97)
31-45	429 (35.48)	248 (40.52)	360 (36.33)	58 (15.14)	1095 (34.27)
46-60	332 (27.46)	42 (6.86)	138 (13.93)	130 (33.94)	642 (20.09)
>60	36 (2.98)	0 (0)	21 (2.12)	27 (7.05)	84 (2.63)

Note: Data are presented as the number and percentage of TB-positive patients within each subdistrict community health center

Microscopic examination of all 60 sputum samples showed no *Paragonimus* eggs. None of the DNA extracts demonstrated detectable amplifiable DNA suitable for PCR amplification. Therefore, PCR testing for *Paragonimus*-specific ITS2 fragments was not performed on clinical samples. Positive and negative controls were run in parallel to validate assay performance.

Gender and Age Profile

The overall gender distribution showed a predominance of male patients (n = 2,117; 66.26%), with a male-to-female ratio of approximately 2:1. This ratio is consistent with national TB surveillance data and aligns with global trends indicating higher TB incidence among men, possibly due to occupational exposure, smoking, and delayed healthcare-seeking behavior.

In terms of age distribution, the highest burden of TB was found in adults aged 31–45 years (n = 1,095; 34.27%), followed by those aged 46–60 years (n = 642; 20.09%) and 15–30 years (n = 702; 21.97%). This trend was consistent across all CHCs, with Pasar Minggu and Cilandak recording particularly high TB burdens among adults aged 31–45 (35.48% and 36.33%, respectively). Pesanggrahan presented a unique distribution, with a substantial proportion of TB cases observed in the 46–60 age group (33.94%). The pediatric population, though less frequent, was not negligible: 672 cases (21.03%) occurred in children under 15 years of age, with the 5–14 age group (n = 422; 13.21%) showing higher case numbers than the 0–4 age group (n = 250; 7.82%).

Microscopic Detection for *Paragonimus spp.* Ova

Despite the clinical suspicion of potential misdiagnosis between TB and paragonimiasis, no *Paragonimus* eggs were detected in a total of 60 sputum specimens that were examined using two conventional methods. The specificity of the NaOH concentration technique in detecting the absence of *Paragonimus* ova was found to be 100% (95% CI: 98.90% to 100%), as confirmed by comparison with the Ziehl-Neelsen staining technique. Images of sputum slides prepared with the NaOH concentration technique and ZNS staining are shown in Figures 2A and 2B, respectively. The absence of egg detection may reflect either the true absence of *Paragonimus* infection in this population or limitations of conventional microscopy, especially in cases of light infections, intermittent egg shedding, or chronic lesions.

Detection of *Paragonimus* DNA by PCR

In this study, DNA extracted from all 60 sputum samples showed no visible amplifiable *Paragonimus*-specific bands when assessed by agarose gel electrophoresis, indicating very low DNA concentration and quality insufficient for PCR amplification. Therefore, PCR testing was not performed on clinical samples. NanoDrop spectrophotometry confirmed the low yield, with absorbance values below the reliable quantification range (<5 ng/μL) and inconsistent A260/A280 ratios.

As shown in Figure 3, the positive control displayed a distinct 221 bp band, while Lanes 3–5 (clinical sputum samples) showed no visible amplification products, confirming the absence of amplifiable *Paragonimus* DNA in all tested specimens.

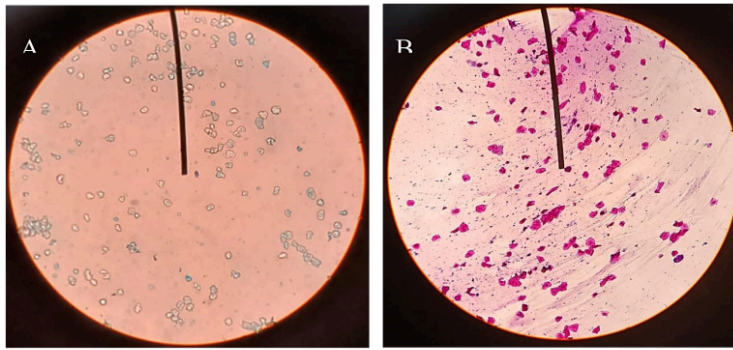


Figure 2: Microscopic Examination of Sputum Demonstrating *Mycobacterium Tuberculosis* Bacilli (Red Rods) and Absence of *Paragonimus* Eggs Using Two Different Techniques at 1000× Magnification (Oil Immersion) (A) Smear Prepared Using the NaOH Concentration Technique (B) Ziehl-Neelsen-Stained Smear



Figure 3. Gel Electrophoresis of Extracted DNA from Sputum Samples. Lane M: 100 Bp DNA Ladder; Lane 1: Negative Control; Lane 2: Positive Control DNA from *Paragonimus westermani*; Lanes 3–5: Clinical Sputum Samples with No Visible *Paragonimus*-Specific Amplification Bands

Discussion

This study explored the potential co-existence of paragonimiasis among bacteriologically confirmed TB patients in South Jakarta. Despite longstanding epidemiological concerns regarding the potential co-infection or clinical overlap between paragonimiasis and TB in endemic areas, our findings revealed no evidence of *Paragonimus* infection. Neither helminth eggs were detected microscopically nor *Paragonimus*-specific DNA

identified through molecular analysis targeting the ITS2 region. These findings underscore the significant burden of TB among economically productive adults, reflecting its dual impact on public health and socioeconomic stability. In addition, the notable proportion of pediatric cases highlights the need for strengthened early detection, contact tracing, and screening programs

in household settings to prevent underdiagnosis and disease progression.

The molecular findings further support the absence of *Paragonimus* infection among bacteriologically confirmed TB patients in this study. Based on the zero-case prevalence concept at a 95% confidence level, the absence of detectable *Paragonimus* DNA suggests that the prevalence in this population is below one percent (15). This aligns with the epidemiological context of urban Jakarta, where *Paragonimus* transmission is unlikely due to modernized food practices and limited exposure to freshwater crustacean hosts. These results indicate that the lack of amplification was not a technical failure, as internal positive and negative controls confirmed assay validity, but rather reflect a true absence of *Paragonimus* infection in the sampled population. Nevertheless, the findings highlight the need for continued surveillance in rural or high-risk areas where traditional consumption of undercooked crabs or crayfish persists.

The absence of detectable *Paragonimus* should not be dismissed as inconsequential. The lack of ova in all samples supports the hypothesis that *Paragonimus* is not currently endemic in the area under study. Microscopy using ZNS and NaOH concentration techniques demonstrated high specificity and may continue to serve as a supportive diagnostic tool for differentiating TB from paragonimiasis, especially in endemic regions (4, 16). However, these methods may have limited sensitivity in low-burden settings. This brings substantial epidemiological and clinical significance in the context of evolving disease landscapes and diagnostic practices in tropical medicine. The absence of amplifiable DNA, as confirmed by RNaseP amplification failure, indicates possible challenges in sputum-based molecular diagnostics due to DNA degradation or the presence of inhibitors (17, 18). The limitation underscores the importance of optimizing DNA extraction protocols, particularly for detecting foodborne parasites such as *Paragonimus*.

Our findings provide empirical evidence that the prevalence of pulmonary paragonimiasis among TB-confirmed individuals in urban Jakarta is likely negligible or has markedly declined, challenging previous assumptions of co-endemicity that may have been based on outdated, unreliable, or unverified data. Although our results align with

historical records showing the absence of paragonimiasis reporting in Indonesia since 1963 was observed, the potential for re-emergence remains, given increasing seafood imports, travel, and diversification of food culture in the country (10, 11). In settings where paragonimiasis remains endemic, misdiagnosis of pulmonary paragonimiasis as TB may still occur; however, among confirmed TB cases such as ours, the concern shifts toward potential co-infection rather than diagnostic confusion (19).

The clinical overlap between paragonimiasis and TB has been extensively documented. Both conditions may present chronic cough, hemoptysis, pleuritic chest pain, and radiological findings such as cavitary or nodular lesions (19, 20). In resource-limited settings, these overlapping features have historically led to empirical anti-TB therapy in cases where parasitic infections were the actual cause. Studies conducted in Peru, Ecuador, and the Philippines reported that up to 20% of suspected TB patients were eventually diagnosed with paragonimiasis (16, 21). However, those studies were carried out in rural or highland areas with well-documented *Paragonimus* transmission linked to traditional dietary habits such as the consumption of undercooked freshwater crabs or crayfish.

Our study setting in urban Jakarta represents a contrasting environment. Over the past two decades, urbanization, improved food safety awareness, and changing dietary habits have likely contributed to the suppression of *Paragonimus* transmission. Additionally, the absence of *Paragonimus*-specific DNA in our samples, despite employing sensitive molecular assays, supports the notion that urban TB patients are currently not at significant risk for paragonimiasis, even in a country historically regarded as endemic. This finding aligns with recent parasitological mapping efforts in Indonesia, which have reported no active *Paragonimus* foci in recent years (22).

From a methodological standpoint, the strength of our study lies in its dual-layered diagnostic approach, integrating microscopy and DNA-based methods. Conventional microscopy remains valuable and cost-effective but suffers from low sensitivity, particularly when egg output is sparse or intermittent (4, 16). Molecular diagnostics targeting the ITS2 region of *Paragonimus* spp. offer a more reliable alternative with high specificity,

even in pauciparasitic infections (23). The absence of amplifiable *Paragonimus*-specific DNA, therefore, is not a reflection of technical failure but a valid representation of the lack of infection, reinforced by the use of internal controls and reference assays confirming methodological reliability.

Publishing negative or null findings remains an underappreciated yet essential scientific practice (24). Such evidence corrects biased assumptions, prevents redundant investigations, and informs policymakers and clinicians about evolving patterns of disease distribution (25, 26). In our context, it alerts healthcare professionals that routine suspicion of paragonimiasis in urban TB cases—without relevant exposure history or clinical indicators—may no longer be justified. This can optimize diagnostic workflows, reduce empirical antiparasitic treatments, and ensure better allocation resources toward condition with active transmission. Rather than maintaining the status quo, these findings provide evidence-based guidance for rational testing strategies—prioritizing *Paragonimus* screening only in populations or regions with known dietary or ecological risk factors.

This study has several limitations that should be acknowledged. First, sampling was limited to bacteriologically confirmed pulmonary TB patients from an urban population, which may not adequately represent rural or highland communities where *Paragonimus* transmission is more likely. Second, the low yield and variable quality of DNA extracted from sputum specimens could have reduced molecular detection sensitivity. However, the inclusion of internal positive and negative controls verified assay validity, indicating that the absence of amplification was unlikely to be due to technical failure. Finally, the modest sample size may limit the statistical power and the generalizability of the findings beyond the study population.

Lastly, our findings highlight the epidemiological heterogeneity of paragonimiasis and the importance of interpreting historical reports within contemporary contexts. Parasitic infections often exhibit highly focal distributions influenced by ecological and cultural factors, even within countries considered endemic (12, 27). As a result, broad assumptions of co-endemicity may lead to misinterpretation of diagnostic priorities and

disease risk (7, 28). The absence of *Paragonimus* spp. in the present study area, despite historical records, illustrates how localized transmission patterns and temporal changes may limit the applicability of older literature.

Implications and Recommendations

Based on the current findings, routine screening for paragonimiasis among urban pulmonary TB patients may not be necessary in low-prevalence settings. However, a targeted diagnostic approach is recommended for patients with atypical clinical features, poor response to anti-tuberculosis treatment, or relevant dietary and environmental exposure histories. Integration of risk-based molecular surveillance into existing TB laboratory networks may enhance early detection of neglected zoonotic infections without imposing unnecessary diagnostic burden. Future research should prioritize high-risk populations, rural or endemic-adjacent regions, and alternative clinical specimens to refine prevalence estimates and inform evidence-based surveillance strategies in Indonesia.

Conclusion

This study presents the first molecular screening for human paragonimiasis among bacteriologically confirmed pulmonary tuberculosis patients in an urban setting in Indonesia. The absence of *Paragonimus* spp. eggs and DNA in sputum samples indicates a minimal risk of paragonimiasis co-infection in the Jakarta study population during the study period. These findings provide contemporary molecular evidence to refine diagnostic priorities, support a targeted risk-based surveillance approach rather than routine screening in urban TB settings, and inform prevention strategies and epidemiological monitoring for neglected zoonotic infections within TB-endemic areas. Molecular diagnostics remain reliable tools for surveillance and should be integrated into broader One Health initiatives; however, these conclusions should be interpreted in light of limitations related to urban-only sampling, modest sample size, and constraints of sputum-based molecular detection. Future research should expand surveillance to rural and highland communities with traditional dietary practices and incorporate environmental and intermediate host sampling to more

comprehensively assess *Paragonimus* transmission risk in Indonesia.

Abbreviations

DNA: Deoxyribonucleic acid, PCR: Polymerase Chain Reaction, SITB: Sistem Informasi Tuberculosis (the National Tuberculosis Information System), TB: Tuberculosis, ZNS: Ziehl Neelsen-staining.

Acknowledgment

We express our sincere gratitude to the heads and staff of the participating sub-district health centers in South Jakarta for their support in sputum sample collection and patient coordination. We also thank the Molecular Laboratory of the Faculty of Medicine, Universitas Trisakti, for their technical assistance in PCR procedures.

Author Contributions

Machrumnizar: conceptualization, methodology, software, validation, funding acquisition, investigation, resources, data curation, original draft writing, review writing, editing, Suriyani Tan: validation, formal analysis, resources, data curation, review writing, editing, visualization, Yuliana: project administration, data collection, field coordinator, proofreading, Rina Kurniasri Kusumaratna: supervision, resources, project administration. All authors have read and approved the final manuscript.

Conflict of Interest

The authors state that the study was performed without any commercial or financial ties that may be seen as a possible conflict of interest during the study.

Declaration of Artificial Intelligence (AI) Assistance

This manuscript was prepared using generative artificial intelligence (AI) tools, specifically Grammarly and QuillBot, for language editing, paraphrasing, and enhancement of academic writing style. These technologies facilitated the establishment of coherent sentence structures, grammatical precision, and tense consistency throughout the document. The intellectual content, critical analysis, data interpretation, reference selection, and final conclusions in this manuscript were exclusively conceptualized, reviewed, and validated by the authors. No AI technology was employed to produce, analyze, or interpret

scientific data, nor to execute any study assignments beyond language support. The authors are completely responsible for the manuscript's originality and accuracy and have ensured that the use of AI-assisted technology follows ethical norms and publication rules.

Ethics Approval

The study involving human participants was reviewed and approved by the Research Ethics Committee of Faculty of Medicine, Universitas Trisakti (Approval No. 056/KEWFK/III2023), and conducted according to the guidelines of the Declaration of Helsinki. Written informed consent to participate in this study was obtained from all participants or their legal guardians.

Funding

This research was funded through the Grant Scheme 2023 from the Research and Community Service Institute, Universitas Trisakti, Indonesia (Grant No. 079/A.1/LPPM-P/USAKTI/X/2023).

References

- Subedi D, Paudel M, Poudel S, Koirala N. Food safety in developing countries: Common foodborne and waterborne illnesses, regulations, organizational structure, and challenges of food safety in the context of Nepal. *Food Frontiers*. 2025;6(1):86-123. doi:10.1002/fft2.517
- Blair D. Changing face of paragonimiasis. *Trop Parasitol*. 2020;10(2):168-171. doi:10.4103/tp.TP_120_20
- Richter J. Current status of the treatment of paragonimiasis. *One Health Implement Res*. 2022;2(2):96-107. doi:10.20517/ohir.2022.10
- Huang Y, Yang X, Zhu Y, Bai H, Jiao F, Jin H, Chen H, Guo Y, Cui P, Wang Y, Luo Y. Analysis of clinical characteristics of 213 clinically diagnosed pediatric patients with paragonimiasis from Yunnan, China. *BMC Infect Dis*. 2025;25(1):397. doi:10.1186/s12879-025-10776-y
- Yoshida A, Doanh PN, Maruyama H. Paragonimus and paragonimiasis in Asia: An update. *Acta Trop*. 2019;199:105074. <https://doi.org/10.1016/j.actatropica.2019.105074>
- Adams AM. Foodborne trematodes: Paragonimus and Fasciola. In: Ortega Y, Sterling C, editors. *Foodborne Parasites: Food Microbiology and Food Safety*. Springer: Cham; 2018, pp. 293-324. https://doi.org/10.1007/978-3-319-67664-7_13
- Shu QH, Yang Y, Li SD, Zhao JS, Li SH, Wang MM, Wang WQ, Tian M, He SM, Ma ZQ, Zhu M, Wang WL. Analysis of the misdiagnosis of 8 adult cases of paragonimiasis with lung masses as the main manifestation in Xishuangbanna, Yunnan. *J Cardiothorac Surg*. 2021;16(1):28. doi:10.1186/s13019-021-01408-y

8. Kunitomo K, Yumoto S, Tsuji T. A Case of Paragonimiasis in a Patient with Wet Cough. *Am J Trop Med Hyg.* 2020;103(3):939-940. doi:10.4269/ajtmh.20-0395
9. Poudyal BS, Paudel B, Bista B, Shrestha GS, Pudasaini P. Clinical, laboratory and radiological features of paragonimiasis misdiagnosed as pulmonary tuberculosis. *Iran J Parasitol.* 2022;17(3):410-414. doi:10.18502/ijpa.v17i3.10632
10. Dharanisha NK, Saminathan M, Mamta P, Ramesh KR, Ananda KJ, Giridhar P, Byregowda SM. Parasitic pneumonia caused by *Paragonimus* spp. in a wild Royal Bengal Tiger, Mysuru, South India. *J Parasit Dis.* 2019 Sep;43(3):528-533. doi: 10.1007/s12639-019-01112-8
11. Kwo EH, Miyazaki I. *Paragonimus westermani* (Kerbert, 1878) from tigers in north Sumatra, Indonesia. *J Parasitol.* 1968;54:630. <https://pubmed.ncbi.nlm.nih.gov/5757735/>
12. Dawa N, Singay J. Cross-border mobility and epidemic response in Southeast Asia: The way forward. *Preventive Medicine Research & Reviews.* 2025;2(5):252-253. doi:10.4103/PMRR.PMRR_96_25
13. Belizario V, Gigataras AJ, Ong LA. Review epidemiology and control of paragonimiasis in Southeast Asia and Western Pacific regions: Lessons learnt and the way forward. *The Southeast Asian Journal of Tropical Medicine and Public Health.* 2022;52(6):836-852. <https://journal.seameotropmednetwork.org/index.php/jtropmed/article/view/221>
14. Yadav A, Kumar A, Agarwal D, Kumar A. A curious case of hemoptysis. *Med J Armed Forces India.* 2022;78(Suppl 1):S266-S268. doi:10.1016/j.mjafi.2019.10.007
15. Sarabeev V, Shvydka S, Lisitsyna O, Oros M, Miterpáková M, Žďimalová M. The sample size matters: Evaluating minimum and reasonable values in prevalence studies. *Nature.* 2025;55(13):683-93. doi:10.1016/j.ijpara.2025.05.003
16. delos Trinos JPC, Sison OT, Anino MRC, Lacuna JDM, Jorge MC, Belizario VY. Identification of suspected paragonimiasis-endemic foci using a questionnaire and detection of paragonimus ova using the Ziehl-Neelsen technique in Zamboanga Region, the Philippines. *Pathog Glob Health.* 2020;114(3):127-35. doi:10.1080/20477724.2020.1741900
17. Xunhui Z, Qingming K, Qunbo T, Haojie D, Lesheng Z, Di L, Jianzu D, Bin Z, Rui C, Tianping W, Shaohong L. DNA detection of *Paragonimus westermani*: Diagnostic validity of a new assay based on loop-mediated isothermal amplification (LAMP) combined with a lateral flow dipstick. *Acta Trop.* 2019;200:105185. <https://doi.org/10.1016/j.actatropica.2019.105185>
18. Resuh V, Kotso A, Kera V, Walling L, Mawlein I, Wankhar W. A review on Paragonimiasis and its differential diagnosis technique. *Biotech Res Asia.* 2024;21(1):81-7. doi:10.13005/bbra/3204
19. Guerrero JGG, Belizario VY. Hidden in plain sight: lessons on misdiagnosis of pulmonary paragonimiasis in a setting of high burden of pulmonary tuberculosis from Zamboanga Peninsula, the Philippines. *J Parasit Dis.* 2025;49(4):908-16. doi:10.1007/s12639-025-01818-y
20. Mahato AK, Shah S, Sah SK, Rupak KC, Adhikari B, Pokhrel A. Spontaneous pneumothorax secondary to pulmonary paragonimiasis: A case report highlighting diagnostic delay in Eastern Nepal. *Respirol Case Rep.* 2025;13:e70131. <https://doi.org/10.1002/rccr2.70131>
21. Villanueva-Villegas R, Diaz-Mendoza J, Salas-Lopez J, Espiche C. Paragonimiasis misdiagnosed as pulmonary tuberculosis: A case report. *Cureus.* 2023;15(3):e36169. <https://doi.org/10.7759/cureus.36169>
22. Lee J, Ryu JS. Current status of parasite infections in Indonesia: A literature review. *Korean J Parasitol.* 2019;57(4):329-339. doi:10.3347/kjp.2019.57.4.329
23. Esteban JG, Muñoz-Antoli C, Toledo R, Ash LR. Diagnosis of human trematode infections. *Adv Exp Med Biol.* 2024;1454:541-82. https://doi.org/10.1007/978-3-031-60121-7_14
24. Bik EM. Publishing negative results is good for science. *Access Microbiol.* 2024;6:000792. <https://doi.org/10.1099/acmi.0.000792>
25. Bepalov A, Steckler T, Skolnick P. Be positive about negatives—recommendations for the publication of negative (or null) results. *Eur Neuropsychopharmacol.* 2019;29(12):1312-20. doi:10.1016/j.euroneuro.2019.10.007
26. Grubic N, Johnston A, Randhawa VK, Humphries KH, Rosella LC, Maximova K. Breaking down bias: A methodological primer on identifying, evaluating, and mitigating bias in cardiovascular research. *Can J Cardiol.* 2025;41(5):996-1009. doi:10.1099/acmi.0.000792
27. Rabone M, Wiethase J, Clark PF, Rollinson D, Cumberlidge N, Emery AM. Endemicity of paragonimus and paragonimiasis in Sub-Saharan Africa: A systematic review and mapping reveals stability of transmission in endemic foci for a multi-host parasite system. *PLoS Negl Trop Dis.* 2021;15(2):e0009120. <https://doi.org/10.1371/journal.pntd.0009120>
28. Singh TS, Devi KR, Ratankumar K, Laishram S, Dhabali T, Haorongbam S. Paragonimiasis: A continuing public health problem in northeast India. *Indian J Med Microbiol.* 2025;55:100866. <https://doi.org/10.1016/j.ijmmb.2025.100866>

How to Cite: Machrumnizar, Tan S, Yuliana, Kusumaratna RK. Absence of *Paragonimus* DNA and Eggs in Tuberculosis Patients in Indonesia: Implications for Surveillance and Public Health Awareness. *Int Res J Multidiscip Scope.* 7(1):1123-1132. DOI: 10.47857/irjms.2026.v07i01.08660

Absence of Paragonimus DNA and Eggs in Tuberculosis Patients in Indonesia: Implications for Surveillance and Public Health Awareness

ORIGINALITY REPORT

8%

SIMILARITY INDEX

7%

INTERNET SOURCES

6%

PUBLICATIONS

%

STUDENT PAPERS

PRIMARY SOURCES

1	repository.iaincurup.ac.id Internet Source	1%
2	vetdergi.kafkas.edu.tr Internet Source	1%
3	Zhi-Hong Ning, Xiu-Heng Wang, Hui-Fang Tang, Heng-Jing Hu. "The Role of SGLT1 in Atrial Fibrillation and Its Relationship with Endothelial-Mesenchymal Transition", Biochemical and Biophysical Research Communications, 2025 Publication	<1%
4	ijmpr.in Internet Source	<1%
5	123dok.net Internet Source	<1%
6	www.atlantis-press.com Internet Source	<1%
7	journal.ipb.ac.id Internet Source	<1%
8	narraj.org Internet Source	<1%
9	repo.uinsatu.ac.id Internet Source	<1%

10	"Digenetic Trematodes", Springer Science and Business Media LLC, 2024 Publication	<1 %
11	Xiaomei Wang, Junbo Wu, Juan Huang, Ye Zeng, Zugao Xu, Changzhen Li. "Ectopic Paragonimiasis Presenting as Massive Pericardial Effusion in a Child: A Rare Diagnostic Challenge", International Journal of Infectious Diseases, 2025 Publication	<1 %
12	journal.hep.com.cn Internet Source	<1 %
13	krishikosh.egranth.ac.in Internet Source	<1 %
14	www2.mdpi.com Internet Source	<1 %
15	www.i-jmr.org Internet Source	<1 %
16	revistas.ups.edu.ec Internet Source	<1 %
17	Pramod Prasad. "Phylogenetic reconstruction using secondary structures and sequence motifs of ITS2 rDNA of Paragonimus westermani (Kerbert, 1878) Braun, 1899 (Digenea: Paragonimidae) and related species", BMC Genomics, 2009 Publication	<1 %
18	www.dovepress.com Internet Source	<1 %

Exclude quotes Off

Exclude matches < 10 words

Exclude bibliography On