SICOT-J

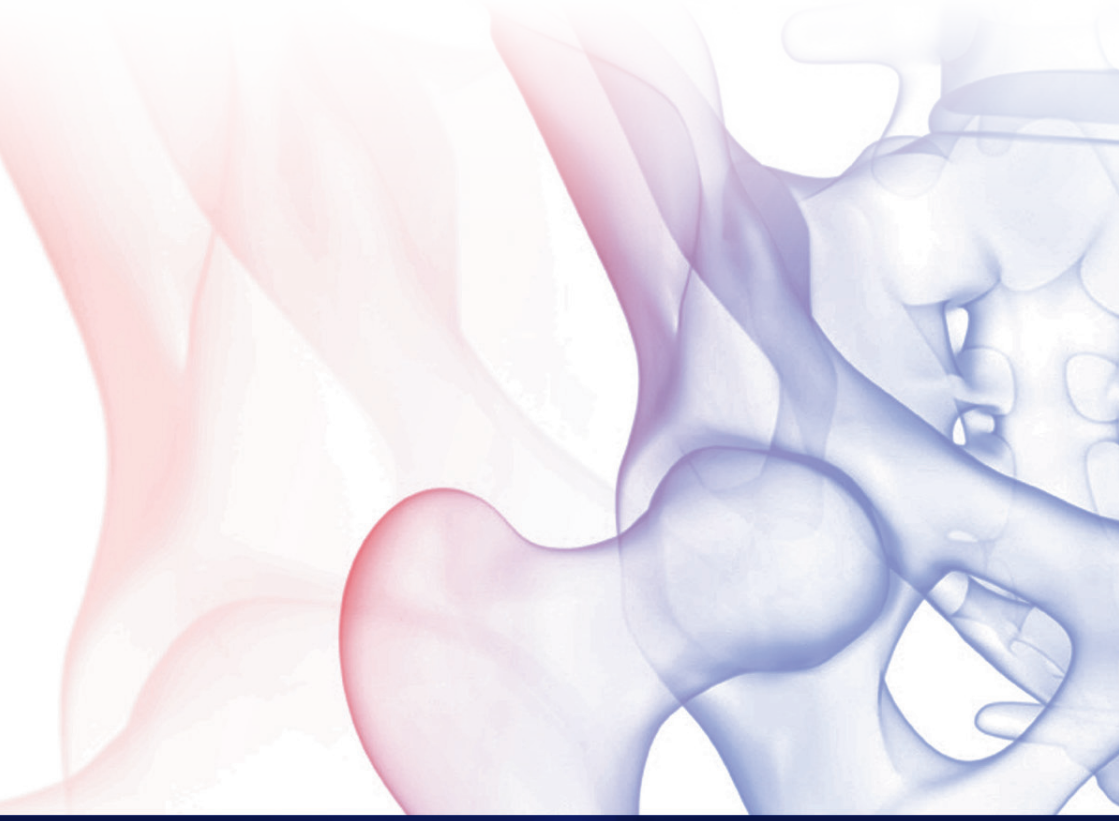

sicot-j.org

edp sciences

By using this website, you agree that EDP Sciences may store web audience measurement cookies and, on some pages, cookies from social networks. More information and setup

Yes No

Editorial board

Editors-in-Chief

Sébastien Lustig, Hôpital de la Croix Rousse, Université Claude Bernard Lyon I, France

Andreas F. Mavrogenis, Athens, National and Kapodistrian University of Athens, School of Medicine, Greece

Raju Vaishya, Indraprastha Apollo Hospitals, New Delhi, India

Past Editor-in-Chief

(2015-2022) **Jacques Caton**, Lyon, Institut d'orthopédie, France

(2015-2020) **Hatem Said**, Assiut, Assiut University Hospital, Egypt

Deputy Editors

Maximilian Rudert, Würzburg, Orthopaedic Clinic König-Ludwig-Haus, Germany

Mohamed Sukeik, Al Khobar, Dr Sulaiman Al Habib Hospital, Saudi Arabia

Associate Editors

Chahine Assi, Beyrouth, Lebanese American University Medical Center, Lebanon

Alberto Carli, New York, Hospital for Special Surgery, USA

Jochen Eulert, Würzburg, Würzburg University, Germany

Panagiotis Giannoudis, Leeds, University of Leeds, UK

Philippe Hernigou, University Paris-Est-Creteil-Val-de-Marne (UPEC), Orthoped Department, France

Ashok Johari, Mumbai, Children's Orthopedic Centre, India

Hans C. Pape, Zürich, UniversitatsSpital Zürich, Switzerland

Jean-Louis Prudhon, Grenoble, Centre Ostéo-Articulaire des Cèdres, France

Marius Scarlat, Toulon, Clinique Saint-Michel, France

Vijay Shetty, Mumbai, India

James Waddell, Toronto, University of Toronto, Canada

Xiaoming Wu, Shanghai, Shanghai General Hospital, Shanghai Jiao Tong University School of Medicine, China

Nianfei Zhang, Beijing, China-Japan Friendship Hospital, China

Section Editors

Mahmoud Abdel Karim (PELVIC and ACETABULAR TRAUMA, HIP & KNEE), Cairo University, Egypt

Ajeya Adhikari (KNEE), London, South West London Elective Orthopaedic Centre, UK

Lucas Anderson (HIP and KNEE), University of Utah, USA

Andrea Angelini (MUSCULOSKELETAL ONCOLOGY), Padova, University of Padova, Italy

Alaaeldin Azmi Ahmad (PEDIATRIC ORTHOPEDIC), the West Bank, Palestine Polytechnic University, Palestine

Cécile Batailler (KNEE and HIP), Lyon, Hôpital de la Croix Rousse, France

Yoan Bourgeault-Gagnon (HIP and KNEE SPORT MEDICINE), Ontario, McMaster University, Canada

Rozalia Dimitriou (PEDIATRIC ORTHOPAEDICS), Heraklion, University of Crete, Greece

Yasser ElBatrawy (DEFORMITY CORRECTION), Cairo, Cairo International Centre for Limb Lengthening and Reconstruction, Egypt

Mohammad El-Sharkawi (SPINE), Assiut, Assiut University Hospital, Egypt

Patricia Fucs (PEDIATRICS), São Paulo, Santa Casa Medical School and Hospitals, Brazil

Ahmed H Abdelazeem (HIP), Giza, Cairo University, Egypt

Anna A. Kulidjian (ORTHOPAEDIC TUMOR SURGERY), La Jolla, Scripps Clinic, USA

Satish Kutty (HIP), Harlow, Princess Alexandra Hospital, UK

Ian Leslie (HAND), Bristol, Bristol Royal Infirmary, UK

Thomas Neri (KNEE SPORT MEDICINE), University Hospital Centre of Saint-Étienne and LIBM EA 7424, University of Lyon - Jean Monnet, France

Emad S B Saweeres (HIP, KNEE and BIOMECHANICS), Cairo, The General Organisation for Teaching Hospitals and Institutes (GOTHI), Egypt

Kumar Shantanu Anand (FOOT and ANKLE), Bihar, Anand Hospital, Purnea, India

Marc Tey Pons (HIP), Barcelona, Institut Hospital del Mar d'Investigacions Mediques (IMIM), Spain

Theodoros H. Tosounidis (TRAUMATOLOGY), Heraklion, University of Crete, Greece

SICOT Executive Committee

President: Vikas Khanduja (United Kingdom)

Past President: Philippe Hernigou (France)

Secretary General: Marc Patterson (United Kingdom)

Treasurer: Suresh Sivananthan (Malaysia)

President Elect: Hatem Said (Egypt)

By using this website, you agree that EDP Sciences may store web audience measurement cookies and, on some pages, cookies from social networks. More information and setting
Ok! No

SICOT-J articles are available online as soon as the production process is complete.
You currently operate based on the expected volume of articles you'll complete. To keep abreast of new articles, you may either visit this page regularly or subscribe to our Feed alert.

SICOT-J

Volume 12 (2026) (in progress)

Sort by Section | Sort by article number

Export the citation of the selected articles Export
Save all

Special Issue: Newer Horizons in Paediatric Orthopaedics & Trauma

Open Access
Review
Early and late initiation of the Ponseti method: pooled comparative outcomes in congenital idiopathic clubfoot: a systematic review and meta-analysis 36
Abdulaal Aidus, Abdullah I. Khurbi, Yousef Alsanad, Turki Alsubhi and Fahad Alshaghan
Published online: 26 February 2026
https://doi.org/10.1051/sicotj/2026006
Abstract · Full HTML · PDF (502.1 KB) · ePub (2.246 MB) · Supplemental Material · Referenced Sources

Open Access
Review
Recent research trends in pediatric bone and joint infections: A 50-year bibliometric analysis (1976–2025) 38
Tuo Zhang, Kelvin Kofler, Ryan Pathan Gaipa, Ishwar Modi, Nabeel Mahmood Alamilaqi, K.S. M and Abhishek Vaish
Published online: 27 May 2026
https://doi.org/10.1051/sicotj/2026038
Abstract · Full HTML · PDF (4.165 MB) · ePub (2.246 MB) · Supplemental Material · Referenced Sources

Open Access
Review
Management of pediatric distal radius fractures - A systematic review and meta-analysis 36
J. Terrence Jose Jerome, G. Surendran and Thirumagal Rajasugeey
Published online: 05 June 2026
https://doi.org/10.1051/sicotj/2026036
Abstract · Full HTML · PDF (1.587 MB) · ePub (1.390 MB) · References · Supplemental Material · Referenced Sources

Open Access
Review
Defining the diplomaty: femoral neck in osteogenesis imperfecta: a radiographic and anatomical entity with diagnostic threshold 40
Vincent Georgen, Jad Zeidan, Alice Badino, Stephanie Pannier, Ibrahim Salkaz and Zagorka Popo
Published online: 03 July 2026
https://doi.org/10.1051/sicotj/2026040
Abstract · Full HTML · PDF (498.1 KB) · ePub (1.088 MB) · References · Supplemental Material · Referenced Sources

Special Issue: Techno-Revolution and Digital Innovations in Orthopedics Reshaping Musculoskeletal Treatments

Open Access
Review
Global trends and hotspots in robotic-assisted orthopedics from 1992 to 2025: a bibliometric and visualized analysis 31
Yuanchun Fu, Dongxiang Tang, Fuqiang Gao, Sebastian Vasilescu and Mingjun Wang
Published online: 19 May 2026
DOI: https://doi.org/10.1051/sicotj/2026031
Abstract · Full HTML · PDF (2.182 MB) · ePub (2.162 MB) · References · Supplemental Material · Referenced Sources

Open Access
Review
Cost reduction associated with intermediate evaluation of low-risk orthopaedic assessment: A cost-minimization analysis. 41
Noel Diamond Finn, Daniel Tavares Malhotra, Kaad Capellas Junqueira Pamiera, Tarcisio Augusto Duarte Acosta, Flavio Tocci Moreira, Karen Francine Fuller, Carlos Henrique Gumiero Pedroti and Helton Knobel
Published online: 27 July 2026
https://doi.org/10.1051/sicotj/2026041
Abstract · Full HTML · PDF (2.222 MB) · ePub (3.063.3 kB) · References · Supplemental Material · Referenced Sources

Open Access
Review
Glucagon like peptide 1 receptor agonists in orthopaedics 61
Ioannis Trichas, Ioannis Papadopoulos, Sotirios Fitilis, Alexandros D. Avramidelos, Symeon Tsourvis, Polyxeni Makrea, Theodoros Sarantopoulos and Sebastian Lustig
Published online: 06 March 2026
https://doi.org/10.1051/sicotj/2026012
Abstract · Full HTML · PDF (1.207 MB) · ePub (1.141 MB) · References · Supplemental Material · Referenced Sources

Open Access
Review
Perspectives on SICOT-J Volume 11 (2025) 62
Raju Vaishya, Sebastien Lustig, Ashfaque P. Bhavnagarwala and Vikas Khanduja
Published online: 29 April 2026
https://doi.org/10.1051/sicotj/2026004
Abstract · Full HTML · PDF (1.042.8 kB) · ePub (764.6 kB) · References · Supplemental Material · Referenced Sources

Open Access
Review
Cybersurgery is imperative in robotic arthroplasty 63
Vaishya Bagaria, Raju Vaishya, Abhishek Vaish and Sebastien Lustig
Published online: 29 April 2026
https://doi.org/10.1051/sicotj/2026005
Abstract · Full HTML · PDF (1.002.3 kB) · ePub (786.2 kB) · References · Supplemental Material · Referenced Sources

Open Access
Review
Embracing uncertainty: a core competency for the global orthopaedic surgeon 64
Ashish Gupta
Published online: 26 May 2026
https://doi.org/10.1051/sicotj/2026007
Abstract · Full HTML · PDF (1.013.3 kB) · ePub (783.5 kB) · References · Supplemental Material · Referenced Sources

Shoulder

Open Access
Review
Hydrocephalus arising from long-standing Dysplasia Epiphysealis Hemimelica of the proximal humerus: A case report 5
Nikolaos N. Stamoulakos, Dimitrios P. Papagkiouras, Efstratios Papadopoulos, Christos Kontogeorgakos, Eleftherios Lykoudis and Panagiotis J. Papagelopoulos
Published online: 03 February 2026
https://doi.org/10.1051/sicotj/2026001
Abstract · Full HTML · PDF (278.8 kB) · ePub (3.580 MB) · References · Supplemental Material · Referenced Sources

Open Access
Review
Anatomic extension-based description for rotator cuff calcifications: retrospective analysis of 100 consecutive cases 17
Daniel Wong, Jorge Rojas Lemus, Diego Gómez, Federico Alfieri, Christos Koulas, Daniel Nieto Serrano and Ricardo Sims
Published online: 26 April 2026
https://doi.org/10.1051/sicotj/2026029
Abstract · Full HTML · PDF (1.004.8 kB) · ePub (2.082 MB) · References · Supplemental Material · Referenced Sources

Open Access
Review
Routine long head of the biceps release improves pain and functional outcomes after arthroscopic rotator cuff repair of degenerative tears: a meta-analysis of randomized controlled trials 18
Dimitrios P. Papagkiouras, Athanasios Anastopoulos, Jamie R. Walker, Ioannis Papadopoulos, Nikolaos Stamoulakos, Konstantinos Tsikopoulos, Ioannis Gkiatas, Vasileios S. Nikolaou and George Babis
Published online: 27 April 2026
https://doi.org/10.1051/sicotj/2026030
Abstract · Full HTML · PDF (268.7 kB) · ePub (3.016 MB) · References · Supplemental Material · Referenced Sources

Open Access
Review
The essential role of rehabilitation in operative and non-operative shoulder management: A 40-year experience (1985–2025) 24
Dominique F. Gaudelli and Marcus W. Scarter
Published online: 27 April 2026
https://doi.org/10.1051/sicotj/2026024
Abstract · Full HTML · PDF (1.068 MB) · ePub (3.054 MB) · References · Supplemental Material · Referenced Sources

Elbow

Open Access
Review
Development and measurement of elbow and knee joints using an electro-goniometer in healthy subjects: A preliminary study 23
Ryosuke Kawamura, Ryo Kawamura, Takashi Nishiwaki, Hideyuki Koshimizu, Chuichi Tsunemoto, Chieko Kawamura and Hirotaroing Yuamoyo Kawai
Published online: 03 May 2026
https://doi.org/10.1051/sicotj/2026023
Abstract · Full HTML · PDF (644.8 kB) · ePub (2.341 MB) · References · Supplemental Material · Referenced Sources

Open Access
Review
Anesthesia nerve anchor fixation of medial epicondyle fractures of the capitellum: A technical note with preliminary clinical outcomes 36
Michal Gurfinkel, Maciej Cieszkin, Maciej Wojtowicz, Jan Przybyszewski, Marcin Domalatak and Jędrzej Lachan
Published online: 28 May 2026
https://doi.org/10.1051/sicotj/2026035
Abstract · Full HTML · PDF (804.6 kB) · ePub (1.318 MB) · References · Supplemental Material · Referenced Sources

Wrist & Hand

Open Access
Review
Outcomes of arthrodeses versus partial arthroplasties for stage II SLAC/SNAC wrists: Long-term outcomes from a single-surgeon comparative series 7
Spyridon Maris, Emmanouil Ayoglu, Alexandros Apostolopoulos, Dimitrios Mathioudakis, Panagiotis Koukoumaris, Panayiotis J. Papagelopoulos and Olga Sarridou-Papadopoulou
Published online: 03 February 2026
https://doi.org/10.1051/sicotj/2026002
Abstract · Full HTML · PDF (2.922 kB) · ePub (4.019 kB) · References · Supplemental Material · Referenced Sources

Hip

Open Access
Review
Factors driving higher opioid use after total hip arthroplasty: insights from a large-scale, tertiary centre analysis 8
Andrew Kotsialy, Shannon Tse, Nadim Kassem, Adam T. Yoon, Crystalline S. The, Isabella Carrino Hatfield, Warren Wigmanian, Ron Pharaoe and Yama S. Haddad
Published online: 03 February 2026
https://doi.org/10.1051/sicotj/2026004
Abstract · Full HTML · PDF (2.9 kB) · ePub (1.252 MB) · References · Supplemental Material · Referenced Sources

Open Access
Review
No dislocation rate gap between single and two-mobility cups in a cemeteries Dual Mobility Cup. 11
Justine Boland, Harry Efseaghane, Nicolas Zadel, Thomas Neri, Frédéric Farizon and Bertrand Boyer
Published online: 26 March 2026
https://doi.org/10.1051/sicotj/2026011
Abstract · Full HTML · PDF (492.9 kB) · ePub (2.077 MB) · References · Supplemental Material · Referenced Sources

Open Access
Review
Osteonecrosis in sickle cell disease: Contemporary practice and outcomes across African healthcare settings 13
Ebenezer Ayesiga, Ronald Ssebuufu, Dauda Obaseki, Abdullah Zubair, Simon Jacobs, Chiadozie Okpala, Patrick Dembele, Onajite Emmanuel, Gregory Dehlke and Ogochukwu Ugwonali
Published online: 08 April 2026
https://doi.org/10.1051/sicotj/2026013
Abstract · Full HTML · PDF (1.007.7 kB) · ePub (3.779.1 kB) · References · Supplemental Material · Referenced Sources

Open Access
Review
Long-versus short capitulumsparing humeral nail for treatment of unstable intercondylar fractures: A single-blinded randomized controlled trial 14
Abdelrahman Amr Abouelela, Ibrahim Abdel-Amir and Ahmed Fayed Kotb
Published online: 13 April 2026
https://doi.org/10.1051/sicotj/2026014
Abstract · Full HTML · PDF (1.245 MB) · ePub (2.241 MB) · References · Supplemental Material · Referenced Sources

Open Access
Review
Coagulopathy in Historically, did Cemented Thompson perform better than uncemented Austin Moore hemiarthroplasty for femoral neck fractures? A meta-analysis of available evidence 16
Mohammed Ali Ali, Ahmed Ali Ali, Ahmed Ali Ali, Sami Gaballa, Yousef Mohamed, Muhammad Shaaqy, Ahmed Khalid, Mahmoud Mirsi, Ahmed M. Afifi, Nardeen Kaber, Hassan Gouhiche et al. 2 more
Published online: 16 April 2026
https://doi.org/10.1051/sicotj/2026016
Abstract · Full HTML · PDF (312.8 kB) · ePub (1.192 MB) · References · Supplemental Material · Referenced Sources

Open Access
Review
Latest versus supine positioning for proximal femoral nailing of unstable intertrochanteric fractures in geriatric patients: A prospective randomized comparative study 21
Wessam Fathey Elsaid, Hesham Osama Sayed, Tarha Hassan, Karim Abd Salam, Ann Amal Amin and Ahmed Sayed Kotb
Published online: 29 April 2026
https://doi.org/10.1051/sicotj/2026021
Abstract · Full HTML · PDF (812.9 kB) · ePub (1.704 MB) · References · Supplemental Material · Referenced Sources

Open Access
Review
Comparison of proximal femoral osteotomy necessary when performing open reduction and Dega acetabuloplasty in walking-age children with developmental dysplasia of the hip 22
Jinghang Yu, Liangxing Li, Liwei Shi, Lijun Zhang, Qiwei Li and Erbo Wang
Published online: 11 June 2026
https://doi.org/10.1051/sicotj/2026022
Abstract · Full HTML · PDF (1.024.8 kB) · ePub (853.6 kB) · References · Supplemental Material · Referenced Sources

Open Access
Review
Atypical femoral fracture: The perioprosthetic variant about two cases without bisphosphonate use 41
Guillaume Aubinger, Thomas Aubert, Thomas Kernarec, Philippe Lecler, and Simon Mantoir
Published online: 27 July 2026
https://doi.org/10.1051/sicotj/2026039
Abstract · Full HTML · PDF (211.2 kB) · ePub (1.870 MB) · References · Supplemental Material · Referenced Sources

Open Access
Review
A systematic review of Acetabular Offset Between the Preoperative Plan (mm)CAD/PC and Postoperative Radiographic Measurements: an overlooked source of error that affects reintroduction of global offset after THA 39
Arasda Manop, Clément Casimiroy, Tanguy Vendeuvre, Pierre Khoo, Guillaume Anthony Dahl and Mathieu Genevay
Published online: 07 August 2026
https://doi.org/10.1051/sicotj/2026042
Abstract · Full HTML · PDF (1.1 MB) · ePub (1.1 MB) · References · Supplemental Material · Referenced Sources

Lower Limb

Open Access
Review
Evaluation of the long-term functional outcome and quality of life after osteosynthesis in the management of primary malignant bone tumors about the knee in Children 20
Hoorin Mafi, Walid Obeid, Lennart Scheys and Lorenz Wibe
Published online: 27 April 2026
https://doi.org/10.1051/sicotj/2026020
Abstract · Full HTML · PDF (1.012.6 kB) · ePub (1.302 MB) · References · Supplemental Material · Referenced Sources

Open Access
Review
Lateral versus supine positioning for proximal femoral nailing of unstable intertrochanteric fractures in geriatric patients: A prospective randomized comparative study 21
Wessam Fathey Elsaid, Hesham Osama Sayed, Tarha Hassan, Karim Abd Salam, Ann Amal Amin and Ahmed Sayed Kotb
Published online: 29 April 2026
https://doi.org/10.1051/sicotj/2026021
Abstract · Full HTML · PDF (812.9 kB) · ePub (1.704 MB) · References · Supplemental Material · Referenced Sources

Open Access
Review
Comparing outcomes for retrograde intramedullary nailing vs. antegrade intramedullary nailing for femoral fractures - a systematic review and meta-analysis 35
Kaushal Kapadia, Mohammad Ibrahim Khalil, Thoya Manickavasi, Ashish Ann Alexander, Hussain Shahid, Karim Abdelghafar and Pranav Mehta
Published online: 26 May 2026
https://doi.org/10.1051/sicotj/2026033
Abstract · Full HTML · PDF (1.219 MB) · ePub (1.601 MB) · References · Supplemental Material · Referenced Sources

Open Access
Review
Lateral pasteurizer approach versus transpatellar splitting approach in intramedullary nailing of diaphyseal tibia fractures, a randomized controlled trial 37
Amr Amal Amin, El Zaher Hassan El Zaher, Hassan Mahmoud Abd El Salam Wafa, Ahmed Mohamed Khalaf El Ghazaly and Amr Mohamed Nagy
Published online: 18 June 2026
https://doi.org/10.1051/sicotj/2026037
Abstract · Full HTML · PDF (1.012.9 kB) · ePub (1.656 MB) · References · Supplemental Material · Referenced Sources

Knee

Open Access
Review
Image-based robotic assisted conversion from partial to total knee arthroplasty under functional alignment: Comparable outcomes to primary total knee arthroplasty 1
Christos Koulouvaris, Angel Ross, Chandramani Mahajanna, Charalampos Kontos, Sebastian Lustig, Neha Tandrajan and Konstantinos Drosakis
Published online: 22 January 2026
https://doi.org/10.1051/sicotj/2026001
Abstract · Full HTML · PDF (419.6 kB) · ePub (1.218 MB) · References · Supplemental Material · Referenced Sources

Open Access
Review
Knee joint new on guard cell tumor of bone 2
Ming Tsukamoto, Costantino Errani, Tessa Bianchi, Tomoo Zamora, Eduardo Ortiz-Cruz, Raju Bhaskara Rajasekaran, Aquinas Yau, Tao Li, Israel Pérez-Muñoz, Francisco Linares et al. (4 more)
Published online: 22 January 2026
https://doi.org/10.1051/sicotj/2026004
Abstract · Full HTML · PDF (2.001 MB) · ePub (1.405 MB) · References · Supplemental Material · Referenced Sources

Open Access
Review
Function of screw insertion for internal fixation plate in distal femoral osteotomy: Evaluation using axial computer tomography imaging 3
Ryosuke Kawamura, Ryuichi Nakamura, Akira Okano, Kazuki Matsumoto, Jun Otsu and Koji Kanzaki
Published online: 28 January 2026
https://doi.org/10.1051/sicotj/2026003
Abstract · Full HTML · PDF (2.005 MB) · ePub (1.165 MB) · References · Supplemental Material · Referenced Sources

Open Access
Review
A systematic review of radiological outcomes and implant positioning in robotic-assisted functionally aligned robotic total knee arthroplasty 4
Ioannis Gkiatas, Angelos D. Angelopoulos, Konstantinos Tsikopoulos, Ioannis Papadopoulos, Konstantinos Drosakis, Christos Koulouvaris and Sebastian Lustig
Published online: 29 January 2026
https://doi.org/10.1051/sicotj/2026005
Abstract · Full HTML · PDF (527.0 kB) · ePub (1.207 MB) · References · Supplemental Material · Referenced Sources

Open Access
Review
Robotic positioning in robotic lateral unicompartmental knee arthroplasty: a step-by-step technique 6
Laura Andrada, Cesar Gonzalez Rancaño, Filippo Leggieri, Elena Serrano, Cécile Batailler and Sébastien Hess-Martin Lustig
Published online: 09 February 2026
https://doi.org/10.1051/sicotj/2026006
Abstract · Full HTML · PDF (268.2 kB) · ePub (715.1 kB) · References · Supplemental Material · Referenced Sources

Open Access
Review
Medial patellofemoral ligament reconstruction with a synthetic polymer suture tape graft and knotless anchors: Five-year clinical and functional outcomes 14
Wessam Fathey Elsaid, Mohamed Kahry, Mohamed Ann Hemida, Ahmed K. Khater, Mohammed K. Gabby and Fatma Hassan
Published online: 13 April 2026
https://doi.org/10.1051/sicotj/2026015
Abstract · Full HTML · PDF (502.6 kB) · ePub (3.339 MB) · References · Supplemental Material · Referenced Sources

Open Access
Review
Outcomes of a knee joint magnetic resonance imaging (MRI)-based model for finite element analysis (FEA) applications 16
Angelo J. Vanhouten, Kalliopi Vakanitsa, Alessandro Chiuso, Dimitrios Chiras, Georgios Tsoumpas, George Paraskevas, Konstantinos Katakalos and Adamantia Vasiou
Published online: 20 April 2026
https://doi.org/10.1051/sicotj/2026016
Abstract · Full HTML · PDF (1.401 kB) · ePub (1.331 MB) · References · Supplemental Material · Referenced Sources

Open Access
Review
Implant survival and factors associated with failure of cemented custom-made distal femoral megaprostheses after tumor resection 18
Gustavo Spostopulos, Michel Wahbah, Marie Kalbas, Lukáš Pazourek, Petr Bokal, Lukáš Kachtelík and Tomáš Tomáš
Published online: 20 April 2026
https://doi.org/10.1051/sicotj/2026018
Abstract · Full HTML · PDF (1.004.8 kB) · ePub (1.040 MB) · References · Supplemental Material · Referenced Sources

Open Access
Review
Pine-stuty: Effects of ovariectomy induced estrogen deficiency on the biomechanical and structural properties of the intact anterior cruciate ligament in a porcine model 19
Ryo Kawamura, Ryuichi Nakamura, Ryuichi Kanda, Masaya Kurahashi, Katsushi Takashima and Hirotaka Chikuda
Published online: 20 April 2026
https://doi.org/10.1051/sicotj/2026019
Abstract · Full HTML · PDF (528.2 kB) · ePub (1.125 MB) · References · Supplemental Material · Referenced Sources

Open Access
Review
Pilot study comparing operating room workflow and team ergonomics in robotic-assisted versus navigated total knee arthroplasty 24
Ashish Gupta, Ashish Bhatnagar and Vishal Kelkar Vasishtha
Published online: 05 May 2026
https://doi.org/10.1051/sicotj/2026024
Abstract · Full HTML · PDF (389.1 kB) · ePub (1.236 MB) · References · Supplemental Material · Referenced Sources

Open Access
Review
Single-stage total knee arthroplasty revision with extensor mechanism allograft: surgical technique 26
Tazeena Sarkar, Gerald DeRosa, Cécile Batailler, Elvire Servien and Sebastien Lustig
Published online: 05 May 2026
https://doi.org/10.1051/sicotj/2026026
Abstract · Full HTML · PDF (1.013.5 kB) · ePub (1.081.9 kB) · References · Supplemental Material · Referenced Sources

Open Access
Review
Flowing knees: variables affecting bone union and functional outcomes: a retrospective study of 72 cases 30
Nicolas Lerner, Thomas Ehlinger, Thibaud Druel, Frederic Bergeron, Antoine Berton, Anthony Vieira and Bernard Bizot
Published online: 11 June 2026
https://doi.org/10.1051/sicotj/2026030
Abstract · Full HTML · PDF (1.1 MB) · ePub (1.292 MB) · References · Supplemental Material · Referenced Sources

Open Access
Review
Precision in Medial pivot total knee arthroplasty: A retrospective study on mechanical axis alignment and functional outcomes with CT-based robotic-assisted surgery 40
Fadhil Bin Sabir and Ikram Yusoh
Published online: 24 June 2026
https://doi.org/10.1051/sicotj/2026040
Abstract · Full HTML · PDF (1.151.9 kB) · ePub (1.448 MB) · References · Supplemental Material · Referenced Sources

Open Access
Review
Accuracy and functional outcomes of robot-assisted total knee arthroplasty combined with inverse kinematic alignment: a 500-case consecutive series 41
Bryan Barton, Arnaud Boyé, Alban Dorvillers, Frédéric Farizon, Pierre-Henri Vernhet and Rémi Philippot
Published online: 25 July 2026
https://doi.org/10.1051/sicotj/2026042
Abstract · Full HTML · PDF (238.3 kB) · ePub (819.6 kB) · References · Supplemental Material · Referenced Sources

Open Access
Review
Posterior tibial slope in the Emirati population: The slope is over 12 degrees 45
Jesper Kiss, Lukas S. Tsitsilas, Zakia Amin, Sebastien Parratte and Robert T. LaPrade
Published online: 07 August 2026
https://doi.org/10.1051/sicotj/2026045
Abstract · Full HTML · PDF (1.159 MB) · ePub (1.519 MB) · References · Supplemental Material · Referenced Sources

Foot

Open Access
Review
Hybrid internally invasive correction for flexible flatfoot in young adults: a prospective cohort study 12
Ahmed S. Elsabaawy, Ahmed Khedr, Rio Bakr Zein, Mohamed Nagy, Mahmoud M. Shaaqy, Mohammed M. and Ahmed Khedr
Published online: 14 March 2026
https://doi.org/10.1051/sicotj/2026010
Abstract · Full HTML · PDF (628.9 kB) · ePub (1.270 MB) · References · Supplemental Material · Referenced Sources

Spine

Open Access
Review
Acupuncture as a usual care for chronic low back pain: a systematic review and meta-analysis of immediate and intermediate effects 3
Spyridon Sotiropoulos, Eleftherios Kafalias, Evaggelos Michalakakos, Andreas Mourgelas and George Georgoudis
Published online: 27 January 2026
https://doi.org/10.1051/sicotj/2026003
Abstract · Full HTML · PDF (754.8 kB) · ePub (1.005.9 kB) · References · Supplemental Material · Referenced Sources

Open Access
Review
Cervical osteotomy via anterior lumbar approach: a technical note 10
Hamdullah Bilgehatoglu, Ann-Marie Mylonas, Mohamed Abdul Fatah Fadlallah, Michel Mitchell, Karina Sylvana Gum and Erica Ghislene
Published online: 29 April 2026
https://doi.org/10.1051/sicotj/2026010
Abstract · Full HTML · PDF (1.007.9 kB) · ePub (1.013.1 kB) · References · Supplemental Material · Referenced Sources

EDP Sciences
Mentions légales Contacts Privacy policy
A SocietyFirst website

SICOT-J 2026, **12**, 19
© The Authors, published by EDP Sciences, 2026
https://doi.org/10.1051/sicotj/2026002

SICOT-J

Available online at:
www.sicot-j.org

SURGICAL TECHNIQUE

OPEN ACCESS

En bloc discectomy via anterior lumbar approach: a technical note

Harmantya Mahadhipta[1,2,3], Amri Muhyi[1], Muhamad Abdul Harist Fadhlizain[4], Mitchel Mitchel[3], Karina Sylvana Gani[3], and Erica Kholinne[3,5,*]

[1] Department of Orthopaedics and Traumatology, Tangerang General Hospital, Banten 15117, Indonesia
[2] Department of Orthopaedics and Traumatology, Cipto Mangunkusumo Hospital, Faculty of Medicine, Universitas Indonesia, Jakarta 10430, Indonesia
[3] Orthopedics and Traumatology, Gatam Institute, Eka Hospital, Tangerang 15321, Indonesia
[4] General Practitioner of Tangerang General Hospital, Banten 15117, Indonesia
[5] Department of Surgery, Faculty of Medicine, Universitas Trisakti, Jakarta 11440, Indonesia

Received 18 December 2025, Accepted 26 January 2026, Published online 20 April 2026

Abstract – *Introduction:* Implant subsidence remains one of the complications following lumbar interbody fusion and total lumbar disc replacement, often attributed to excessive and uneven preparation of the subchondral bone. To address this limitation, we describe a novel surgical approach – en bloc discectomy – designed to enable more controlled disc removal, preserve subchondral endplate integrity, and minimize the risk of implant subsidence. *Methods:* We describe the procedural steps for the en bloc discectomy, including patient positioning, surgical approach, and the specific technique using a Cobb spinal elevator to remove the cartilaginous en bloc. The technique's advantages include controlled disc removal, minimized subsidence, and even subchondral endplate preparation. *Results:* En bloc discectomy was successfully performed in our patient. No intraoperative or postoperative complications occurred, and all patients reported immediate and sustained symptomatic improvement. *Conclusion*: En bloc discectomy provides a safe and reproducible alternative to conventional (standard piecemeal discectomy) disc excision. By reducing endplate damage and implant subsidence, this technique has the potential to improve long-term stability and clinical outcomes in patients undergoing lumbar interbody procedures.

Key words: Lumbar vertebrae, Intervertebral disc displacement, Discectomy, Total disc replacement, Implant subsidence.

Introduction

Lumbar disc herniation and degenerative disc disease are major causes of low back pain and radiculopathy, often requiring surgery when conservative treatment fails [1]. Anterior lumbar interbody fusion (ALIF) is commonly performed because it provides direct disc access and restores disc height and alignment with limited posterior disruption [2]. However, implant subsidence, sinking of the interbody device into the endplate, remains a significant complication. Lumbar Disc Replacement (LDR) offers better stabilization and has been associated with lower subsidence rates than ALIF [3]. Reported subsidence rates for ALIF range from 6% to 23%, whereas Richard et al. documented a 3.4% rate for LDR. Subsidence may compromise fusion stability, reduce lordosis, cause recurrent symptoms, and necessitate revision surgery [4].

Successful lumbar interbody implantation via the anterior approach requires balancing two opposing goals: removing disc material to prepare a fusion bed while preserving endplate integrity for load-bearing. Conventional piecemeal discectomy can leave residual cartilage, is difficult to standardize, and risks damaging the subchondral bone [1, 2]. Excessive endplate removal weakens axial strength; one biomechanical study showed failure load reductions of 15% in TLIF and 36.6% in PLIF after aggressive preparation [5]. In ALIF, subsidence has been associated with over-preparation, cage–endplate mismatch, and suboptimal cage positioning [6], yet the ideal extent of endplate removal remains unclear. Similarly, size mismatch in lumbar disc replacement can cause the implant to rest on weaker central bone rather than the stronger peripheral ring, increasing subsidence risk [7]. Therefore, a more reproducible and endplate-preserving disc removal technique is needed.

To address these challenges, we introduce a novel en bloc discectomy technique for the anterior lumbar approach. Using

*Corresponding author: erica@trisakti.ac.id

This is an Open Access article distributed under the terms of the Creative Commons Attribution License (https://creativecommons.org/licenses/by/4.0), which permits unrestricted use, distribution, and reproduction in any medium, provided the original work is properly cited.

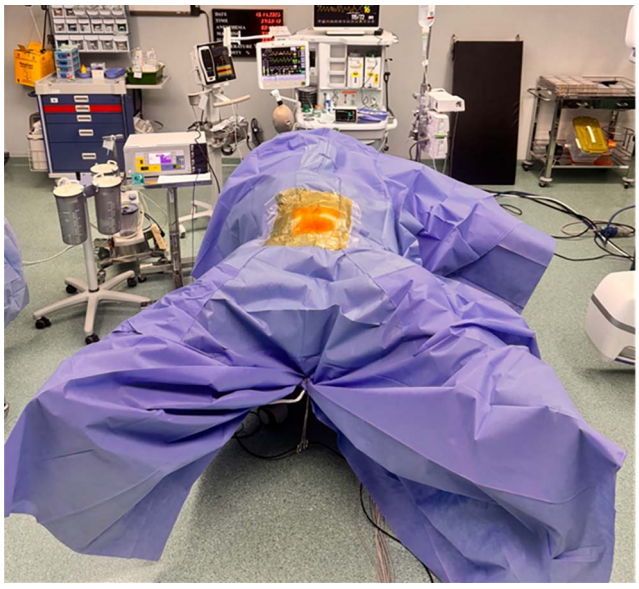

Figure 1. Patient was positioned in supine Da Vinci under sterile operative procedure.

a Cobb spinal elevator, this method enables controlled, systematic removal of the cartilaginous disc while minimizing endplate trauma. This technical note outlines the key procedural steps and presents illustrative clinical cases. Our goal is to provide a reproducible technique that achieves adequate disc clearance and may help reduce implant subsidence in anterior lumbar interbody procedures.

Surgical technique

Standard surgical instruments were utilized, including a Cobb elevator for disc space preparation, electrocautery for soft tissue management, and forceps for tissue handling. A third-generation total disc replacement implant, ProDisc®-L (Synthes Spine, West Chester, PA), was implanted following discectomy and endplate preparation, with attention to appropriate sizing and positioning based on preoperative planning.

Anesthesia, patient position, and incision

All procedures were performed under general anesthesia. The patient was positioned supine in the Da Vinci position on the operating table and prepared in a standard sterile fashion (Figure 1). The surgeon stood on the caudal side of the patient. The surgical exposure is achieved through a midline or paramedian incision at all lumbar levels, or a mini-Pfannenstiel incision at the L5/S1 level, utilizing a retroperitoneal approach with vascular mobilization and dissection. This approach offers several advantages, including direct midline visualization of the disc space and broad lateral exposure of the vertebral bodies, enabling efficient disc removal and rapid endplate preparation [8]. In addition, anterior access permits the use of larger interbody implants with increased surface area, facilitating more effective correction of spinal pathology. Preservation of the posterior spinal musculature and anterolateral psoas muscles may also contribute to reduced postoperative pain and functional impairment [9]. We then cauterized the anterior longitudinal ligament and the anterior portion of the disc, creating a rectangular window. Intraoperative fluoroscopy was used to confirm the target disc level.



Figure 2. The anterior part of the targeted disc was cauterized into a rectangular shape. “V” represent as vertebral body, and “D” represent as disc.

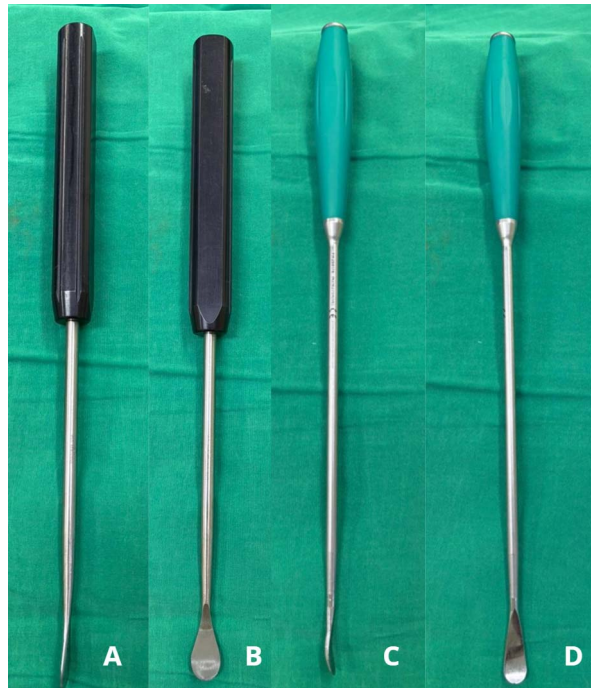

Figure 3. Cobb elevator (A&B) flat head (C&D) curve head.

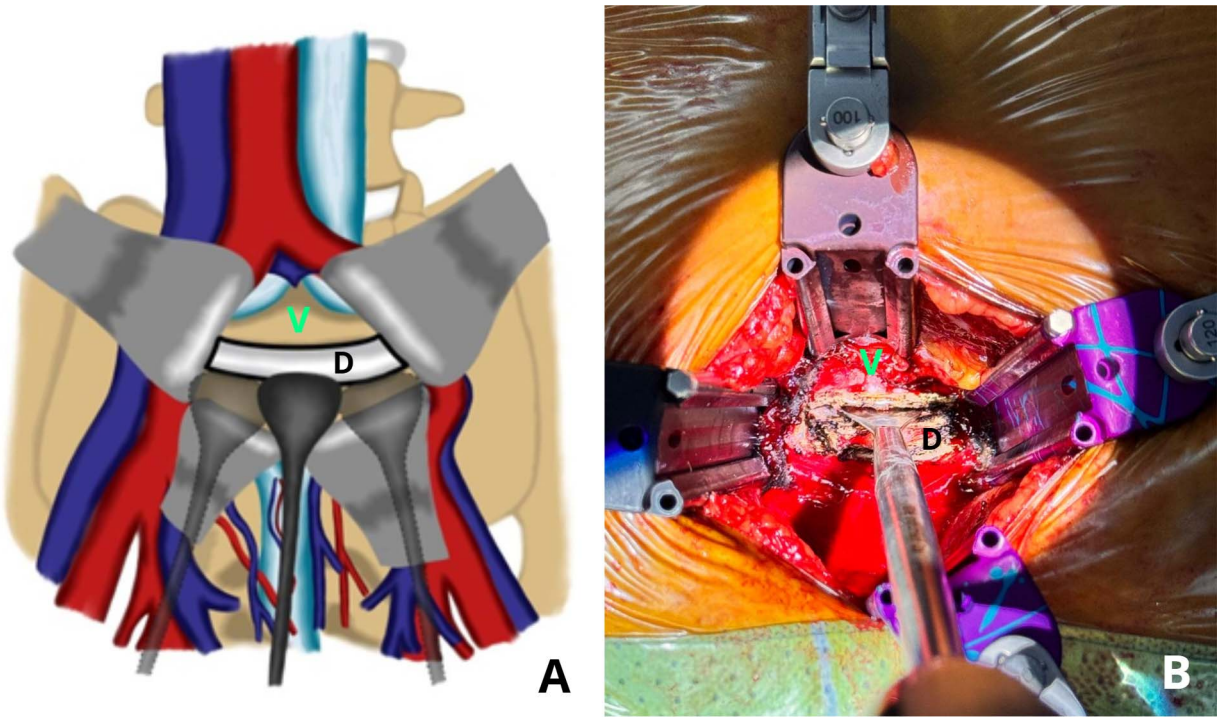

Figure 4. (A) Illustrative images. (B) Intraoperative images showing detachment of the superior and inferior parts of the nucleus pulposus from the posterior annulus using a flat head Cobb elevator, by "sweep and lift" technique. "V" represent as vertebral body, and "D" represent as disc.

Identification of disc–endplate borders

Following exposure, the anterior annulus fibrosus was incised longitudinally with an electrocautery/diathermy. The incision was made large enough to allow adequate visualization and working access while preserving the peripheral annular fibers to maintain stability. The anatomical borders of the working zone were then carefully identified, the superior and inferior limits were defined at the annulus-endplate junction, while the lateral borders were established approximately 1cm medial to the lateral edge of the disc, corresponding to the annulus-nucleus junction (Figure 2).

Dissection planes were then carefully developed superiorly and inferiorly between the vertebral endplates and the intervertebral disc. We are using two types of Cobb elevators: a flat-head for the superior and inferior portions, and a curved head for the lateral portion of the nucleus (Figure 3). Using a flat-head Cobb elevator, the cartilaginous endplate was elevated from the subchondral bone by the "sweep and lift technique" from the superior and inferior cartilage endplate. The lateral portion of the nucleus pulposus was detached from the lateral annulus using a curved head Cobb elevator by the "scooping technique" (Figures 4 and 5). Removal of the disc en bloc, which consists of the anterior annulus and the whole nucleus pulposus.

En bloc discectomy

The posterior annulus was removed using a Kerrison punch to ensure canal decompression. Disc material was removed centrally while carefully preserving the peripheral subchondral bone and ring apophysis to maintain load-bearing capacity and reduce the risk of cage subsidence. Any residual fragments were cleared with pituitary rongeurs or curettes as needed. The excised disc (Figure 6) was measured to guide cage sizing. Sequential trial implants were then inserted to assess disc height restoration, footprint coverage, and sagittal alignment, with care taken to avoid over-distraction and potential endplate injury.

The appropriately sized interbody device was inserted into the prepared disc space under fluoroscopic guidance. The device was positioned centrally to maximize contact with the peripheral ring apophysis, thereby optimizing axial load distribution and construct stability. Final placement and alignment were confirmed with anteroposterior and lateral fluoroscopic imaging (Figure 7).

After meticulous hemostasis, retractors were released, and the retroperitoneal contents were allowed to return to their anatomical position. A layered closure was performed, beginning with the fascia, followed by the subcutaneous tissue and skin. We have summarized a key surgical step and potential pitfalls in En Bloc Discectomy via Anterior Lumbar Approach (Table 1).

Potential complication and risks

En bloc resection is a surgical method designed to excise pathological tissue in one intact piece to obtain clear margins and minimize the likelihood of residual disease. However, despite its oncologic and biomechanical benefits, this technique is technically challenging and carries a greater risk of complications than piecemeal resection [10, 11]. En bloc resection necessitates the removal not only of the involved bone but also of

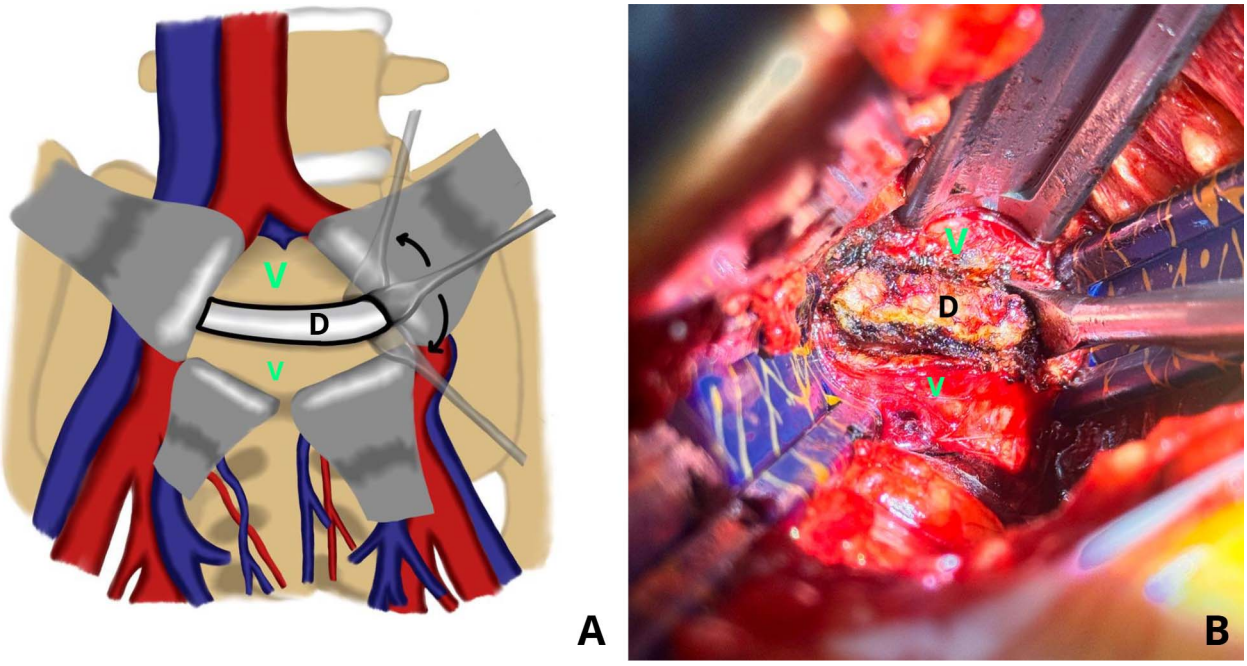

Figure 5. (A) Illustrative image. (B) Intraoperative images of the lateral detachment from the lateral annulus using a curved head Cobb elevator, by the "scooping" technique. "V" represent as vertebral body, and "D" represent as disc.

Figure 6. The excised disc fragment.

most of the surrounding stabilizing structures, resulting in complete spinal instability [12]. With the en bloc discectomy approach, common intraoperative complications include dural tears that will lead to cerebrospinal fluid (CSF) leakage, visceral and vascular injuries, malpositioning of surgical hardware, and nerve root injury, causing a longer hospitalization period [12–14]. Epidural bleeding is also a potential concern [12]. A retrospective study found that the most frequent intraoperative complication was dural tear, occurring in approximately 34% of cases, while the most common postoperative complication was hematoma, with an incidence of about 12%. In the late postoperative period, there is a substantial risk of construct failure, with or without loss of correction. Such events are relatively common in spinal surgery because of the complex biomechanics and kinematics of the spine [15].

Discussion

Lumbar fusion is the most common surgical option for discogenic pain or spinal instability unresponsive to conservative treatment [16]. Among spinal fusion techniques, the anterior approach is widely utilized because of its high success rates and relatively low complication profile, and is indicated for selected degenerative lumbar disorders, including discogenic or facet-mediated low back pain, neurogenic claudication, radiculopathy due to foraminal stenosis, and degenerative spinal deformities such as symptomatic spondylolisthesis and degenerative scoliosis. This approach is best suited for the L4/L5 and L5/S1 levels, where anterior access is generally safer and facilitates restoration of disc height and sagittal alignment. In contrast, its application at the L2/3 and L3/4 levels is limited due to the need for extensive peritoneal and renal mobilization and the rare but potential risk of superior mesenteric artery thrombosis. Contraindications to ALIF include extensive prior abdominal surgery with adhesions, unfavorable vascular anatomy, severe peripheral vascular disease, a solitary kidney on the side of exposure, active spinal infection, and high-grade (Grade $\geq$2) degenerative spondylolisthesis in the absence of posterior instrumentation. [9, 17]. One notable complication is postoperative subsidence, defined as a reduction in disc

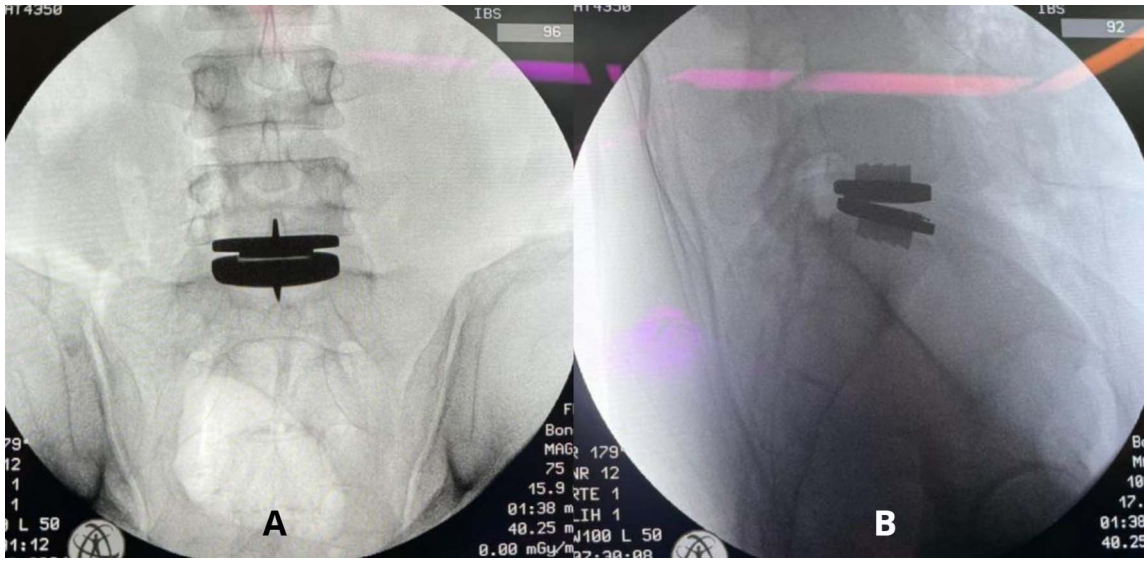

Figure 7. The interbody cage is positioned at the L5-S1 level as seen under fluoroscopic imaging.

Table 1. Pearls and pitfalls of en bloc discectomy via anterior lumbar approach.

Pearls	**Details**
Direct visualization of the disc and anterior pathology	The anterior approach provides direct access to both the disc space and any anterior intracanal pathology, facilitating better surgical precision
Complete nucleus removal	Complete removal of the nucleus offers a reduced risk of re-herniation compared to traditional microdiscectomy, ensuring long-term relief
Preserving subchondral bone with Cobb elevators	By positioning Cobb elevators parallel to the endplate, the attachment of the cartilage endplate can be carefully removed, preserving the critical subchondral bone for optimal bony integration with the implant.
Stability through peripheral annulus preservation	Preserving the peripheral annular rim (especially on the lateral side) enhances implant stability, minimizing the risk of displacement.
Larger implant placement for increased stability	The anterior approach allows for the placement of a larger cage or implant, contributing to better overall stability and reduced risk of implant migration
Pitfalls	
Steep learning curve for anterior approach	The anterior lumbar spine approach requires a steep learning curve, as it necessitates familiarity with the vascular structures in the area to avoid complications.
Risk of subchondral bone damage	Use of aggressive, non-parallel Cobb elevators may compromise the integrity of the subchondral bone, increasing the likelihood of implant subsidence or failure.
Implant misalignment and malposition	Incorrect alignment or positioning of the implant can lead to instability and may increase the likelihood of requiring revision surgery due to mechanical failure

height [18]. To avoid fusion-related drawbacks, lumbar total disc replacement (TDR) was introduced. TDR achieves pain relief through complete disc removal, restoration of physiological load transmission and sagittal alignment, preservation of motion, and may reduce adjacent-segment pathology [19]. However, TDR has also been associated with drawbacks, such as subsidence, dislocation, or malposition of the implant [20]. However, the anatomical structure of the vertebral body also influences the risk of subsidence. The peripheral endplate, or epiphyseal ring, is mechanically stronger than the central region. Therefore, implants with a larger footprint are preferred to distribute load across these stronger areas and reduce focal stress. By engaging the epiphyseal rings more effectively and occasionally interacting with pedicle screws as a mechanical stop, larger implants are associated with a lower incidence and severity of subsidence [21]. The clinical improvement and subsidence rates in different techniques are summarized in Table 2.

Preserving cartilaginous endplates is critical in lumbar fusion, as endplate violation significantly increases subsidence risk. Subsidence can lead to unintended fusion or TDR failure due to wear or implant displacement [32]. Kitzen et al. [16] reported parallel subsidence in 6.4% of patients. The en bloc discectomy technique offers a controlled method to remove the posterior disc, often the source of neural compression, while protecting the endplate. We applied this technique in three patients, all without complications.

Cage shape, size, and placement all affect subsidence risk. Larger-footprint ALIF cages reduce subsidence by distributing load more evenly across the endplate. Implant placement along the vertebral periphery is preferred because the central endplate is structurally weaker [4]; cadaveric studies confirm that

Table 2. Comparison of clinical outcomes and subsidence rates at final follow-up among various surgical techniques.

Author (Year)	Total of patients *n* (M/F)	Age (years ± SD)	Surgical technique	Follow-up (months)	Implant type	Subsidence rate (%)	Clinical outcome (mean ± SD)
Cuellar et al (2021) [22]	46 (N/A)	N/A	ALIF	72	ProDisc-L (Synthes Spine, Westchester, PA)	N/A	Improved ROM ODI TDR-1: 46% improvement TDR-2: 40% improvement TDR-3: 38.6% improvement VAS TDR-1: 53% improvement TDR-2: 58% improvement TDR-3: 55% improvement
Rao et al (2017) [23]	147 (103/44)	57.3 ± 13.6	ALIF	18	SynFix-LR PEEK integral (Depuy) for 89.1% of the patients	10.2%	VAS: 2.7 ± 0.2 ODI: 28.8 ± 1.8 SF-12 physical: 41.7 ± 0.9 SF-12 mental: 48.9 ± 1.0 Fusion rate: 91.2%
Chen et al (2019) [24]	107 (53/54)	60.79 ± 1.12	LLIF	24	PPEK cages	26.9%	VAS: 2.40 ± 0.32 JOA: 18.67 ± 0.46
Gionali et al (2024) [25]	61 (38/23)	39 ± 13.3	LLIF	35.5	Static (NuVasive CoRoent ® or Modulus ®), Static (J&J Synmesh ®), Expandable (Globus Medical ELSA ®)	27.8%	MacNab criteria: Excellent: 65.6% Good: 29.5% Fair: 4.9% Poor: 0
Chang et al (2019) [26]	169 (61/108)	67.7 10.9	OLIF	12	PEEK cages	62/168 (36.9%) 85/261 (32.6%)	ODI DS: 37.7 ± 13.5 SS: 34.4 ± 5.1 ST: 38.2 ± 15.2 DF: 55.0 ± 14.9 VAS DS: 2.4 ± 1.9 SS: 2.2 ± 1.6 ST: 2.0 ± 1.6 DF: 3.8 ± 1.6 SF-36 DS: 38.6 ± 7.6 SS: 39.0 ± 5.8 ST: 39.6 ± 7.4 DF: 30.9 ± 6.6 JOABPEQ All domains improved

(Continued on next page)

Table 2. (Continued)

Author (Year)	Total of patients *n* (M/F)	Age (years ± SD)	Surgical technique	Follow-up (months)	Implant type	Subsidence rate (%)	Clinical outcome (mean ± SD)
Wen et al (2020) [27]	74 (28/46)	BPS: 56.9 ± 13.2 UPS: 58.9 ± 16.1	OLIF	24 months	N/A	13/74 (17.6%)	VAS BPS: 2.97 ± 0.45 UPS: 2.73 ± 0.83 ODI BPS: 8.17 ± 1.74 UPS: 7.94 ± 1.62
Oh et al (2017) [28]	129 (52/87)	65.17 ± 8.599	PLIF	49.2	PEEK cage (O.I.C. cages; Stryker	15.8%	VAS: 2.89 ODI: 15.86 SF-36: 16.46
Park et al (2019) [29]	40 (11/29)	68.9 ± 7.9	PLIF	29.7	N/A	Low grade; 10/44 (22.7%) High grade; 4/44 (9.1%)	VAS:5.2 ± 2.1 ODI: 51.9 ± 16.1
Zhao et al (2020) [30]	76 (29/47)	53.91 ± 1.13	TLIF	60	PEEK material and cuboid shape (arched appearance) from Stry	Low grade: 11.8% High grade: 7.9%	VAS:2.21 ± 0.05 ODI: 10.34 ± 1.03 JOA: 20.79 ± 0.40
Kulkani et al (2024) [31]	36 (N/A)	42.16 ± 19.7	TLIF	48	N/A	N/A	VAS Group A: 0.19 Group B: 0.29 ODI Group A: 5 Group B: 5

Abbreviations: N/A, Non Available; M, male; F, female; ALIF, anterior lumbar interbody fusion; DF, deformity; DS, degenerative spondylolisthesis; SS, spondylolytic spondylolisthesis; ST, spinal stenosis; ROM, range of motion; BPS, bilateral pedicle screw; UPS, unilateral pedicle screw; LLIF, lateral lumbar interbody fusion; OLIF, oblique lumbar interbody fusion; PEEK, polyetheretherketone; PLIF, posterior lumbar interbody fusion; TDR-1, Total Disc Replacement 1 level; TDR-2, Total Disc Replacement 2 level; TDR-3, Total Disc Replacement 3 level; SF- 12, 12- Item Short Form Health Survey; TLIF, transverse lumbar interbody fusion; VAS, visual analog scale; SF- 36, 36- Item Short Form Health Survey; ODI, Oswestry Disability Index; JOABPEQ, Japan Orthopedic Association Back Pain Evaluation Questionnaire; JOA, Japan Orthopedic Association.

peripheral positioning helps prevent cage penetration regardless of design [33]. Taller cages increase subsidence risk due to over-distraction and higher endplate loading, whereas undersized cages may compromise decompression and fusion success [4].

Based on our earlier experience with conventional discectomy techniques, several technical limitations were consistently encountered. Disc removal performed in a piecemeal fashion often resulted in incomplete clearance of disc material, leading to concerns regarding the cleanliness of the disc space. Manual curettage frequently produced uneven endplate surfaces, with focal areas of excessive excavation adjacent to inadequately prepared regions. This nonuniform endplate preparation may compromise implant support and potentially increase the risk of subsidence.

In addition, the procedure required a longer operative time, particularly during endplate preparation using curettes. These accumulated technical challenges informed the transition to an en bloc discectomy technique, which aligns with the advantages observed in the present study. Based on our study and experience, en bloc discectomy provides a more controlled and systematic method of disc removal, thereby reducing procedural complexity and operative time. By enabling disc clearance in a single piece, this technique minimizes the likelihood of residual disc fragments while ensuring adequate decompression. Importantly, the focused removal of the cartilaginous disc en bloc reduces the need for aggressive curettage, facilitating more uniform endplate preparation and preserving vertebral endplate integrity. This standardized and reproducible approach allows for improved intraoperative assessment of endplate quality, which may enhance implant seating and contribute to a lower risk of implant subsidence.

The limitations of this technique include a significant learning curve, a heightened risk of endplate injury, and the possibility of incomplete discectomy. Because it requires a high level of precision, improper use of an osteotome or specialized curette may result in endplate fracture or damage. Furthermore, incomplete removal of the disc block can leave residual fragments, increasing the risk of re-herniation or persistent neural compression.

Conclusion

The en bloc discectomy is a promising technique for improving the outcomes of anterior lumbar fusion by focusing on precise and complete disc removal while preserving the endplates. This approach addresses the limitations of traditional piecemeal discectomy and aims to provide better long-term stability and reduce complications.

Funding

This research received no external funding.

Conflicts of interest

The authors declare no conflicts of interest.

Data availability statement

This article has no associated data generated and/or analyzed.

Author contribution statement

Author 1: Conceptualization, Methodology; Author 4–6: Writing original draft; Author 2,3: Visualization, Investigation; Author 3: Supervision; Author 1–6: Writing, Reviewing, and Editing.

Ethics approval

Ethical approval was not required.

Informed consent

Written informed consent was obtained from the patient depicted in the technique presentation.

References

1. De Kunder SL, Rijkers K, Caelers IJMH, et al. (2018) Lumbar interbody fusion: a historical overview and a future perspective. Spine (Phila Pa 1976) 43, 1161–1168.
2. Zhang B, Zhang C, Du Y, et al. (2025) Anterior lumbar discectomy and fusion: an effective technique in treating lumbar disc herniation – a retrospective case study. BMC Musculoskelet Disord 26, 20–25.
3. Dimar JR, Beck DJ, Glassman SD, et al. (2001) Posterior lumbar interbody cages do not augment segmental biomechanical stability. Am J Orthop (Belle Mead NJ) 30, 636–639.
4. Parisien A, Wai EK, Elsayed MSA, et al. (2022) Subsidence of spinal fusion cages: a systematic review. Int J Spine Surg 16, 1103–1118.
5. Calek AK, Cornaz F, Suter M, et al. (2024) Endplate weakening during cage bed preparation significantly reduces endplate load capacity. Eur Spine J 33, 2621–2629.
6. Zavras AG, Federico V, Nolte MT, et al. (2024) Risk factors for subsidence following anterior lumbar interbody fusion. Glob Spine J 14, 257–264.
7. Punt I, Van Rijsbergen M, Van Rietbergen B, et al. (2013) Subsidence of SB Charité total disc replacement and the role of undersizing. Eur Spine J 22, 2264–2270.
8. RJ Mobbs, K Phan, GK Thayaparan, PJ Rao (2016) Anterior lumbar interbody fusion as a salvage technique for pseudarthrosis following posterior lumbar fusion surgeryGlob spine J 16, 14–20.
9. Mobbs RJ, Phan K, Malham G, Seex K, Rao PJ (2015) Lumbar interbody fusion: techniques, indications and comparison of interbody fusion options including PLIF, TLIF, MI-TLIF, OLIF/ATP, LLIF and ALIF. J Spine Surg (Hong Kong) 1, 2–18.
10. Roy-Camille R, Saillant G, Mazel C, Monpierre H (1990) Precision of robotic guided instrumentation for acetabular component positioning. Organi Mov 5, 392–397.
11. Tomita K, Kawahara N, Baba H, Tsuchiya H, Fujita T, Toribatake Y (1997) Total en bloc spondylectomy. A new surgical technique for primary malignant vertebral tumors. Spine (Phila Pa 1976) 22, 324–333.
12. Boriani S (2018) En bloc resection in the spine: a procedure of surgical oncology. J spine Surg (Hong Kong) 4, 668–676.
13. Bandiera S, Boriani S, Donthineni R, Amendola L, Cappuccio M, Gasbarrini A (2009) Complications of en bloc resections in the spine. Orthop Clin North Am 40, 125–131.
14. Yokogawa N, Murakami H, Demura S, Kato S, Yoshioka K, Tsuchiya H (2018) Incidental durotomy during total en bloc spondylectomy. Spine J 18, 381–386.

15. Bandiera S, Noli LE, Griffoni C, et al. (2022) Complications and risk factors in en bloc resection of spinal tumors: a retrospective analysis on 298 patients treated in a single institution. Curr Oncol 29, 7842–7857.
16. Kitzen J, Verbiest V, Buil I, et al. (2020) Subsidence after total lumbar disc replacement is predictable and related to clinical outcome. Eur Spine J 29, 1544–1552.
17. K Phan, Thayaparan GK, MobbsRJ, (2015) Anterior lumbar interbody fusion versus transforaminal lumbar interbody fusion–systematic review and meta-analysis. Br J Neurosurg 29, 705–711.
18. Weiner BK, Fraser RD (1998) Spine update lumbar interbody cages. Spine (Phila Pa 1976) 23, 634–640.
19. Bai DY, Liang L, Zhang BB, et al. (2019) Total disc replacement versus fusion for lumbar degenerative diseases - a meta-analysis of randomized controlled trials. Medicine (Baltimore) 98, e16460.
20. Jacobs W, Van der Gaag NA, Tuschel A, et al. (2012) Total disc replacement for chronic back pain in the presence of disc degeneration. Cochrane Database Syst Rev 30, 1422–1478.
21. You KH, Cho SK, Hwang JY, et al. (2024) Effect of cage material and size on fusion rate and subsidence following biportal endoscopic transforaminal lumbar interbody fusion. Neurospine 21, 973–983.
22. Cuellar JM, Rasouli A, Lanman TH, Kanim L, Delamarter R (2021) Single and multilevel lumbar total disc replacement adjacent to L5–S1 ALIF (lumbar hybrid): 6 years of follow-up. Int J spine Surg 15, 971–977.
23. Rao PJ, Phan K, Giang G, Maharaj MM, Phan S, Mobbs RJ (2017) Subsidence following anterior lumbar interbody fusion (ALIF): a prospective study. J spine Surg (Hong Kong) 3, 168–175.
24. Chen E, Xu J, Yang S, Zhang Q, Yi H, Liang D, Lan S, Duan M, Wu Z (2019) Cage subsidence and fusion rate in extreme lateral interbody fusion with and without fixation. World Neurosurg 122, 969–977.
25. Gianoli D, Bättig L, Bertulli L, Forster T, Martens B, Stienen MN (2024) Lateral lumbar and thoracic interbody fusion (LLIF) for thoracolumbar spine trauma (Trauma LLIF): a single-center, retrospective observational cohort study. North Am Spine Soc J 59, 412–449.
26. Chang SY, Nam Y, Lee J, Chang BS, Lee CK, Kim H (2019) Impact of preoperative diagnosis on clinical outcomes of oblique lateral interbody fusion for lumbar degenerative disease in a single-institution prospective cohort. Orthop Surg 11, 66–74.
27. Wen J, Shi C, Yu L, Wang S, Xi Y, Ye X (2020) Unilateral versus bilateral percutaneous pedicle screw fixation in oblique lumbar interbody fusion. World Neurosurg 134, 920–927.
28. Oh KW, Lee JH, Lee JH, Lee DY, Shim HJ (2017) The correlation between cage subsidence, bone mineral density, and clinical results in posterior lumbar interbody fusionClin Spine Surg. 2017 30, 683–689.
29. Park HY, Kim YH, Ha KY, Kim S Il, Min HK, Oh IS, Seo JY, Chang DG, Park JT (2019) Minimally invasive lateral lumbar interbody fusion for clinical adjacent segment pathology: a comparative study with conventional posterior lumbar interbody fusion. Clin spine Surg 32, 426–433.
30. Zhao Y, Jia J, Liu W, Chen X, Mai R, Tian Y, Zhao J, Liu X (2020) Influence of contoured versus straight rod on clinical outcomes and sagittal parameters in minimally invasive transforaminal lumbar interbody fusion (MIS-TLIF) at L4/5 level-more than 5 years follow-up. J Orthop Sci 25, 89–95.
31. Kulkarni AG, Kumar P, Umarani A, Patil S, Chodavadiya S (2025) Minimally invasive transforaminal interbody fusion for high-grade spondylolisthesis: a retrospective study analysis of a tailor-made solution. Asian Spine J 19, 10–20.
32. Punt IM, Visser VM, Van Rhijn LW (2008) Complications and reoperations of the SB Charité lumbar disc prosthesis: experience in 75 patients. Eur Spine J 17, 36–43.
33. Briski DC, Goel Q, Waddell BS (2017) Does spanning a lateral lumbar interbody cage across the vertebral ring apophysis increase loads required for failure and mitigate endplate violation. Spine (Phila Pa 1976) 42, 1158–1164.

Cite this article as: Mahadhipta H, Muhyi A, Harist Fadhlizain MA, Mitchel M, Gani KS & Kholinne E (2026) En bloc discectomy via anterior lumbar approach: a technical note. SICOT-J **12**, 19. https://doi.org/10.1051/sicotj/2026002.

4. Turn it in En Bloc

by Erika FK

Submission date: 11-Aug-2026 09:22AM (UTC+0700)
Submission ID: 2652995823
File name: oc_discectomy_via_anterior_lumbar_approach-_a_technical_note.pdf (1.01M)
Word count: 4658
Character count: 25801

4. Turn it in En Bloc

ORIGINALITY REPORT

9%	8%	7%	5%
SIMILARITY INDEX	INTERNET SOURCES	PUBLICATIONS	STUDENT PAPERS

MATCH ALL SOURCES (ONLY SELECTED SOURCE PRINTED)

2%

★ mdpi-res.com

Internet Source

Exclude quotes	On	Exclude matches	< 15 words
Exclude bibliography	On		

SICOT-J 2026, **12**, 19
© The Authors, published by EDP Sciences, 2026
https://doi.org/10.1051/sicotj/2026002

SICOT-J

Available online at:
www.sicot-j.org

SURGICAL TECHNIQUE

OPEN ACCESS

En bloc discectomy via anterior lumbar approach: a technical note

Harmantya Mahadhipta[1,2,3], Amri Muhyi[1], Muhamad Abdul Harist Fadhlizain[4], Mitchel Mitchel[3], Karina Sylvana Gani[3], and Erica Kholinne[3,5,*]

[1] Department of Orthopaedics and Traumatology, Tangerang General Hospital, Banten 15117, Indonesia
[2] Department of Orthopaedics and Traumatology, Cipto Mangunkusumo Hospital, Faculty of Medicine, Universitas Indonesia, Jakarta 10430, Indonesia
[3] Orthopedics and Traumatology, Gatam Institute, Eka Hospital, Tangerang 15321, Indonesia
[4] General Practitioner of Tangerang General Hospital, Banten 15117, Indonesia
[5] Department of Surgery, Faculty of Medicine, Universitas Trisakti, Jakarta 11440, Indonesia

Received 18 December 2025, Accepted 26 January 2026, Published online 20 April 2026

Abstract – *Introduction:* Implant subsidence remains one of the complications following lumbar interbody fusion and total lumbar disc replacement, often attributed to excessive and uneven preparation of the subchondral bone. To address this limitation, we describe a novel surgical approach – en bloc discectomy – designed to enable more controlled disc removal, preserve subchondral endplate integrity, and minimize the risk of implant subsidence. *Methods:* We describe the procedural steps for the en bloc discectomy, including patient positioning, surgical approach, and the specific technique using a Cobb spinal elevator to remove the cartilaginous en bloc. The technique's advantages include controlled disc removal, minimized subsidence, and even subchondral endplate preparation. *Results:* En bloc discectomy was successfully performed in our patient. No intraoperative or postoperative complications occurred, and all patients reported immediate and sustained symptomatic improvement. *Conclusion*: En bloc discectomy provides a safe and reproducible alternative to conventional (standard piecemeal discectomy) disc excision. By reducing endplate damage and implant subsidence, this technique has the potential to improve long-term stability and clinical outcomes in patients undergoing lumbar interbody procedures.

Key words: Lumbar vertebrae, Intervertebral disc displacement, Discectomy, Total disc replacement, Implant subsidence.

Introduction

Lumbar disc herniation and degenerative disc disease are major causes of low back pain and radiculopathy, often requiring surgery when conservative treatment fails [1]. Anterior lumbar interbody fusion (ALIF) is commonly performed because it provides direct disc access and restores disc height and alignment with limited posterior disruption [2]. However, implant subsidence, sinking of the interbody device into the endplate, remains a significant complication. Lumbar Disc Replacement (LDR) offers better stabilization and has been associated with lower subsidence rates than ALIF [3]. Reported subsidence rates for ALIF range from 6% to 23%, whereas Richard et al. documented a 3.4% rate for LDR. Subsidence may compromise fusion stability, reduce lordosis, cause recurrent symptoms, and necessitate revision surgery [4].

Successful lumbar interbody implantation via the anterior approach requires balancing two opposing goals: removing disc material to prepare a fusion bed while preserving endplate integrity for load-bearing. Conventional piecemeal discectomy can leave residual cartilage, is difficult to standardize, and risks damaging the subchondral bone [1, 2]. Excessive endplate removal weakens axial strength; one biomechanical study showed failure load reductions of 15% in TLIF and 36.6% in PLIF after aggressive preparation [5]. In ALIF, subsidence has been associated with over-preparation, cage–endplate mismatch, and suboptimal cage positioning [6], yet the ideal extent of endplate removal remains unclear. Similarly, size mismatch in lumbar disc replacement can cause the implant to rest on weaker central bone rather than the stronger peripheral ring, increasing subsidence risk [7]. Therefore, a more reproducible and endplate-preserving disc removal technique is needed.

To address these challenges, we introduce a novel en bloc discectomy technique for the anterior lumbar approach. Using

*Corresponding author: erica@trisakti.ac.id

This is an Open Access article distributed under the terms of the Creative Commons Attribution License (https://creativecommons.org/licenses/by/4.0), which permits unrestricted use, distribution, and reproduction in any medium, provided the original work is properly cited.

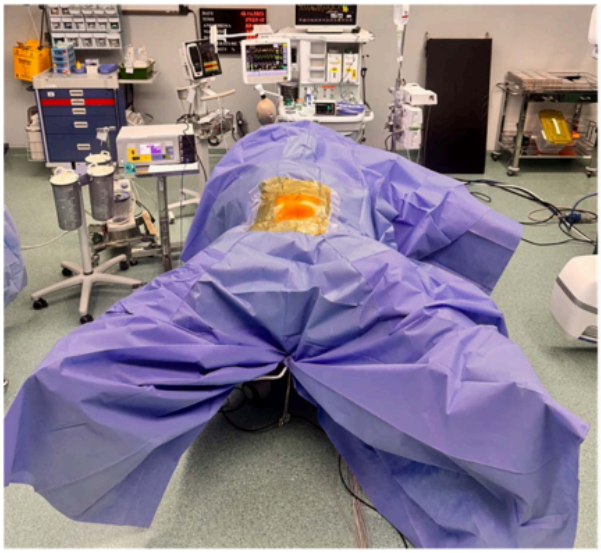

Figure 1. Patient was positioned in supine Da Vinci under sterile operative procedure.

a Cobb spinal elevator, this method enables controlled, systematic removal of the cartilaginous disc while minimizing endplate trauma. This technical note outlines the key procedural steps and presents illustrative clinical cases. Our goal is to provide a reproducible technique that achieves adequate disc clearance and may help reduce implant subsidence in anterior lumbar interbody procedures.

Surgical technique

Standard surgical instruments were utilized, including a Cobb elevator for disc space preparation, electrocautery for soft tissue management, and forceps for tissue handling. A third-generation total disc replacement implant, ProDisc®-L (Synthes Spine, West Chester, PA), was implanted following discectomy and endplate preparation, with attention to appropriate sizing and positioning based on preoperative planning.

Anesthesia, patient position, and incision

All procedures were performed under general anesthesia. The patient was positioned supine in the Da Vinci position on the operating table and prepared in a standard sterile fashion (Figure 1). The surgeon stood on the caudal side of the patient. The surgical exposure is achieved through a midline or paramedian incision at all lumbar levels, or a mini-Pfannenstiel incision at the L5/S1 level, utilizing a retroperitoneal approach with vascular mobilization and dissection. This approach offers several advantages, including direct midline visualization of the disc space and broad lateral exposure of the vertebral bodies, enabling efficient disc removal and rapid endplate preparation [8]. In addition, anterior access permits the use of larger interbody implants with increased surface area, facilitating more effective correction of spinal pathology. Preservation of the posterior spinal musculature and anterolateral psoas muscles may

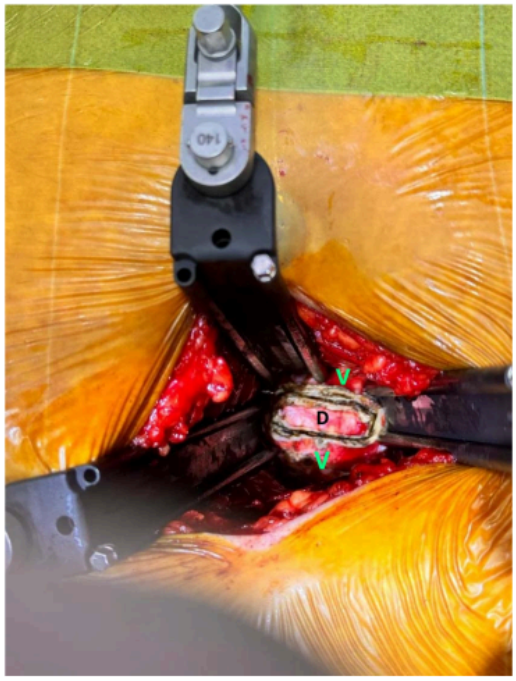

Figure 2. The anterior part of the targeted disc was cauterized into a rectangular shape. "V" represent as vertebral body, and "D" represent as disc.

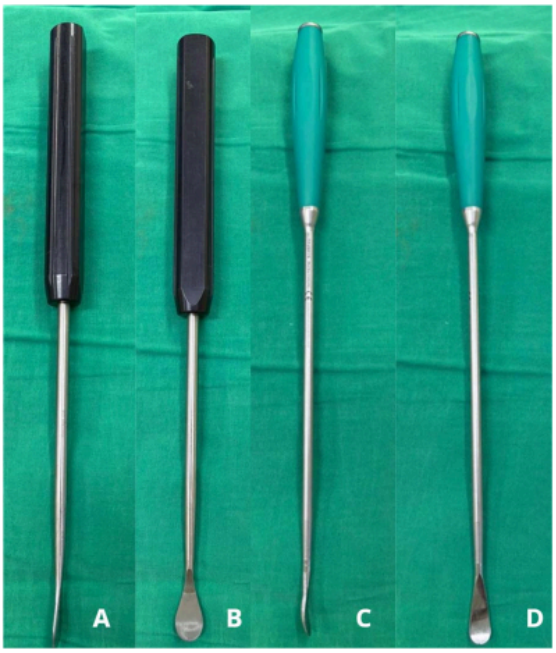

Figure 3. Cobb elevator (A&B) flat head (C&D) curve head.

also contribute to reduced postoperative pain and functional impairment [9]. We then cauterized the anterior longitudinal ligament and the anterior portion of the disc, creating a rectangular window. Intraoperative fluoroscopy was used to confirm the target disc level.

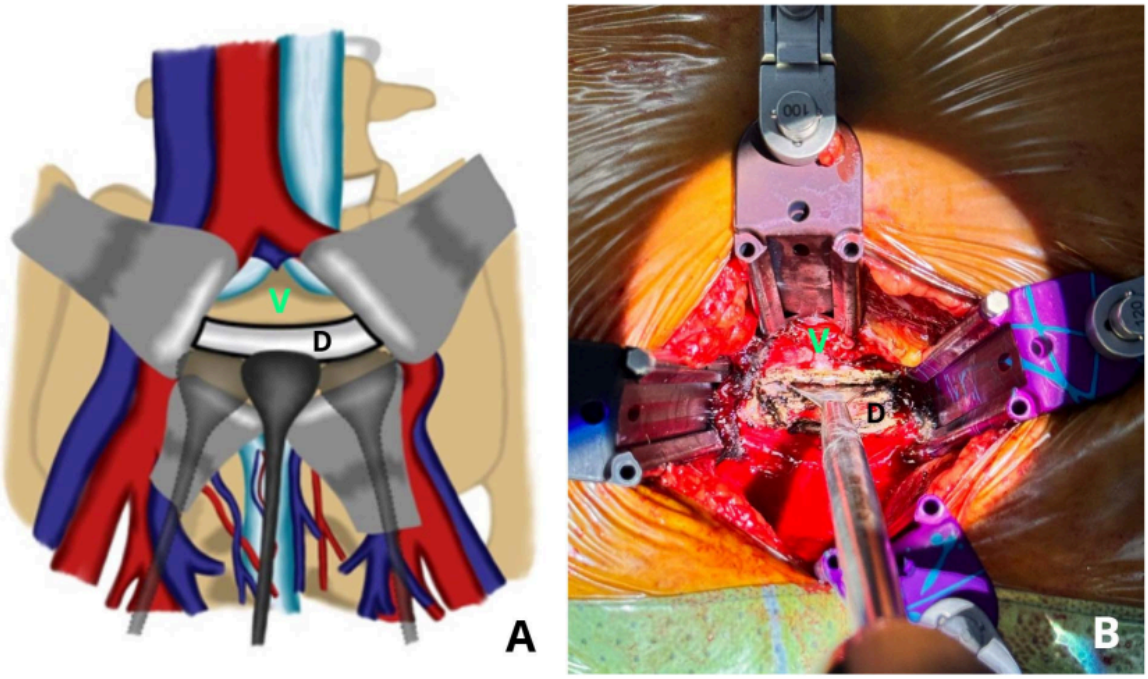

Figure 4. (A) Illustrative images. (B) Intraoperative images showing detachment of the superior and inferior parts of the nucleus pulposus from the posterior annulus using a flat head Cobb elevator, by "sweep and lift" technique. "V" represent as vertebral body, and "D" represent as disc.

Identification of disc–endplate borders

Following exposure, the anterior annulus fibrosus was incised longitudinally with an electrocautery/diathermy. The incision was made large enough to allow adequate visualization and working access while preserving the peripheral annular fibers to maintain stability. The anatomical borders of the working zone were then carefully identified, the superior and inferior limits were defined at the annulus-endplate junction, while the lateral borders were established approximately 1cm medial to the lateral edge of the disc, corresponding to the annulus-nucleus junction (Figure 2).

Dissection planes were then carefully developed superiorly and inferiorly between the vertebral endplates and the intervertebral disc. We are using two types of Cobb elevators: a flat-head for the superior and inferior portions, and a curved head for the lateral portion of the nucleus (Figure 3). Using a flat-head Cobb elevator, the cartilaginous endplate was elevated from the subchondral bone by the "sweep and lift technique" from the superior and inferior cartilage endplate. The lateral portion of the nucleus pulposus was detached from the lateral annulus using a curved head Cobb elevator by the "scooping technique" (Figures 4 and 5). Removal of the disc en bloc, which consists of the anterior annulus and the whole nucleus pulposus.

En bloc discectomy

The posterior annulus was removed using a Kerrison punch to ensure canal decompression. Disc material was removed centrally while carefully preserving the peripheral subchondral bone and ring apophysis to maintain load-bearing capacity and reduce the risk of cage subsidence. Any residual fragments were cleared with pituitary rongeurs or curettes as needed. The excised disc (Figure 6) was measured to guide cage sizing. Sequential trial implants were then inserted to assess disc height restoration, footprint coverage, and sagittal alignment, with care taken to avoid over-distraction and potential endplate injury.

The appropriately sized interbody device was inserted into the prepared disc space under fluoroscopic guidance. The device was positioned centrally to maximize contact with the peripheral ring apophysis, thereby optimizing axial load distribution and construct stability. Final placement and alignment were confirmed with anteroposterior and lateral fluoroscopic imaging (Figure 7).

After meticulous hemostasis, retractors were released, and the retroperitoneal contents were allowed to return to their anatomical position. A layered closure was performed, beginning with the fascia, followed by the subcutaneous tissue and skin. We have summarized a key surgical step and potential pitfalls in En Bloc Discectomy via Anterior Lumbar Approach (Table 1).

Potential complication and risks

En bloc resection is a surgical method designed to excise pathological tissue in one intact piece to obtain clear margins and minimize the likelihood of residual disease. However, despite its oncologic and biomechanical benefits, this technique is technically challenging and carries a greater risk of complications than piecemeal resection [10, 11]. En bloc resection necessitates the removal not only of the involved bone but also of

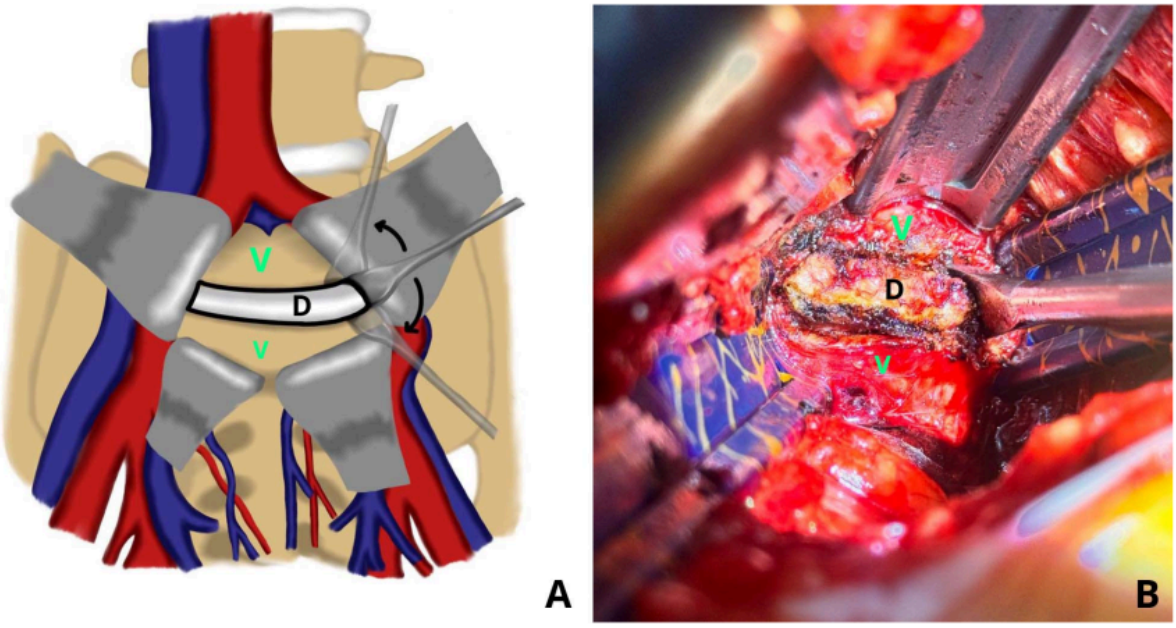

Figure 5. (A) Illustrative image. (B) Intraoperative images of the lateral detachment from the lateral annulus using a curved head Cobb elevator, by the "scooping" technique. "V" represent as vertebral body, and "D" represent as disc.

Figure 6. The excised disc fragment.

most of the surrounding stabilizing structures, resulting in complete spinal instability [12]. With the en bloc discectomy approach, common intraoperative complications include dural tears that will lead to cerebrospinal fluid (CSF) leakage, visceral and vascular injuries, malpositioning of surgical hardware, and nerve root injury, causing a longer hospitalization period [12–14]. Epidural bleeding is also a potential concern [12]. A retrospective study found that the most frequent intraoperative complication was dural tear, occurring in approximately 34% of cases, while the most common postoperative complication was hematoma, with an incidence of about 12%. In the late postoperative period, there is a substantial risk of construct failure, with or without loss of correction. Such events are relatively common in spinal surgery because of the complex biomechanics and kinematics of the spine [15].

Discussion

Lumbar fusion is the most common surgical option for discogenic pain or spinal instability unresponsive to conservative treatment [16]. Among spinal fusion techniques, the anterior approach is widely utilized because of its high success rates and relatively low complication profile, and is indicated for selected degenerative lumbar disorders, including discogenic or facet-mediated low back pain, neurogenic claudication, radiculopathy due to foraminal stenosis, and degenerative spinal deformities such as symptomatic spondylolisthesis and degenerative scoliosis. This approach is best suited for the L4/L5 and L5/S1 levels, where anterior access is generally safer and facilitates restoration of disc height and sagittal alignment. In contrast, its application at the L2/3 and L3/4 levels is limited due to the need for extensive peritoneal and renal mobilization and the rare but potential risk of superior mesenteric artery thrombosis. Contraindications to ALIF include extensive prior abdominal surgery with adhesions, unfavorable vascular anatomy, severe peripheral vascular disease, a solitary kidney on the side of exposure, active spinal infection, and high-grade (Grade $\geq$2) degenerative spondylolisthesis in the absence of posterior instrumentation. [9, 17]. One notable complication is postoperative subsidence, defined as a reduction in disc

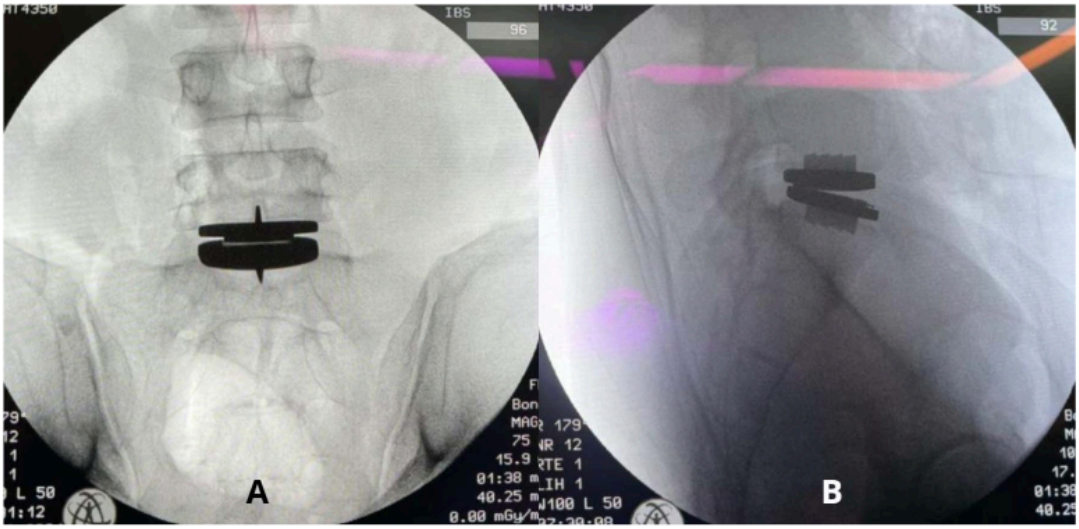

Figure 7. The interbody cage is positioned at the L5-S1 level as seen under fluoroscopic imaging.

Table 1. Pearls and pitfalls of en bloc discectomy via anterior lumbar approach.

Pearls	**Details**
Direct visualization of the disc and anterior pathology	The anterior approach provides direct access to both the disc space and any anterior intracanal pathology, facilitating better surgical precision
Complete nucleus removal	Complete removal of the nucleus offers a reduced risk of re-herniation compared to traditional microdiscectomy, ensuring long-term relief
Preserving subchondral bone with Cobb elevators	By positioning Cobb elevators parallel to the endplate, the attachment of the cartilage endplate can be carefully removed, preserving the critical subchondral bone for optimal bony integration with the implant.
Stability through peripheral annulus preservation	Preserving the peripheral annular rim (especially on the lateral side) enhances implant stability, minimizing the risk of displacement.
Larger implant placement for increased stability	The anterior approach allows for the placement of a larger cage or implant, contributing to better overall stability and reduced risk of implant migration
Pitfalls	
Steep learning curve for anterior approach	The anterior lumbar spine approach requires a steep learning curve, as it necessitates familiarity with the vascular structures in the area to avoid complications.
Risk of subchondral bone damage	Use of aggressive, non-parallel Cobb elevators may compromise the integrity of the subchondral bone, increasing the likelihood of implant subsidence or failure.
Implant misalignment and malposition	Incorrect alignment or positioning of the implant can lead to instability and may increase the likelihood of requiring revision surgery due to mechanical failure

height [18]. To avoid fusion-related drawbacks, lumbar total disc replacement (TDR) was introduced. TDR achieves pain relief through complete disc removal, restoration of physiological load transmission and sagittal alignment, preservation of motion, and may reduce adjacent-segment pathology [19]. However, TDR has also been associated with drawbacks, such as subsidence, dislocation, or malposition of the implant [20]. However, the anatomical structure of the vertebral body also influences the risk of subsidence. The peripheral endplate, or epiphyseal ring, is mechanically stronger than the central region. Therefore, implants with a larger footprint are preferred to distribute load across these stronger areas and reduce focal stress. By engaging the epiphyseal rings more effectively and occasionally interacting with pedicle screws as a mechanical stop, larger implants are associated with a lower incidence and severity of subsidence [21]. The clinical improvement and subsidence rates in different techniques are summarized in Table 2.

Preserving cartilaginous endplates is critical in lumbar fusion, as endplate violation significantly increases subsidence risk. Subsidence can lead to unintended fusion or TDR failure due to wear or implant displacement [32]. Kitzen et al. [16] reported parallel subsidence in 6.4% of patients. The en bloc discectomy technique offers a controlled method to remove the posterior disc, often the source of neural compression, while protecting the endplate. We applied this technique in three patients, all without complications.

Cage shape, size, and placement all affect subsidence risk. Larger-footprint ALIF cages reduce subsidence by distributing load more evenly across the endplate. Implant placement along the vertebral periphery is preferred because the central endplate is structurally weaker [4]; cadaveric studies confirm that

Table 2. Comparison of clinical outcomes and subsidence rates at final follow-up among various surgical techniques.

Author (Year)	Total of patients *n* (M/F)	Age (years ± SD)	Surgical technique	Follow-up (months)	Implant type	Subsidence rate (%)	Clinical outcome (mean ± SD)
Cuellar et al (2021) [22]	46 (N/A)	N/A	ALIF	72	ProDisc-L (Synthes Spine, Westchester, PA)	N/A	Improved ROM ODI TDR-1: 46% improvement TDR-2: 40% improvement TDR-3: 38.6% improvement VAS TDR-1: 53% improvement TDR-2: 58% improvement TDR-3: 55% improvement
Rao et al (2017) [23]	147 (103/44)	57.3 ± 13.6	ALIF	18	SynFix-LR PEEK integral (Depuy) for 89.1% of the patients	10.2%	VAS: 2.7 ± 0.2 ODI: 28.8 ± 1.8 SF-12 physical: 41.7 ± 0.9 SF-12 mental: 48.9 ± 1.0 Fusion rate: 91.2%
Chen et al (2019) [24]	107 (53/54)	60.79 ± 1.12	LLIF	24	PPEK cages	26.9%	VAS: 2.40 ± 0.32 JOA: 18.67 ± 0.46
Gionali et al (2024) [25]	61 (38/23)	39 ± 13.3	LLIF	35.5	Static (NuVasive CoRoent ® or Modulus ®), Static (J&J Synmesh ®), Expandable (Globus Medical ELSA ®)	27.8%	MacNab criteria: Excellent: 65.6% Good: 29.5% Fair: 4.9% Poor: 0
Chang et al (2019) [26]	169 (61/108)	67.7 10.9	OLIF	12	PEEK cages	62/168 (36.9%) 85/261 (32.6%)	ODI DS: 37.7 ± 13.5 SS: 34.4 ± 5.1 ST: 38.2 ± 15.2 DF: 55.0 ± 14.9 VAS DS: 2.4 ± 1.9 SS: 2.2 ± 1.6 ST: 2.0 ± 1.6 DF: 3.8 ± 1.6 SF-36 DS: 38.6 ± 7.6 SS: 39.0 ± 5.8 ST: 39.6 ± 7.4 DF: 30.9 ± 6.6 JOABPEQ All domains improved

(Continued on next page)

Table 2. (Continued)

Author (Year)	Total of patients *n* (M/F)	Age (years ± SD)	Surgical technique	Follow-up (months)	Implant type	Subsidence rate (%)	Clinical outcome (mean ± SD)
Wen et al (2020) [27]	74 (28/46)	BPS: 56.9 ± 13.2 UPS: 58.9 ± 16.1	OLIF	24 months	N/A	13/74 (17.6%)	VAS BPS: 2.97 ± 0.45 UPS: 2.73 ± 0.83 ODI BPS: 8.17 ± 1.74 UPS: 7.94 ± 1.62
Oh et al (2017) [28]	129 (52/87)	65.17 ± 8.599	PLIF	49.2	PEEK cage (O.I.C. cages; Stryker	15.8%	VAS: 2.89 ODI: 15.86 SF-36: 16.46
Park et al (2019) [29]	40 (11/29)	68.9 ± 7.9	PLIF	29.7	N/A	Low grade; 10/44 (22.7%) High grade; 4/44 (9.1%)	VAS:5.2 ± 2.1 ODI: 51.9 ± 16.1
Zhao et al (2020) [30]	76 (29/47)	53.91 ± 1.13	TLIF	60	PEEK material and cuboid shape (arched appearance) from Stry	Low grade: 11.8% High grade: 7.9%	VAS:2.21 ± 0.05 ODI: 10.34 ± 1.03 JOA: 20.79 ± 0.40
Kulkani et al (2024) [31]	36 (N/A)	42.16 ± 19.7	TLIF	48	N/A	N/A	VAS Group A: 0.19 Group B: 0.29 ODI Group A: 5 Group B: 5

Abbreviations: N/A, Non Available; M, male; F, female; ALIF, anterior lumbar interbody fusion; DF, deformity; DS, degenerative spondylolisthesis; SS, spondylolytic spondylolisthesis; ST, spinal stenosis; ROM, range of motion; BPS, bilateral pedicle screw; UPS, unilateral pedicle screw; LLIF, lateral lumbar interbody fusion; OLIF, oblique lumbar interbody fusion; PEEK, polyetheretherketone; PLIF, posterior lumbar interbody fusion; TDR-1, Total Disc Replacement 1 level; TDR-2, Total Disc Replacement 2 level; TDR-3, Total Disc Replacement 3 level; SF- 12, 12- Item Short Form Health Survey; TLIF, transverse lumbar interbody fusion; VAS, visual analog scale; SF- 36, 36- Item Short Form Health Survey; ODI, Oswestry Disability Index; JOABPEQ, Japan Orthopedic Association Back Pain Evaluation Questionnaire; JOA, Japan Orthopedic Association.

peripheral positioning helps prevent cage penetration regardless of design [33]. Taller cages increase subsidence risk due to over-distraction and higher endplate loading, whereas undersized cages may compromise decompression and fusion success [4].

Based on our earlier experience with conventional discectomy techniques, several technical limitations were consistently encountered. Disc removal performed in a piecemeal fashion often resulted in incomplete clearance of disc material, leading to concerns regarding the cleanliness of the disc space. Manual curettage frequently produced uneven endplate surfaces, with focal areas of excessive excavation adjacent to inadequately prepared regions. This nonuniform endplate preparation may compromise implant support and potentially increase the risk of subsidence.

In addition, the procedure required a longer operative time, particularly during endplate preparation using curettes. These accumulated technical challenges informed the transition to an en bloc discectomy technique, which aligns with the advantages observed in the present study. Based on our study and experience, en bloc discectomy provides a more controlled and systematic method of disc removal, thereby reducing procedural complexity and operative time. By enabling disc clearance in a single piece, this technique minimizes the likelihood of residual disc fragments while ensuring adequate decompression. Importantly, the focused removal of the cartilaginous disc en bloc reduces the need for aggressive curettage, facilitating more uniform endplate preparation and preserving vertebral endplate integrity. This standardized and reproducible approach allows for improved intraoperative assessment of endplate quality, which may enhance implant seating and contribute to a lower risk of implant subsidence.

The limitations of this technique include a significant learning curve, a heightened risk of endplate injury, and the possibility of incomplete discectomy. Because it requires a high level of precision, improper use of an osteotome or specialized curette may result in endplate fracture or damage. Furthermore, incomplete removal of the disc block can leave residual fragments, increasing the risk of re-herniation or persistent neural compression.

Conclusion

The en bloc discectomy is a promising technique for improving the outcomes of anterior lumbar fusion by focusing on precise and complete disc removal while preserving the endplates. This approach addresses the limitations of traditional piecemeal discectomy and aims to provide better long-term stability and reduce complications.

Funding

This research received no external funding.

Conflicts of interest

The authors declare no conflicts of interest.

Data availability statement

This article has no associated data generated and/or analyzed.

Author contribution statement

Author 1: Conceptualization, Methodology; Author 4–6: Writing original draft; Author 2,3: Visualization, Investigation; Author 3: Supervision; Author 1–6: Writing, Reviewing, and Editing.

Ethics approval

Ethical approval was not required.

Informed consent

Written informed consent was obtained from the patient depicted in the technique presentation.

References

1. De Kunder SL, Rijkers K, Caelers IJMH, et al. (2018) Lumbar interbody fusion: a historical overview and a future perspective. Spine (Phila Pa 1976) 43, 1161–1168.
2. Zhang B, Zhang C, Du Y, et al. (2025) Anterior lumbar discectomy and fusion: an effective technique in treating lumbar disc herniation – a retrospective case study. BMC Musculoskelet Disord 26, 20–25.
3. Dimar JR, Beck DJ, Glassman SD, et al. (2001) Posterior lumbar interbody cages do not augment segmental biomechanical stability. Am J Orthop (Belle Mead NJ) 30, 636–639.
4. Parisien A, Wai EK, Elsayed MSA, et al. (2022) Subsidence of spinal fusion cages: a systematic review. Int J Spine Surg 16, 1103–1118.
5. Calek AK, Cornaz F, Suter M, et al. (2024) Endplate weakening during cage bed preparation significantly reduces endplate load capacity. Eur Spine J 33, 2621–2629.
6. Zavras AG, Federico V, Nolte MT, et al. (2024) Risk factors for subsidence following anterior lumbar interbody fusion. Glob Spine J 14, 257–264.
7. Punt I, Van Rijsbergen M, Van Rietbergen B, et al. (2013) Subsidence of SB Charité total disc replacement and the role of undersizing. Eur Spine J 22, 2264–2270.
8. RJ Mobbs, K Phan, GK Thayaparan, PJ Rao (2016) Anterior lumbar interbody fusion as a salvage technique for pseudarthrosis following posterior lumbar fusion surgeryGlob spine J 16, 14–20.
9. Mobbs RJ, Phan K, Malham G, Seex K, Rao PJ (2015) Lumbar interbody fusion: techniques, indications and comparison of interbody fusion options including PLIF, TLIF, MI-TLIF, OLIF/ATP, LLIF and ALIF. J Spine Surg (Hong Kong) 1, 2–18.
10. Roy-Camille R, Saillant G, Mazel C, Monpierre H (1990) Precision of robotic guided instrumentation for acetabular component positioning. Organi Mov 5, 392–397.
11. Tomita K, Kawahara N, Baba H, Tsuchiya H, Fujita T, Toribatake Y (1997) Total en bloc spondylectomy. A new surgical technique for primary malignant vertebral tumors. Spine (Phila Pa 1976) 22, 324–333.
12. Boriani S (2018) En bloc resection in the spine: a procedure of surgical oncology. J spine Surg (Hong Kong) 4, 668–676.
13. Bandiera S, Boriani S, Donthineni R, Amendola L, Cappuccio M, Gasbarrini A (2009) Complications of en bloc resections in the spine. Orthop Clin North Am 40, 125–131.
14. Yokogawa N, Murakami H, Demura S, Kato S, Yoshioka K, Tsuchiya H (2018) Incidental durotomy during total en bloc spondylectomy. Spine J 18, 381–386.

15. Bandiera S, Noli LE, Griffoni C, et al. (2022) Complications and risk factors in en bloc resection of spinal tumors: a retrospective analysis on 298 patients treated in a single institution. Curr Oncol 29, 7842–7857.
16. Kitzen J, Verbiest V, Buil I, et al. (2020) Subsidence after total lumbar disc replacement is predictable and related to clinical outcome. Eur Spine J 29, 1544–1552.
17. K Phan, Thayaparan GK, MobbsRJ, (2015) Anterior lumbar interbody fusion versus transforaminal lumbar interbody fusion–systematic review and meta-analysis. Br J Neurosurg 29, 705–711.
18. Weiner BK, Fraser RD (1998) Spine update lumbar interbody cages. Spine (Phila Pa 1976) 23, 634–640.
19. Bai DY, Liang L, Zhang BB, et al. (2019) Total disc replacement versus fusion for lumbar degenerative diseases - a meta-analysis of randomized controlled trials. Medicine (Baltimore) 98, e16460.
20. Jacobs W, Van der Gaag NA, Tuschel A, et al. (2012) Total disc replacement for chronic back pain in the presence of disc degeneration. Cochrane Database Syst Rev 30, 1422–1478.
21. You KH, Cho SK, Hwang JY, et al. (2024) Effect of cage material and size on fusion rate and subsidence following biportal endoscopic transforaminal lumbar interbody fusion. Neurospine 21, 973–983.
22. Cuellar JM, Rasouli A, Lanman TH, Kanim L, Delamarter R (2021) Single and multilevel lumbar total disc replacement adjacent to L5–S1 ALIF (lumbar hybrid): 6 years of follow-up. Int J spine Surg 15, 971–977.
23. Rao PJ, Phan K, Giang G, Maharaj MM, Phan S, Mobbs RJ (2017) Subsidence following anterior lumbar interbody fusion (ALIF): a prospective study. J spine Surg (Hong Kong) 3, 168–175.
24. Chen E, Xu J, Yang S, Zhang Q, Yi H, Liang D, Lan S, Duan M, Wu Z (2019) Cage subsidence and fusion rate in extreme lateral interbody fusion with and without fixation. World Neurosurg 122, 969–977.
25. Gianoli D, Bättig L, Bertulli L, Forster T, Martens B, Stienen MN (2024) Lateral lumbar and thoracic interbody fusion (LLIF) for thoracolumbar spine trauma (Trauma LLIF): a single-center, retrospective observational cohort study. North Am Spine Soc J 59, 412–449.
26. Chang SY, Nam Y, Lee J, Chang BS, Lee CK, Kim H (2019) Impact of preoperative diagnosis on clinical outcomes of oblique lateral interbody fusion for lumbar degenerative disease in a single-institution prospective cohort. Orthop Surg 11, 66–74.
27. Wen J, Shi C, Yu L, Wang S, Xi Y, Ye X (2020) Unilateral versus bilateral percutaneous pedicle screw fixation in oblique lumbar interbody fusion. World Neurosurg 134, 920–927.
28. Oh KW, Lee JH, Lee JH, Lee DY, Shim HJ (2017) The correlation between cage subsidence, bone mineral density, and clinical results in posterior lumbar interbody fusionClin Spine Surg. 2017 30, 683–689.
29. Park HY, Kim YH, Ha KY, Kim S Il, Min HK, Oh IS, Seo JY, Chang DG, Park JT (2019) Minimally invasive lateral lumbar interbody fusion for clinical adjacent segment pathology: a comparative study with conventional posterior lumbar interbody fusion. Clin spine Surg 32, 426–433.
30. Zhao Y, Jia J, Liu W, Chen X, Mai R, Tian Y, Zhao J, Liu X (2020) Influence of contoured versus straight rod on clinical outcomes and sagittal parameters in minimally invasive transforaminal lumbar interbody fusion (MIS-TLIF) at L4/5 level-more than 5 years follow-up. J Orthop Sci 25, 89–95.
31. Kulkarni AG, Kumar P, Umarani A, Patil S, Chodavadiya S (2025) Minimally invasive transforaminal interbody fusion for high-grade spondylolisthesis: a retrospective study analysis of a tailor-made solution. Asian Spine J 19, 10–20.
32. Punt IM, Visser VM, Van Rhijn LW (2008) Complications and reoperations of the SB Charité lumbar disc prosthesis: experience in 75 patients. Eur Spine J 17, 36–43.
33. Briski DC, Goel Q, Waddell BS (2017) Does spanning a lateral lumbar interbody cage across the vertebral ring apophysis increase loads required for failure and mitigate endplate violation. Spine (Phila Pa 1976) 42, 1158–1164.

Cite this article as: Mahadhipta H, Muhyi A, Harist Fadhlizain MA, Mitchel M, Gani KS & Kholinne E (2026) En bloc discectomy via anterior lumbar approach: a technical note. SICOT-J **12**, 19. https://doi.org/10.1051/sicotj/2026002.